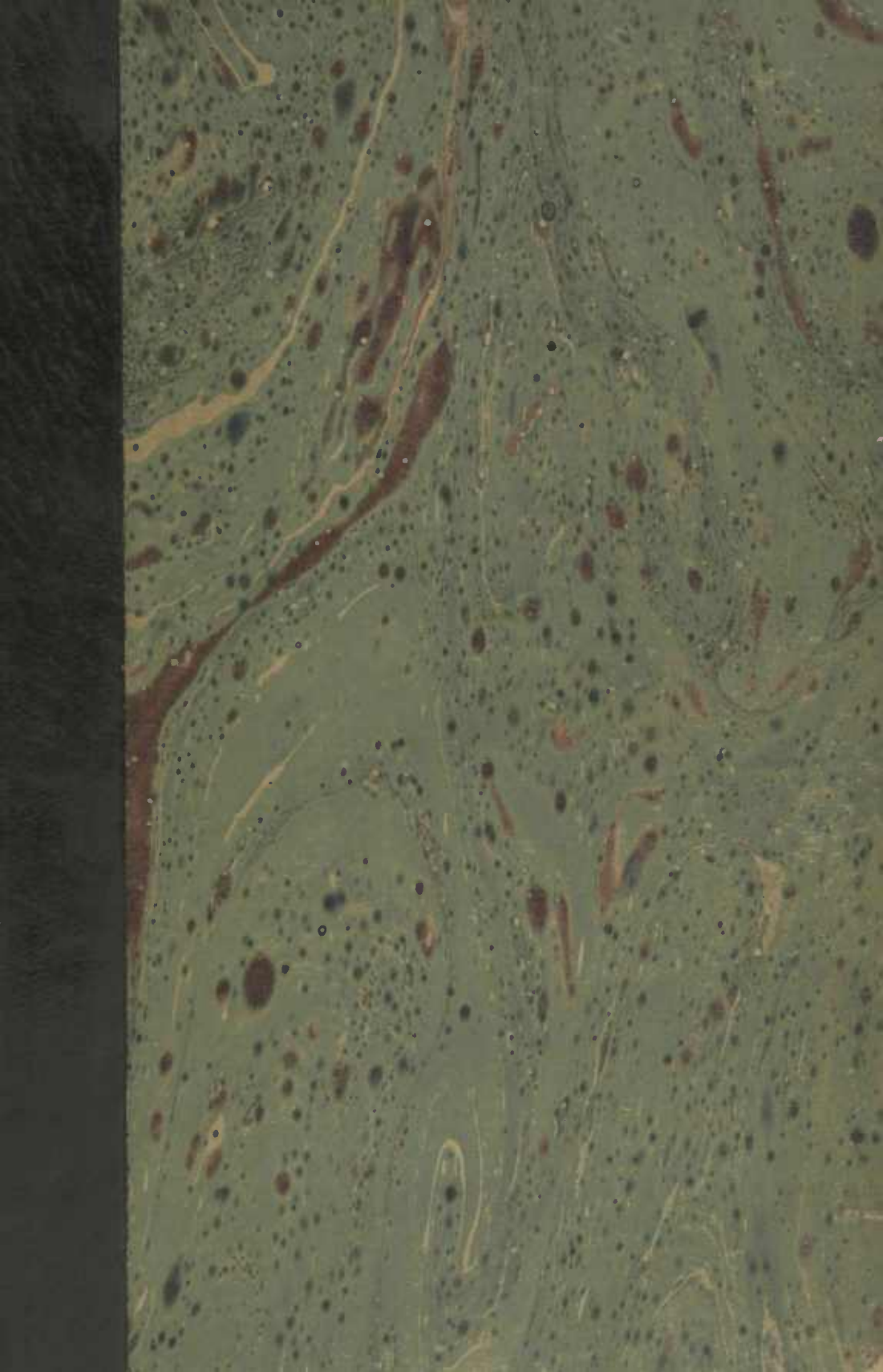









A MANUAL OF SURGICAL TREATMENT



# A Manual of Surgical Treatment

By

W WATSON CHEYNE

M.B., F.R.C.S., F.R.S.

Professor of Surgery in King's College, London; Surgeon to King's College Hospital, and  
The Children's Hospital, Paddington Green, etc.

and

F F. BURGHARD

M.D. and M.S. (Lond.), F.R.C.S.

Teacher of Practical Surgery in King's College, London; Surgeon to King's College Hospital, and  
The Children's Hospital, Paddington Green, etc.

In Six Parts

PART III.

*The Treatment of the Surgical Affections of the Bones.  
Amputations*

LONGMANS, GREEN AND CO.

39 PATERNOSTER ROW, LONDON

AND BOMBAY

1900



To

THE RIGHT HON.  
LORD LISTER, LL.D., P.R.S.,  
THE FOUNDER OF MODERN SURGERY,  
WITHOUT WHOSE WORK MUCH OF  
THIS BOOK COULD NOT HAVE  
BEEN WRITTEN.



## AUTHORS' PREFACE.

### GENERAL PREFACE.

THE subject of Surgery has now become so extensive that any work attempting to deal with it in an exhaustive manner must necessarily be so large and unwieldy as to be suitable only for purposes of reference, or for the use of those who devote themselves exclusively to its practice. In any text-book of convenient size the information given in certain branches of the subject must therefore be considerably condensed, and, as the first essential for the beginner is to have the fullest knowledge of the nature and characters of the diseases that he has to study, special stress is usually laid upon pathology, symptomatology, and diagnosis. For the practitioner, on the other hand, who is already acquainted with these points, the great essential is full and detailed information as to the best methods of treatment.

We have ourselves frequently experienced the want of detailed information, especially as regards the after-treatment of our cases, and have had to learn the best methods of procedure from experience. Nothing can of course replace experience, but it is often of the greatest advantage to have a detailed record of that of others upon which to base one's work. It is this want that the present work is intended to supply. We have tried to put ourselves in the place of those who have to treat a given case for the first time, and we have endeavoured to supply them with details as to treatment from the commencement to the termination of the illness. We have assumed that the reader is familiar with the nature and diagnosis of the disease, and we only refer to the pathology and symptoms in so far as it is necessary to render intelligible the principles on which the treatment is based, and the various stages of the disease to which each particular method is applicable.

We have purposely avoided attempting to give anything like a complete summary of the various methods of treatment that have from time to time been proposed: to do so would merely confuse the reader.

Only those plans are described which our experience has led us to believe are the best, but with regard to these we have endeavoured to state exactly and in detail what we ourselves should do under given circumstances. In some cases no doubt several methods of treatment are of equal value, and while we have only discussed at length that which we have ourselves been led to adopt, we have referred shortly to the others.

We have not mentioned all the exceptional conditions that may be met with, but we have endeavoured to include all the circumstances with which the surgeon is most commonly called upon to deal. The task has been one of some difficulty, the more so as we have had, to a certain extent, to break new ground. This must serve as our excuse for the many shortcomings in the work.

### PREFACE TO PART III.

It was originally intended to include the Surgical Affections of the Joints in this Part; it has however been necessary, owing to considerations of space, to relegate them to the succeeding one (Part IV.). It will also be found that Fractures of the Skull, the Spine, the Jaw, the Hyoid Bone and the Ribs have not been included among those described in this volume. We felt that they would be better treated of later on when the more strictly regional part of the work is reached, as much repetition concerning the treatment of complications will thereby be saved.

It may be objected that we have not even mentioned many well-recognised methods of treating various fractures. The subject is so extensive that we have had to confine ourselves strictly to the principle of the work, namely, only to recommend those methods that have proved best in our hands; a mere enumeration of methods would be of no value for our purpose.

We have received much help from Dr. Lambert Lack in seeing the volume through the press. We are indebted to the courtesy of the Council of the New Sydenham Society for permission to copy Fig. 52 from Prof. Helferich's well-known work on *Fractures and Dislocations*, while Messrs. Down Bros. have again been good enough to allow us to draw freely upon their illustrations of surgical instruments. With the above exceptions the illustrations have been made by Mr. T. P. Collings, from photographs or original sketches; to him we offer our best thanks.



# TABLE OF CONTENTS.

## PART III.

### DIVISION I.

#### THE SURGICAL AFFECTIONS OF BONES.

##### SECTION I.—FRACTURES.

###### CHAPTER I.—FRACTURES : GENERAL CONSIDERATIONS.

	PAGE
DEFINITION—Causes : Exciting and Predisposing—Classification—Displacement—Pathological Changes—Repair,	1-5
TREATMENT OF SIMPLE FRACTURES— <i>Reduction</i> : Extension and Counter-Extension—Obstacles—Time for Effecting Reduction.— <i>Maintenance of Reduction</i> : Position of Limb—Retentive Apparatus : Bandages and Strapping—Splints—Extension Apparatus—Mechanical Fixation of Fractured Ends.— <i>Prevention of Adhesions in Joints and Muscles,</i>	5-31
TREATMENT OF COMPOUND FRACTURES—When Wound is Considerable—When the Wound is very Small—When the Damage is Extreme,	31-36
TREATMENT OF COMPLICATED FRACTURES— <i>Immediate Complications</i> : Wounds of Skin not communicating with Fracture—Injury to Main Artery—False Aneurism—Injury to Main Vein—Injury to Main Nerve—Injury to a neighbouring Viscus—Wounds of Joints—Dislocation—Fatty Embolism.— <i>Complications occurring during the progress of the Case</i> —Oedema, Pruritus and Vesication—Thrombosis—Gangrene—Septic Complications—Oedema of Lungs and Hypostatic Pneumonia—Delirium Tremens—Bedsore—Necrosis—Mal-union—Non-union—Inclusion of Nerves in the Callus—Adhesion of Muscles and Tendons to Fractured Ends,	36-55

###### CHAPTER II.—FRACTURES OF THE CLAVICLE AND SCAPULA.

FRACTURES OF THE CLAVICLE—Displacement—Complications.—Treatment : Of Ordinary Form—Of Fracture of Acromial End—Of Fracture at the Sternal End—Of Green-stick Fractures—Of Compound Fracture,	56-62
FRACTURES OF THE SCAPULA—Varieties—Symptoms.—Treatment : Of Fractures of the Body—Of Fractures of the Acromion Process—Of Fractures of the Neck—Of Fractures of the Coracoid Process,	63-65

## CHAPTER III.—FRACTURES OF THE HUMERUS.

	PAGE
FRACTURES OF THE UPPER END—Varieties—Treatment: Of Fractures of the Surgical and Anatomical Necks—Of Separation of the Great Tuberosity—Of Separation of the Upper Epiphysis—Combined Fracture and Dislocation,	66-74
FRACTURES OF THE SHAFT—Causes—Displacement—Complications—Treatment: Injury to the Musculo-Spiral Nerve,	74-76
FRACTURES OF THE LOWER END—Varieties—Treatment: Of Supra-Condyloid Fracture—Of T-shaped Fracture—Of Fracture of either Condyle alone—Of Fracture of Internal Epicondyle,	77-81

## CHAPTER IV.—FRACTURES OF THE FORE-ARM AND HAND.

FRACTURES OF THE BONES OF THE FORE-ARM:	
FRACTURES OF THE OLECRANON—Causes—Displacement—Treatment: In Recent and Old Cases—Palliative and Operative,	82-90
FRACTURES OF THE CORONOID PROCESS—Causes—Treatment,	90-91
FRACTURES OF THE HEAD AND NECK OF THE RADIUS—Causes—Treatment,	91-92
FRACTURES OF THE MIDDLE OF THE FORE-ARM.— <i>Of the Ulna alone</i> : Displacement—Treatment: Of Simple Fracture—When there is Dislocation of the Head of the Radius.— <i>Of the Radius alone</i> : Causes—Displacement—Treatment: Of Fracture above and of Fracture below the Insertion of the Pronator Teres.— <i>Of both Bones</i> : Causes—Displacement—Treatment: Of Simple Fracture—Of Green-stick Fracture—Of Mal-union—Of Ununited Fracture,	92-97
FRACTURES OF THE LOWER THIRD OF THE FORE-ARM.— <i>Colles's Fracture</i> : Causes—Displacement—Treatment: Reduction—Splints—Mal-union.— <i>Separation of the Lower Epiphysis of the Radius</i> : Causes—Results—Treatment.— <i>Fracture of the Styloid Process of the Ulna</i> : Treatment.— <i>Fracture of both Bones</i> ,	97-100
FRACTURES OF THE BONES OF THE HAND:	
OF THE CARPAL BONES: Causes—Treatment,	101
OF THE METACARPAL BONES: Causes—Displacement—Treatment,	101
OF THE PHALANGES: Causes—Treatment,	102

## CHAPTER V.—FRACTURES OF THE PELVIS.

FRACTURES OF THE PELVIS AS A WHOLE—Seats—Complications—Treatment,	103-104
FRACTURES OF THE INDIVIDUAL BONES OF THE PELVIS.— <i>Of the Ilium</i> : Treatment.— <i>Of the Ischium</i> : Treatment.— <i>Of the Acetabulum</i> : Treatment,	104-106
FRACTURES OF THE SACRUM—Causes—Complications—Displacement—Treatment,	106-107
FRACTURES OF THE COCCYX—Causes—Treatment,	107-108

## CHAPTER VI.—FRACTURES OF THE FEMUR.

FRACTURES OF THE UPPER END—Varieties.— <i>Intra-Capsular Fracture</i> : Displacement—Treatment: In Young Adults: Unimpacted—Impacted.—In Elderly and Feeble Subjects: Palliative—Operative.— <i>Extra-Capsular Fracture</i> : Causes—Displacement—Treatment: Of Unimpacted Form—Of Impacted Form.— <i>Fractures of the Great Trochanter</i> : Displacement—Treatment,	109-119
OF THE SHAFT—Causes—Displacement—Treatment: When just below the Trochanters—Near the Centre of the Shaft—In Children—Of Mal-union—Of Non-union—Of Compound Fracture,	119-129

	PAGE
OF THE LOWER END.— <i>Supra-Condylloid Fracture</i> : Displacement—Treatment: Of Simple Form—Of Compound Fracture.— <i>Fracture of either Condyle</i> : Treatment.— <i>T-shaped Fracture</i> : Treatment.— <i>Separation of Lower Epiphysis</i> : Treatment,	129-133
DETACHMENT OF ARTICULAR CARTILAGE—Treatment,	133

## CHAPTER VII.—FRACTURES OF THE PATELLA.

TRANSVERSE FRACTURE.— <i>Treatment of Recent Cases</i> : Operative—Palliative.— <i>Treatment of Long-standing Cases</i> : Secondary Suture,	134-147
COMMINUTED FRACTURE—Treatment,	147-148
COMPOUND FRACTURE—Treatment,	148
VERTICAL FRACTURE—Treatment,	148

## CHAPTER VIII.—FRACTURES OF THE LEG AND FOOT.

## FRACTURES OF THE BONES OF THE LEG:

FRACTURES OF THE TIBIA ALONE— <i>Of Upper End</i> —Treatment: Of Compression Fracture—When Spine is broken off—In Transverse Fracture—In Separation of Epiphysis.— <i>Of Shaft of Tibia</i> —Treatment: Of Simple Fracture—Of Comminuted Fracture—Of Compound Fracture—Of Ununited Fracture— <i>Of Lower End</i> —Treatment,	149-155
FRACTURES OF THE FIBULA ALONE— <i>Of the Shaft</i> —Treatment— <i>Pott's Fractures</i> —Definition—Displacement—Complications—Treatment: Of Simple Fractures—Of Compound Fractures—Of Mal-Union.— <i>Of the Lower End without Dislocation</i> —Treatment— <i>Dupuytren's Fracture</i> —Treatment,	155-163
FRACTURES OF BOTH BONES—Causes—Displacement—Treatment: Of Simple Fractures—Of Compound Fracture—Of Ununited Fracture,	149-167
FRACTURES OF THE BONES OF THE FOOT— <i>Fracture of the Astragalus</i> —Treatment— <i>Fracture of the Os Calcis</i> —Treatment: Of Comminuted Fracture—of Compound Fracture—Of Fracture of the Posterior Part— <i>Fractures of other Tarsal Bones</i> — <i>Fractures of the Metatarsal Bones</i> .	167-169

## SECTION II.—DISEASES OF BONES.

## CHAPTER IX.—ACUTE AND CHRONIC INFLAMMATION OF BONES.

GROWING PAINS,	170
ACUTE INFLAMMATION:	
ACUTE NON-SUPPURATIVE OSTEITIS—Treatment,	171
ACUTE SUPPURATIVE OSTEITIS—Causes—Pathological Changes—Symptoms—Results—Treatment: <i>Of Acute Suppurative Periostitis</i> —Incision— <i>Of Acute Osteomyelitis</i> —Osteotomy—Amputation—Resection of entire Diaphysis—Bone-grafting— <i>Of Acute Epiphysitis</i> —Treatment of Arrest of Growth—Amputation— <i>Of Acute Suppurative Osteitis accompanied by Joint Suppuration</i> —Amputation—Osteotomy and Arthrotomy— <i>Of Acute Suppurative Osteomyelitis and Periostitis after an Open Wound</i> —Amputation— <i>Of Acute Suppurative Osteitis of the Flat Bones</i> ,	170-182
CHRONIC INFLAMMATION—Pathological Changes—Symptoms—Treatment: Palliative—Operative: In young subjects—In old subjects,	182-185

## CHAPTER X.—NECROSIS : PHOSPHORUS NECROSIS.

	PAGE
NECROSIS—Characters of a Sequestrum—Separation of the Sequestrum—Treatment : <i>Sequestrotomy</i> —Methods of obtaining Obliteration of the Cavity in the Bone : In an Aseptic Wound—In a Septic Wound— <i>Amputation</i> ,	186-193
QUIET NECROSIS—Treatment,	193-194
PHOSPHORUS NECROSIS—Treatment : Prophylactic—When the Disease is estab- lished,	194-195

## CHAPTER XI.—TUBERCULOUS DISEASE OF BONE.

VARIETIES—Acute Tuberculosis—Limited Tuberculous Deposits—Tuberculous Osteo- myelitis—Tuberculous Periostitis.—CLINICAL STAGES—TREATMENT : <i>Of Cases</i> <i>unaccompanied by Chronic Abscess</i> : Palliative—Radical— <i>Of Cases in which</i> <i>there is an Unopened Abscess</i> : Excision of Abscess— <i>Of Cases in which there are</i> <i>Septic Sinuses</i> : Excision of Sinuses—Amputation,	196-202
---	---------

## CHAPTER XII.—SYPHILITIC AND RHEUMATIC AFFECTIONS OF BONE.

SYPHILIS OF BONE.— <i>In Secondary Syphilis</i> : Treatment.— <i>In Tertiary Syphilis</i> : Treatment.— <i>In Hereditary Syphilis</i> : Treatment,	203-205
RHEUMATIC PERIOSTITIS AND OSTEITIS—Treatment—Medicinal—Operative,	205-206

## CHAPTER XIII.—RICKETS : SCURVY-RICKETS.

RICKETS — Etiology — Pathological Changes — Treatment : Feeding — Clothing — General Directions—Drugs—Splints—Operation, -	207-211
SCURVY-RICKETS — Definition — Etiology — Pathological Changes — Symptoms — Treatment : <i>Prophylaxis</i> : Feeding—General Hygienic Directions.— <i>Curative</i> : General—Local,	212-216

CHAPTER XIV.—OSTEOMALACIA : OSTEITIS DEFORMANS : LEONTIASIS  
OSSIUM : ACROMEGALY : ACTINOMYCOSIS : AND TUMOURS OF BONE.

OSTEOMALACIA—Treatment.—OSTEITIS DEFORMANS—Treatment.—LEONTIASIS OSSIUM — Treatment. — ACROMEGALY — ACTINOMYCOSIS — Treatment. — TUMOURS — Treatment.— <i>Of Primary Tumours</i> : Exostosis — Chondroma— Sarcoma.— <i>Of Secondary Tumours</i> ,	217-221
--	---------

## DIVISION II.

## AMPUTATIONS.

## CHAPTER XV.—AMPUTATIONS : GENERAL CONSIDERATIONS.

PRESENT POSITION OF AMPUTATION IN SURGERY—Greater Deliberation—In- frequency—Increasing Favour of Irregular Flaps—Predominance of the Skin- flap,	222-223
ESSENTIALS OF A GOOD AMPUTATION—Position of Cicatrix—Avoidance of Adher- ent Flaps—Painless Scar, -	223-224

	PAGE
METHODS OF AMPUTATING.— <i>The Circular Method</i> : Objections.— <i>Modified Circular Method</i> : Suitable Cases.— <i>The Flap Method</i> : Length of Flaps— <i>The Racket Method</i> : Suitable Cases.— <i>Irregular Amputations</i> ,	224-232
METHOD OF PERFORMING A TYPICAL AMPUTATION.— <i>Preliminary Steps</i> : Disinfection.—Arrest of Hæmorrhage: Esmarch's Method—Lister's Method—Prevention of Shock—The Amputating Knife— <i>Cutting the Flaps</i> : Shape of the Flaps—Raising the Flaps— <i>Sawing the Bone</i> — <i>Securing the Vessels</i> — <i>Suture of Flaps</i> — <i>Drainage</i> — <i>Dressings</i> — <i>Splints</i> .— <i>After-treatment</i> : Stump Bandages—When the Amputation becomes Septic.— <i>Faulty Stump</i> : Treatment.— <i>Conical Stump</i> : Treatment,	232-243

#### CHAPTER XVI.—AMPUTATIONS IN THE UPPER EXTREMITY.

AMPUTATIONS OF THE FINGERS—General Considerations.— <i>Amputation of the Terminal Phalanx</i> : By a Long Palmar Flap.— <i>Amputation through the Second Phalanx</i> : Fixation of Tendons to Stump.— <i>Amputation through the First Phalanx</i> — <i>Amputation at the Metacarpo-Phalangeal Joint</i> : Importance of retaining the Metacarpal Bone—Racket-shaped Incision.— <i>After-treatment</i> : <i>Removal of the Head of the Metacarpal Bone</i> .— <i>Amputation of the Index and Little Fingers</i> .— <i>Amputation of a Metacarpal Bone</i> .— <i>Partial Amputations of the Hand</i> .— <i>Amputation of the Thumb</i> ,	244-254
AMPUTATION AT THE WRIST JOINT—General Considerations—Modified Circular Method—Amputation by a Long Palmar Flap,	254-256
AMPUTATIONS THROUGH THE FORE-ARM—Modified Circular Method,	256-257
AMPUTATION THROUGH THE ELBOW JOINT,	257-259
AMPUTATIONS THROUGH THE ARM,	259-260
AMPUTATIONS AT THE SHOULDER JOINT—Spence's Operation—Operation by a Deltoid Flap—By Lateral Flaps—Furneaux Jordan's Method,	260-264
REMOVAL OF ENTIRE UPPER EXTREMITY—Indications—Position—Preliminary Incision—Raising of Anterior and Posterior Flaps,	264-267
REMOVAL OF THE SCAPULA—Preliminary Incision—Incision for Flaps— <i>After-treatment</i> .—Results,	267-270

#### CHAPTER XVII.—AMPUTATIONS IN THE LOWER EXTREMITY.

AMPUTATIONS OF THE TOES—General Considerations—Methods—Removal of the Metatarsal Bones,	271-272
AMPUTATIONS OF THE FOOT—General Considerations—Lisfranc's Operation—Chopart's Amputation—Sub-astragaloid Amputation—Syme's Amputation—Pirogoff's Amputation—Amputation through the Ankle by means of an Internal Flap,	272-280
AMPUTATIONS THROUGH THE LEG—Lister's Amputation—Amputation at the "Seat of Election"—Other Methods,	280-283
AMPUTATION THROUGH THE KNEE JOINT—Stephen Smith's Amputation—Lister's Amputation—Carden's Amputation—The Stokes-Gritti Amputation,	283-287
AMPUTATIONS THROUGH THE SHAFT OF THE FEMUR—Control of Circulation—Prevention of Shock—Amputation by Antero-External and Postero-Internal Flaps,	287-290
AMPUTATIONS THROUGH THE HIP JOINT—Furneaux Jordan's Amputation—Treatment where it is impracticable to perform a Furneaux Jordan's Amputation,	290-295

# LIST OF ILLUSTRATIONS.

## PART III.

FIG.	PAGE
1. Gooch's Splinting,	11
2. Wire-Netting Splint,	12
3. Croft's Splint: Method of cutting out the Lateral Portions,	14
4. " " Removing the excess of Plaster from the Lateral Portions,	15
5. " " Bandaging on the Lateral Portions,	16
6. Method of examining a Limb in a Croft's Splint,	17
7. Croft's Splint: Shape of the Anterior and Posterior Portions,	19
8. " " Application of the Anterior and Posterior Portions,	20
9. " " The Antero-Posterior Splint Removed.	20
10. Bavarian Splint: Method of Application,	21
11. Bavarian Splint,	21
12. Pulley Arm for Weight Extension,	23
13. Stirrup for Weight Extension,	24
14. Weight Extension applied to the Lower Limb,	25
15. Interrupted Plaster of Paris Splint,	35
16. Screws and Drill for Fixation of Fractures,	51
17. Peters' Forceps,	52
18. Methods of Wiring a Long Bone,	53
19. Securing a Transverse Fracture by Aluminium Plates,	53
20. The Handkerchief Method of Treating Fractured Clavicle,	58
21. Apparatus for pulling back the Shoulders in Fractured Clavicle,	59
22. Sayre's Apparatus for Fractured Clavicle: Applying the Arm Loop,	60
23. " " " " Pushing forward the Elbow and pulling back the Shoulder,	61
24. " " " " Supporting the Elbow,	62
25. Method of securing a Pad in the Axilla,	68
26. Bandages applied in Transverse Fracture of the Upper End of the Humerus,	69
27. Shoulder Cap for use in Fractures of the Humerus,	70
28. Weight Extension in Fracture of the Upper End of the Humerus: Extension applied while the patient is in bed,	71
29. " " " " Extension applied while the patient is up,	72
30. Apparatus for Fractures of the Shaft of the Humerus,	75
31. Incision for Wiring the Olecranon,	83
32. Operation for Wiring the Olecranon: Drilling the Bone,	84

FIG.		PAGE
33.	Operation for Wiring the Olecranon : Method of Passing the Wires,	85
34.	"    "    "    "    Twisting the Wire,	86
35.	Method of Lengthening the Triceps in the operation for Wiring long-standing cases of Fracture of the Olecranon,	89
36.	Carr's Splint for Colles's Fracture,	99
37.	Metal Splint for Fractures of the Phalanges,	102
38.	Extension Applied for Fracture of the Acetabulum,	106
39.	Liston's Long Splint : Method of Application,	111
40.	"    "    "    The Splint Applied,	112
41.	Thomas's Hip Splint,	113
42.	Extension Apparatus for Fracture of the Neck of the Femur,	116
43.	Method of Preventing Rotation during Weight Extension for Fracture of the Femur,	117
44.	Weight Extension for Fracture of the Femur below the Trochanters,	120
45.	Hodgen's Splint,	121
46.	Metal Splint for Fracture of the Shaft of the Femur,	123
47.	Vertical Extension for Fractured Femur in Children,	124
48.	The Double Splint for Fracture of the Femur,	125
49.	Method of Attaching Pulleys to the Lower Extremity,	126
50.	Methods of Cutting the Femur for Ununited Fracture,	127
51.	Thomas's Knee Splint,	128
52.	Transverse Fracture of the Patella ( <i>after Helferich</i> ),	135
53.	Incision for Wiring the Patella,	136
54.	Wiring the Patella : Drilling the Lower Fragment,	137
55.	"    "    "    "    "    Passing the Wire,	138
56.	"    "    "    "    "    Twisting the Wire,	139
57.	Method of Uniting a Comminuted Fracture of the Patella,	139
58.	Fracture of the Patella Treated by Splints,	143
59.	Lengthening of the Quadriceps in Suture of the Patella,	146
60.	"Fracture Box" or "Box Splint" for Fractures of the Leg,	151
61.	Dupuytren's Splint,	158
62.	Syme's Horse-shoe Splint,	159
63.	Anterior Suspension Bar for Compound Fracture of the Leg,	166
64.	Method of Wiring a Transverse Fracture of the Tibia,	167
65.	Circular Method of Amputation,	225
66.	The Modified Circular Method of Amputation.	226
67.	Rugines or Periosteum Detachers,	226
68.	Bandage Retractors for Amputations,	227
69.	Metal Retractor for Amputations.	228
70.	Flap Method of Amputation,	229
71.	How to Estimate the Length of the Flaps in Amputating,	230
72.	Various Types of Racket-shaped Incisions,	231
73.	Methods of Rounding off the End of the Bone in Amputations,	237
74.	Gauze and Collodion Bandage for an Amputation Stump,	240
75.	The Stump Bandage,	241
76.	Amputation of the Terminal Phalanx of a Finger,	245
77.	Amputations of the Fingers,	248
78.	Amputations of the Index and Little Fingers,	250
79.	Amputation of a Metacarpal Bone Alone,	251
80.	Amputations of the Thumb,	253
81.	Amputations through the Wrist Joint,	255
82.	Modified Circular Amputation through the Forearm,	257
83.	Amputation through the Elbow Joint by a long Internal Flap,	258

## LIST OF ILLUSTRATIONS.

	PAGE
Method of Controlling Hæmorrhage in Amputations of the Upper Arm,	260
Methods of Amputating at the Shoulder Joint,	261
Incisions for Removal of the Entire Upper Extremity,	266
Amputation of the Scapula,	268
Amputations of the Toes,	272
Farabeuf's Sub-astragaloid Amputation of the Foot,	274
" " "	275
Syme's Amputation,	277
Syme's "Foot-Knife,"	277
Amputation at the Ankle Joint by an Internal Flap,-	280
Lister's Amputation through the Leg,	281
Amputation of the Leg at the "Seat of Election" by the "Hooded Flap,"	282
Amputations about the Knee,	285
How to Prevent Esmarch's Tubing from Slipping during an Amputation through the Thigh,	288
Tourniquet for use in Amputations high up the Thigh,	289
Abdominal Tourniquet for use in Amputations at the Hip Joint,	292
Amputations through the Hip Joint,	294



# DIVISION I.

## THE SURGICAL AFFECTIONS OF BONES

### SECTION I.—FRACTURES.

#### CHAPTER I.

##### FRACTURES : GENERAL CONSIDERATIONS.

**DEFINITION.**—By a fracture is understood a sudden solution of continuity in a bone brought about by some form of violence. Before dealing with fractures of the individual bones, it will be well to refer to some points in the treatment of fractures in general.

**CAUSES.**—It is usual to divide the causes of fracture into the **exciting causes**—that is to say, the actual violence producing the fracture,—and the various **predisposing causes** which lead to brittleness of the bones and a tendency to fracture upon the application of even a slight degree of force. It is important to bear these predisposing causes in mind, because, when such exist, the treatment must be directed, not only to replacing the fragments and keeping them in position, but also to combating the predisposing cause.

**Exciting causes.**—When violence is applied to a bone, it may give way at a point directly opposite the seat of injury—when the fracture is termed one by **direct violence**—or it may break at some distance from the point of application of the force—when the fracture is spoken of as one from **indirect violence**. The question as to whether any particular fracture is caused by direct or indirect violence is of importance both in prognosis and treatment. When the fracture is due to indirect violence, the line of fracture is very often oblique or spiral, and there is frequently some difficulty in reducing and keeping the fragments in proper position. When the fracture is caused by direct violence, on the other hand, it is

transverse or comminuted, and the injury is usually not confined to the bone alone; the soft parts in the neighbourhood may be considerably damaged.

Fractures from indirect violence may occur in several ways; it is very common for the ends of the bone to be compressed between two opposing forces, and for fracture to take place at some intermediate point. Here the fracture is essentially due to a bending of the bone which is carried beyond its limit of elasticity; in the long bones the resulting fracture usually occurs at the weakest part of the bone, namely, at the junction of the expanded articular end with the comparatively narrow shaft. In other cases, fractures from indirect violence may be brought about by muscular action alone; this is generally due to unduly forcible or irregular muscular contraction, or to muscular contraction of normal strength in those who suffer from some pathological condition of the bones. As an example of fracture resulting from irregular and forcible contraction may be mentioned fracture of the patella from violent contraction of the quadriceps extensor when the knee is bent, while fracture of the neck of the femur in old and debilitated persons may be quoted as an example of fracture from the latter cause.

**Predisposing causes.**—There are numerous pathological conditions which produce a liability to fracture, and so act as predisposing causes. It will suffice to enumerate the most important. Amongst these are the senile changes which occur in the structure of the bones, fragilitas ossium, mollities ossium, scurvy rickets, insanity, locomotor ataxia, atrophy of bone, new growths in bones, and various inflammatory conditions, such as those which lead to extensive necrosis or rarefying osteitis.

It is always important to bear in mind the predisposing causes in the treatment of a case of fracture; when a fracture has been produced by comparatively slight violence, one of these causes should be carefully searched for, and, if found, appropriately treated.

**CLASSIFICATION.**—Fractures are variously classified; for our purposes they may be divided into three great classes: Simple, Compound, and Complicated.

**A Simple fracture** is one which does not communicate with the exterior and which is uncomplicated by injury to important structures in its neighbourhood. This form of fracture is not liable to septic complications, and, with few exceptions, heals with very little trouble.

**A Compound fracture** is one which communicates with the exterior through one of the cutaneous or mucous surfaces. These fractures may be compound from the first; communication with the exterior may occur simultaneously with the fracture, either as a result of the soft parts being divided down to the bone, or from the broken ends of the bone tearing through the tissues and projecting through the skin or mucous membrane. On the other hand, a fracture may be simple at first, and may afterwards become compound, either from the bone working its way through the

tissues as a result of movement, or from the occurrence of inflammation and suppuration or gangrene of the parts over the broken ends.

**A Complicated fracture** is one that is complicated with some other injury; this may be a wound in the skin which does not, however, communicate with the bone, or wounds of vessels, nerves, joints, etc.

Fractures are still further subdivided according to the peculiarities about the line of fracture. According to the direction of the line of fracture, they are classified as *transverse*, *oblique*, and *spiral* fractures. When the bone at the seat of fracture is broken up into a number of small pieces, the term *comminuted* fracture is usually applied. *Multiple* fractures are those in which there is either more than one fracture in an individual bone, or more than one bone broken. An *impacted* fracture is one in which one end of the broken bone is driven into and, to a certain extent, splits up the other fragment. A *greenstick* fracture is one in which, owing to the softness of the bone, the fracture is incomplete, some of the fibres being torn while others are merely bent.

Besides these forms of true fracture, there is a **separation of the epiphysis** from its junction with the shaft; this occurs only in subjects under the age of twenty-five, and in many cases the line of separation runs partly through the epiphyseal cartilage and partly through the shaft of the bone.

Various other forms of fracture are described, but they are of very little importance from the point of view of treatment; most of them occur in the flat bones, more particularly those of the skull, and will be discussed later on. Amongst these may be mentioned fissures, indentations, starred and depressed fractures.

**DISPLACEMENT.—Varieties.**—When a bone is fractured, the fractured ends are, as a general rule, more or less displaced as regards each other; it is comparatively rare for a fracture to be unaccompanied by any displacement. The chief displacements which may be met with are *angular* displacements, where the fragments are inclined at an angle to each other, as is seen especially in greenstick fracture; *lateral* displacements, where the fractured ends remain to some extent in apposition, but are displaced to the side; *riding* or *overlapping* of the fragments, which is especially common in oblique fractures, the lower end being pushed up in front of or behind the other; *rotation* of one fragment around its vertical axis; and *separation* of the fragments, which is most often seen in fractures of the patella and the olecranon.

**Causes.**—The displacement in fractures is due to the force which produces the injury, to the contraction of muscles inserted into the fragments, or to the weight of the limb. In most cases the primary displacement is determined by *the direction and force of the injury* producing the fracture. There is comparatively very slight displacement in fractures due to direct violence, whilst it is very marked in those produced by indirect violence. This shows that it is not due, primarily at any rate, so much to

the muscular contraction as to the direction of the force. On the other hand, however, the displacement is kept up in most cases by *the contraction of the muscles*, whilst in others it is increased, and may even be entirely caused, by the muscular contraction; this may be the case even when there is little or no displacement at first. *The weight of the limb* is also an important factor in the production of displacement. This is more especially marked in fractures of the lower extremity, where, if proper support be not given to the foot, the latter rotates outwards, carrying with it the limb below the fracture, and outward rotation of the lower fragment is thus produced.

**PATHOLOGICAL CHANGES.**—When a bone is broken, there is always a certain amount of bruising or tearing of the soft parts about it. The periosteum is almost invariably torn through, although in children it may occasionally remain intact to a large extent; usually, however, it gives way either immediately above or below the actual seat of fracture. This is an important point to remember, because the free ends of the torn periosteum may become interposed between the fractured surfaces, and non-union may result. The muscles attached to the bone in the immediate neighbourhood of the fracture are torn, and, if there be much displacement, the fractured ends still further tear up the tissues in the immediate vicinity. The result is a considerable effusion of blood, which coagulates; the ends of the bone, when brought into apposition, are therefore to some extent separated by a layer of clot, whilst they are surrounded by a mass of coagulated blood, in which are entangled torn portions of the periosteum, the muscles, and other soft tissues. In a simple fracture this clot remains, and forms a mould in which the processes of repair take place.

**REPAIR.**—It is unnecessary here to specify the precise steps seen *in a simple fracture* undergoing repair. It is sufficient to mention that they consist of the formation of a temporary callus and ossification between the ends of the bones, and subsequent absorption of this callus. *In septic compound fractures* the process is different; the fractured surfaces and the tissues around become converted into granulation tissue, so that, provided no necrosis or osteo-myelitis occurs, the opposing surfaces of the bone are soon covered by granulations. These granulations coalesce, and ossification takes place in them; the union is thus an example of ossification in membrane. Opinions differ as to the exact process when union takes place *in aseptic compound fractures*. By some it is considered that the process is one of ossification in cartilage, similar to that occurring in simple fractures, whilst others look upon it as an ossification in membrane, as in suppurating compound fractures. The important point of distinction between the repair in simple and compound fractures, however, is that in the latter the external callus, which apparently plays a very important part in fixing the ends of the bones together whilst union is occurring between the broken surfaces, is absent, or, at any rate, is much less marked, and it is highly probable that the delay in union, which is so very common in

aseptic compound fractures or in aseptic operations for ununited or badly united fractures, may be to some extent due to the want of this temporary supporting material.

The treatment of fractures may best be considered under the headings of Simple, Compound, and Complicated fractures.

#### TREATMENT OF SIMPLE FRACTURES.

There are four important indications to attend to in the treatment of any case of fracture:

1. To bring the ends of the bone level with each other,—or Reduction.
2. To get the ends into accurate apposition,—or Coaptation. (These two manipulations are included under the popular term of “setting the fracture.”)
3. To maintain the ends of the bones in apposition until union has satisfactorily taken place,—or Immobilisation.
4. To promote the nutrition of the part, and to prevent adhesions in neighbouring joints and muscles.

**REDUCTION AND COAPTATION.**—These two processes may be considered together. Their object is to bring the ends of the fractured bone together, and to place them in accurate apposition, so that union may take place with the least possible deformity. Reduction and coaptation of a fracture are necessary whenever there is any displacement. Sometimes, as in fractures of the metacarpus or the jaw, this may be done by simple manipulation with the fingers, aided, if necessary, by the administration of an anæsthetic; but in the great majority of fractures affecting the long bones, mere manipulation will not suffice. The fractured ends generally overlap to a varying extent, and the muscles are contracted and offer considerable resistance to the necessary manipulations. Hence it is necessary to employ extension of the limb by traction, in order to bring the ends of the bone to the same level before the manipulations requisite for the proper coaptation of the broken ends can be practised.

**Extension and counter-extension.**—For the proper reduction of a fracture in a long bone it is very desirable to have some assistance, and, if the patient be very muscular, two assistants, if available, will be more satisfactory. If only one be at hand, he should exert counter-extension, that is to say, he opposes the extending force; it is not necessary to have a skilled assistant for this purpose. Where no assistant at all is available, counter-extension may be obtained by fixing the body of the patient to the bed, whilst the surgeon makes the necessary extension and manipulations. The lower fragment should be firmly seized with one hand well below the seat of the fracture; the other is left free to grasp the region of the fracture, and to manipulate the bones into proper position when the lower fragment has been pulled down sufficiently. If two assistants be present, one may be employed to make extension, whilst the other looks after the counter-

extension; the surgeon is thus able to devote all his attention to the proper coaptation of the fractured ends.

The extension should be made in the long axis of the bone, and should be steady and gradual. No sudden, jerky movements are allowable, as they only lead to contractions of the muscles that oppose the reduction; if slowly and steadily stretched, these muscles gradually become tired out, and their resistance ceases. If there be much pain or spasm associated with the attempt at reduction, or if the patient be very muscular, it is well to administer an anæsthetic; the muscular contraction will then be completely overcome, and the fractured ends can be brought into accurate apposition, while the apparatus necessary for maintaining them in position can be carefully and methodically applied before the patient is allowed to come round. With few exceptions, therefore, the administration of an anæsthetic should be insisted upon. It is most important to see that the limb is securely immobilised during the actual administration of the anæsthetic, and special attention must be directed to seeing that no involuntary movements of the limb occur; considerable damage may be done to the soft parts, and a simple fracture may be easily converted into a compound one from a neglect of this precaution. This danger must be particularly guarded against in alcoholic subjects; an assistant should be specially told off to fix the limb during the preliminary stages of the administration of the anæsthetic.

**Obstacles to reduction.**—There are various obstacles to reduction which must be borne in mind. The chief are:

1. **Spasm of the muscles**, which has just been alluded to, and which is readily overcome by the administration of an anæsthetic.

2. **The presence of impaction**, where one fragment is driven into the other. It may be a matter of considerable difficulty to disentangle the ends, and to bring them into proper position, but in most cases this should be done. There are a few instances, however, in which impaction is of great advantage, and should not be interfered with, *e.g.*, in fracture of the neck of the femur in old people. On the other hand, in such fractures as Colles's fracture, it is absolutely essential that the impaction should be undone as soon after the injury as possible, because if it be allowed to persist, the bones become welded together very quickly, and the hand is permanently disabled by a bony deformity and a displacement of the articular surface that cannot then be remedied without operation.

3. **The presence of loose fragments** about the fracture may give rise to much difficulty in effecting accurate coaptation. This is particularly the case in fractures in the immediate vicinity of joints; in them the greatest care must be taken to so manipulate the loose fragments, while the patient is under the anæsthetic, as to secure proper coaptation. If this be found impossible—as is particularly likely in fractures in the neighbourhood of the elbow joint—the surgeon should not hesitate to expose

the seat of fracture, and either remove the loose fragments or fix them properly in position according to their size or situation. If an attempt be made to get union with a loose fragment in bad position, the result will be that either non-union will occur, or the consolidation of the fracture will be accompanied by deformity and functional impairment of the limb; this will probably require for its rectification an operation at a later date and under much less favourable conditions. The treatment of individual cases of this kind will be referred to later, when we describe the special fractures.

**4. Portions of muscle, tendon, or fascia** may be interposed between the fragments, and, if allowed to remain, will cause union either to fail entirely, or to be very imperfect and accompanied by considerable deformity. Here again, if after thorough manipulation under an anæsthetic it be found that the interposed structures cannot be satisfactorily pushed aside, it is best to cut down upon the fracture, disentangle the ends of the bones, and then to bring them into proper apposition and secure them there.

**Time for effecting reduction.**—The reduction and coaptation of fractures should always be effected as soon as possible after the accident has happened, before any marked effusion has occurred; the surgeon is then able to ascertain satisfactorily whether he has brought the ends of the bones into accurate apposition. Moreover, as the effusion to a great extent is due to the hæmorrhage resulting from laceration of the tissues by the broken ends of the bone, the sooner these are immobilised the less effusion will there be. Lastly, it is easier to perform reduction immediately after the occurrence of the fracture, and there is less necessity to employ an anæsthetic than if some time be allowed to elapse, because in the early period the patient is suffering from a certain amount of shock; the muscles are considerably relaxed, and hence there is less rigidity and less difficulty in bringing the ends of the bone into apposition, while at the same time the patient does not appreciate the pain as much as he does after the shock has passed off. Many authors describe cases in which immediate reduction is not to be attempted, and where some time should be allowed to elapse before the fracture is reduced; they are those in which there is great swelling about the fracture, or excessive spasm (as in those suffering from incipient delirium tremens). The same line of treatment is recommended when a considerable interval has elapsed since the occurrence of the fracture. But in all these cases we have no doubt that there would be less trouble in reducing the fracture, less pain caused to the patient, and less likelihood of the occurrence of local troubles if the broken ends were brought into position at once. Fresh swelling will not then occur, because the ends of the bones are at rest; spasm can be readily overcome by an anæsthetic, and the limb can be so put up that the fracture cannot be subsequently displaced, even by the most violent movements. The longer the time allowed to elapse between the

injury and the reduction of the fracture, the greater will be the difficulty in effecting it, because of the rapid consolidation of the effusion that has been poured out, and the difficulty, therefore, of stretching the parts sufficiently to allow the ends of the bone to come into apposition.

When a fracture is reduced, it should be done once and for all, and the surgeon should then immediately proceed to apply some form of retentive apparatus designed to immobilise the parts. Should suitable fixation apparatus not be at hand when the surgeon first sees the case, he should content himself with applying some form of temporary fixation to the fragments, without making any attempt to bring them into apposition, and he should then, as soon as possible, complete his arrangements for the reduction of the fracture and the permanent maintenance of the broken ends in position. To attempt a partial reduction, in the first instance, and apply a temporary splint, and then to come back again and repeat the reduction before applying a permanent one is to lacerate the tissues twice instead of once, and to lead to the production of a much greater amount of effusion than would be the case if the advice we have just given were followed.

**MAINTENANCE OF REDUCTION.**—In maintaining the fragments in position after reduction, two points must be borne in mind. In the first place, the limb should be placed in a position that will minimise the action of all the muscles that can pull upon the fragment and so reproduce the displacement; in the second place, some suitable form of apparatus must be employed to fix the bones immovably in proper position.

**Position of the limb.**—One of the first points of importance in putting up a fracture permanently is to place the limb in such a position that the muscles which pull upon the broken fragments, and which may therefore reproduce the displacement, are relaxed as much as possible. This is better than attempting to control muscular action by the application of powerful splints and tight bandages. In determining the position which a limb should be made to assume when the bone is broken near either extremity, it should be remembered that it is more difficult to act upon the short fragment than upon the long one, and the shorter the fragment the more difficult it is to keep it in proper position. Hence, a good axiom, and one that applies more especially to fractures of the lower extremity, is that the position of the limb during repair should be so arranged that the long fragment is brought into a line with the short one, and not *vice versâ*. For example, in a fracture of the femur below the lesser trochanter, the short upper fragment is tilted forwards, and rotated outwards, and it is quite impossible with any form of apparatus to maintain the short fragment in the horizontal position and prevent its outwards rotation. Hence, in putting up the fracture, the long axis of the lower fragment, that is to say, the thigh and leg, must be made to coincide with the short one—in other words, the thigh must be flexed and rotated outwards.



In this connection it may be mentioned that, in spite of proper attention to position, the muscular contraction may sometimes be so great as to keep up the displacement, and it may therefore be advisable to divide tendons in order to neutralise the pull of the muscles. This is sometimes necessary in fractures about the ankle, where, in spite of flexion of the knee, the gastrocnemius pulls back the lower fragment.

**Retentive apparatus.**—After reduction of the fracture, measures must be taken to keep the fragments at rest until consolidation has occurred. Of course, in such fractures as those of the skull and the upper jaw, in which there is no likelihood of a recurrence after any displacement present has been reduced, these measures are not necessary. The following are the chief methods in use: (1) Bandages and strapping; (2) splints of various kinds, including immovable apparatus made of plaster of Paris, etc.; (3) extension in its various forms; and (4) operative interference designed to mechanically fasten the fragments together.

**1. Bandages and strapping.**—These are chiefly employed in fractures involving the trunk, and are only very rarely used for those affecting the extremities. In fractures of the clavicle, for example, and in certain fractures of the jaw, no splints are required, bandages or strapping being sufficient to secure proper coaptation and immobilisation. In fractures of the ribs also, strapping applied to the chest, in the manner to be described later on, suffices to ensure a sufficient amount of immobilisation. In fractures of the extremities this is rarely sufficient, although in certain instances it may be all that is required; such are fractures of one metacarpal or metatarsal bone, where the neighbouring bones act as efficient splints. Here a bandage to keep the parts at rest is all that is necessary.

The exact manner in which bandages and strapping should be applied will be dealt with when we describe the particular fractures for which they are employed; we may mention here that it should be a cardinal rule in most cases (the chief exception being fracture of the ribs) that the *bandages or strapping should not be put over the actual seat of fracture*. This is important for two reasons: in the first place, the pressure upon the line of fracture causes pain to the patient, and may actually bring about a recurrence of the displacement, while, in the second place, considerable irritation of the soft parts over the fractured ends will occur, and this will result in inflammation and possibly ulceration of the skin. Indeed, simple fractures have thus become converted into compound ones in the course of a few days.

**2. Splints of various kinds.**—In speaking of splints we shall confine our remarks chiefly to fractures of the extremities, and here it will be well to lay down certain general rules which are applicable to the treatment of the majority of these fractures.

(a) It is important to immobilise any joint acted upon by muscles attached to one or other of the fragments. Hence, in almost all cases, the joints above and below the fracture should be included in the splints,

and in some cases, such as fractures of the lower end of the humerus, the joints further away—*i.e.* those of the wrist and fingers—must also be fixed. It is to neglect of this precaution that the occurrence of faulty union or non-union after fractures of the long bones is often to be attributed.

(*b*) All undue pressure upon any bony prominence over which splints are applied must be carefully avoided. Unless this be done there will be much pain, the muscles will be irritated and in a state of spasmodic contraction, and sloughs and sores will be very apt to form. This, besides leading to further difficulty in applying the splints, will also expose the patient to the risks of septic absorption. It is still more important that all pressure over the seat of the fracture should be avoided, as otherwise a simple fracture may be converted into a compound one. Any splint that is used must be carefully and uniformly padded, so as to minimise the pressure exerted by the hard material of which it is made.

(*c*) The splints must not be bandaged on too tightly. Quite apart from the pain, and the tendency to the production of pressure sores over bony prominences resulting from too tight bandaging, œdema of the limb below and actual gangrene may ensue from it. Besides this, no bandage should be put on beneath the splint unless it be required to secure a dressing. It is recommended by many authors that, in a fracture of the upper arm, the limb should be bandaged from the fingers upwards to the seat of the fracture before the splints are applied, so as to prevent the occurrence of œdema. We do not ourselves advise this; if it be done, it is impossible to see what is happening when the splints have been applied, and œdema may occur in spite of the bandages, and there may be great constriction and even gangrene of the limb. If a bandage be employed at all, it should not reach higher than the lower end of the splint.

(*d*) While the splints are being secured to the limb, care must be taken not to relax the traction upon the fragments, or to alter their direction until the splints have been finally and firmly applied; displacement is otherwise liable to recur.

The choice of fixation apparatus is large, and varies according to the part affected; in selecting any particular form of splint, attention should be paid to the following points: (1) The splint should be as light as possible, consistent with the work which it has to perform; (2) it should be more or less porous, so as to permit of evaporation, otherwise decomposition of the sweat is apt to occur and lead to irritation of the skin beneath; (3) it should take its purchase only from bony points, and should not anywhere press unduly upon the limb; (4) it should be removable, so as to permit of massage and movements of the muscles and neighbouring joints from time to time.

**Materials for splints.**—The materials of which fixation apparatus may be made are very numerous. They may be wood, various kinds of metal, wire, guttapercha, pasteboard, felt, plaster of Paris, silicate of soda, etc. The material of which the majority of wooden splints is made is ordinary *deal*,

which has the advantage of being strong, light, cheap and easily obtainable; it has however the disadvantage that the splint cannot be made to fit the limb closely, and therefore, in many cases, its place is with advantage taken by materials which may be made to more or less encircle the limb. To a certain extent this may be done by a wooden splint if the form known as *Gooch's splint* be employed. This consists of a thin lath of deal, to the under surface of which is glued a piece of American cloth or canvas. When this has thoroughly dried, the upper surface of the deal is scored by a series of longitudinal cuts about three-quarters of an inch apart reaching down to the canvas on the under surface (see Fig. 1); this splint is particularly useful when, as in fractures of the upper arm or thigh, it is required to surround the limb more or less completely.

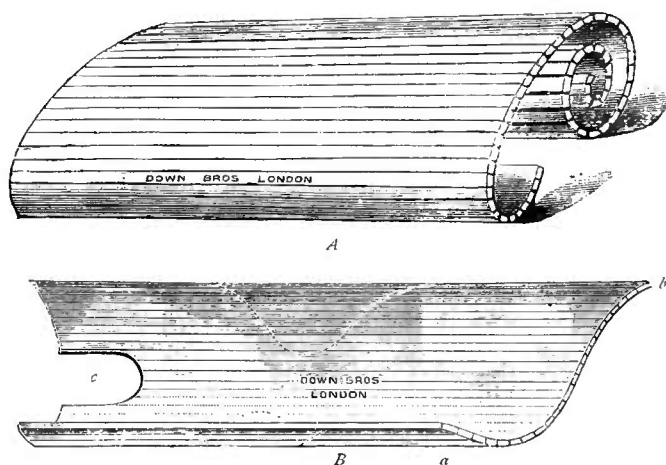


FIG. 1.—GOOCH'S SPLINTING. *A*. The roll of splinting before it is cut. The scored surface is uppermost in the figure, the one covered with American cloth being undermost. *B*. The splint cut ready for application to the right lower limb. An aperture *c* has been cut for the heel, while the upper end of the splint *ab* has been cut obliquely from the inner side *a* upwards and outwards to *b*. The dotted lines indicated upon the splint show the manner in which it is sometimes still further cut away when it is desired to leave the knee exposed.

*Block tin* is an extremely useful article for splints. It is especially good after operations and in compound fractures, as it can be cut to any pattern with plaster of Paris shears, bent round the limb easily, and so moulded as to fit it closely. For operation cases it has the advantage that it can be readily sterilised by boiling and, owing to the facility with which it is moulded, it can be incorporated in the substance of dressings. A specially valuable material for this latter purpose is the ordinary *wire netting* used for fences. This can be got of suitable stoutness, sterilised and moulded to fit the limb; it has the great advantage that, if incorporated with the dressing, it does not interfere with the proper absorption of the discharges (see Fig. 2).

Other materials from which moulded splints are conveniently made are guttapercha, poroplastic material, and leather. Splints made of these materials

are very comfortable and may be adjusted to any particular case rapidly and satisfactorily. In preparing them, a pattern should first of all be cut out in brown paper and upon this the material employed should be shaped. *Gutta-percha* may be readily cut with stout scissors after softening in warm

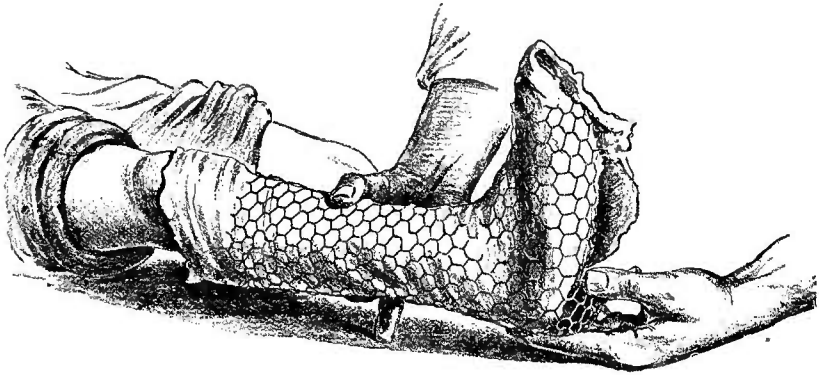


FIG. 2.—WIRE-NETTING SPLINT. The illustration shows the method of incorporating these splints with the dressing. A few layers of gauze are placed directly over the wound, and then a large sheet of the gauze is wrapped around the limb; outside this the wire-netting is moulded to the limb, and when this has been done, the gauze is turned down over the free edges of the splint, and more dressing is added over the region of the wound outside the netting. In the figure above, two lateral splints of this netting are being applied.

water. When cut to the pattern, the splint is immersed in boiling water; before applying it to the limb, the latter should be covered by a layer of wool or a thick folded bath-towel, as otherwise the patient might be burnt. The gutta-percha is taken out of the boiling water with a pair of forceps, laid on a warm dry towel, another towel is placed over it and the excess of moisture thus removed as quickly as possible, and then the soft gutta-percha is rapidly applied to the part, moulded round the limb and secured by a quickly applied bandage. The splint will harden in a few minutes and it and the temporary padding can then be removed and the permanent padding carefully arranged so that the splint does not exercise undue pressure anywhere, while at the same time it gets a thoroughly good hold.

*Poroplastic material* may be cut with a sharp knife with ease if the latter be held obliquely at about an angle of  $45^{\circ}$ ; if the knife be held at right angles it will be found extremely difficult to cut. When cut out, the splint is best softened by holding it before a fierce fire or by putting it in a steam steriliser for a short time. The material softened in this way does not set so quickly and gives more time for its careful adaptation to the limb.

*Leather* can be softened by immersion in vinegar or a solution of acetic acid. Splints made of gutta-percha or of leather should be perforated with holes, which should be punched from within outwards, in order to allow of the escape of perspiration from beneath.

**Padding of splints.**—As has already been said, the most careful attention must be paid to the padding of splints. In hospitals, the nurse in her leisure

hours generally gets a number of splints ready for use by placing cotton wool or tow over the splint and keeping this in place by means of a piece of linen which is sewn over the back of the splint. Splints so padded are quite useless, because they are made without any reference to the shape or peculiarity of the limb to which they are to be applied. The surgeon should pad the splints himself immediately before he puts them on. This is best done by arranging tow or wool over the splint, making it thicker where hollows are present. Over this is placed a piece of folded linen which overlaps the splint in all directions; when the splint is to be left on for some time, it is well to place a layer of boracic lint between the linen and the skin so as to absorb the sweat and prevent its decomposition. In addition to padding of this kind, small pads made of wool or tow sewn up in muslin should be at hand and these may be arranged between the limb and the splint wherever it is required to avoid pressure upon bony prominences.

**Methods of fastening splints.**—Splints may be fastened to the limb by straps or bandages. It is a common custom to fix the splints by means of strips of strapping applied around them in two or three places, and no doubt, as a method of preventing them from slipping, this is a good plan. It is only necessary however where flat wooden splints are employed and it has the disadvantage that, as the strapping is unyielding, constriction will be caused and the œdema below will be increased if the limb swells. In most cases splints may be perfectly well fastened on with bandages, and this is certainly the most comfortable and convenient method. In a few days the original bandages may be removed and fresh ones applied, or a fresh bandage can be put on outside the first if the latter be getting loose; this may be done without disturbing the fracture in the least. There is not the same risk of œdema of the limb below when bandages are used as there is when strapping is employed.

When splints are applied to each side of the limb they may be most conveniently fixed by strips of webbing and buckles applied in three places—top, bottom and middle of the splints. If these be not at hand, strips of bandage tied in slip knots may be substituted; outside this an ordinary bandage may be put on. The advantage of this plan is that the outside bandage can be taken off and the line of fracture inspected as often as may be necessary without loosening or disturbing the splints in any way; if the slip knots become stretched they can be easily tightened up one at a time without causing any disturbance at all.

**Plaster of Paris splints.**—A very useful form of splint which is applicable to a large number of fractures may be made with plaster of Paris. This may either take the form of an immovable casing completely surrounding the limb and destined to remain on for some time, or of lateral or antero-posterior splints hinged so that either or both can be easily removed to permit of inspection of the limb. The latter form of apparatus is that generally known by the name of Croft's modification of the Bavarian splint, and is of such general utility that we shall describe its application in detail.

**Croft's Splint.**—With some slight modification this method may be employed for moulded removable splints in almost any case of fracture. There are two ways of making this apparatus; in one the splints are lateral, in the other they are antero-posterior.

*The usual form of Croft's splint*, as employed for fractures of the lower extremities, is made as follows. A pattern for the lateral portions of the splint is first cut out from a piece of thoroughly shrunk house-flannel. The shaping of this pattern is of considerable importance in the proper application of the splint; the simpler but less accurate method is to take a stocking which fits the patient's sound limb, and lay it flat, with the foot at right angles, upon the house-flannel from which the pattern is then cut, making due allowance for any swelling that there may be in the region of the fracture. Another and more accurate way is that depicted in the diagram (see Fig. 3). In the first place, a series of measurements

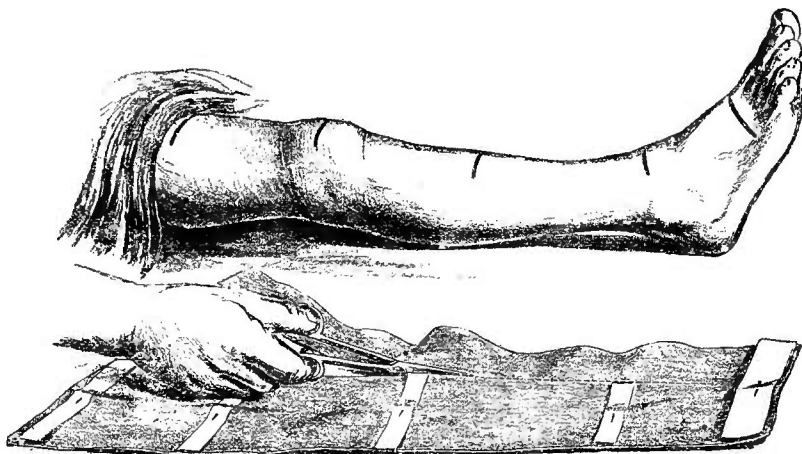


FIG. 3.—CROFT'S SPLINT. *Method of cutting out the lateral portions.* The pieces of white paper in the lower figure are equal to half the circumference of the limb in the upper at the corresponding marks, with the exception of the right hand one which is equal to the distance from the point of the heel to the mark at the root of the toes.

of the injured limb are taken in the following manner. The distance between the upper limit of the splint and the sole of the foot is first ascertained; then a series of marks are made with ink or an aniline pencil upon the skin at certain measured distances down the limb. The points usually chosen are opposite the extreme upper limit of the splint, over the front of the knee joint, opposite the centre of the calf, and just above the ankle; all the marks are made in the middle line in front. The circumference of the limb at each of these points is then ascertained, and a series of strips of bandage or plain white paper corresponding in length to half these diameters is prepared. A piece of house-flannel, eighteen inches wide, and the length of the intended splint, is then laid upon the table, and the strips of paper or bandage are laid upon the flannel in due order, as ascertained by measurement with a tape, commencing at its upper

limit. From these guides the pattern for the lateral splint is then cut out (see Fig. 3). The foot piece must be exactly at right angles, and must not extend further forwards than just behind the ball of the great toe. A small triangular gap or a simple slit of about two inches long is then made at the angle in front of the ankle, and a small slit is made over the point of the heel. This is to allow the proper adaptation of the splint to the limb.

By these means a lateral splint which will extend from the middle of the thigh above, to the middle of the sole below, and from the middle line of the limb behind to the middle line in front, is obtained. Three other pieces of house-flannel are then cut to this pattern, and the four pieces are arranged in two pairs, which are laid upon the table. This should be done in such a manner that the two innermost pieces, namely those that will lie against the skin, should be next to the table. A large mackintosh, or several sheets of newspaper, are then placed beneath the affected limb, so as to protect the bedclothes, and the whole of the

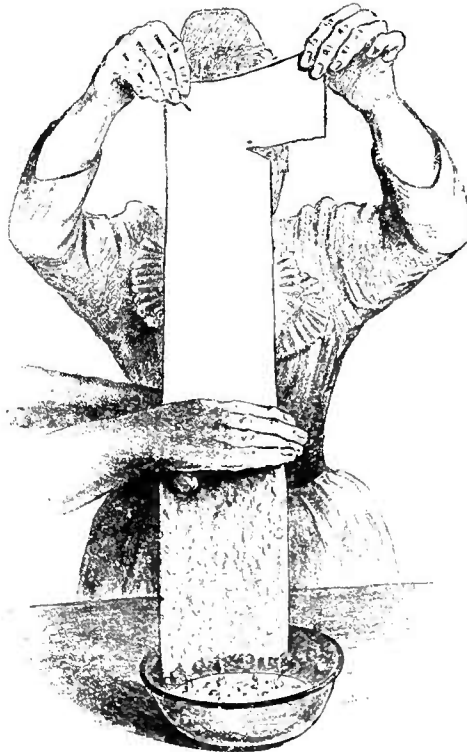


FIG. 4.—CROFT'S SPLINT. *Removing the excess of plaster from the lateral portions.* This shows a simple way of ensuring an even distribution of the plaster.

extremity is thoroughly oiled in order to prevent the splint sticking to the hairs of the limb. The surgeon then proceeds to mix the plaster of Paris,

which should be of the very best quality, and quite free from hard lumps or masses; in mixing it, cold water only should be used, as, if hot water be employed, the plaster is very likely to set before there is time to bandage the splint on.

The best method of mixing plaster of Paris is to put a sufficiency of cold water into a basin, and then to dust the plaster into it by hand without attempting to stir it until the plaster ceases to sink in the water. The first plaster dusted in sinks at once, and this will continue until the water has become saturated, when the plaster floats upon the surface; this may be taken as an indication that enough has been added to the water to enable it to solidify into a firm mass which will not crack and will not set too rapidly. When the saturation point is reached, the plaster should be thoroughly stirred up with the hand, so as to break up any lumps; when mixed it will be of the consistency of thin cream. The outer layer of each of the lateral splints is rapidly immersed in this and thoroughly impregnated with it; as this is done each piece is raised from the plaster in the vertical position, and any excess upon its surface removed by passing the hands down it (see Fig. 4). As each layer is prepared, it is laid down in position upon the unplastered portion which remains on the table.

This finishes the preparation of the splints; the next step is to bandage them on. Each lateral splint (consisting of the inner unplastered and the outer plastered layer) is raised and applied to its respective side of the limb, and, while this is being done, the surgeon sets the fracture and

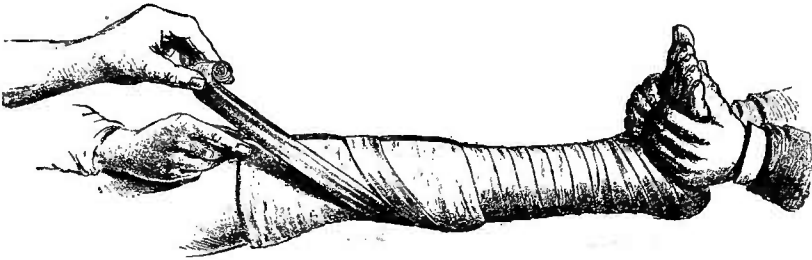

FIG. 5.—CROFT'S SPLINT. *Bandaging on the lateral portions.* The surgeon holds the fracture in good position and the foot at right angles, an assistant keeps the lateral portions in position at their upper end, while a second assistant applies the muslin bandage.

holds the limb in position, taking care to see that the foot is at right angles with the leg. As he does this, he grasps the foot-piece of the two lateral splints, whilst an assistant holds them together at the upper part of the thigh; a second assistant rapidly bandages them in place (see Fig. 5).

The bandages used for this purpose are of ordinary book-muslin, about two and a half inches wide and of sufficient length. They are not impregnated with plaster at all, but are merely steeped in hot water. They should be applied smoothly, evenly, and without any compression. The plaster shrinks slightly as it dries, and therefore if the splints were at all



tightly bandaged on there would be a risk of undue compression when they dried. The bandaging must be done rapidly, as otherwise the plaster will set before it is done, and the splint will not fit smoothly and evenly. It is of great importance not to impregnate the flannel with the plaster until everything is ready for immediate application of the splints, as it is generally found that, by the time the bandaging has been completed, the plaster is already fairly firm.

After the splint has been applied, a hood of cotton-wool is put over the toes, and the limb left exposed upon the bed for two or three hours to dry thoroughly. Any rough edges, etc., of the splint either above or below should be trimmed off with strong scissors, before the plaster has thoroughly set.

If there be no signs of undue pressure upon the limb, such as great pain, lividity or anæsthesia of the toes, the splint should be left untouched for twenty-four hours; at the end of this time the gap along the middle line of the front of the leg and the sole of the foot, which is merely covered by a few layers of muslin bandage, should be cut down with scissors, and the casing thus converted into two lateral splints hinged together behind by the muslin bandage. The fracture may thus be easily inspected, the limb being held in position in one half of the splint while the other

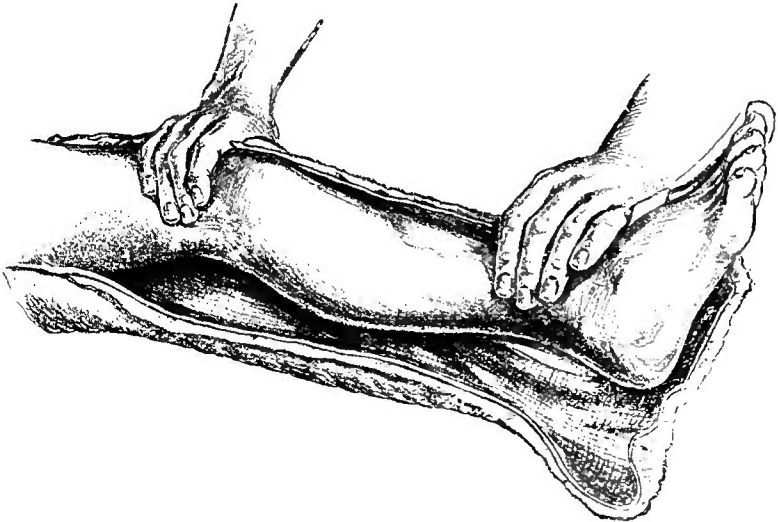


FIG. 6.—*Method of examining a limb in a Croft's splint.* The limb is held steady in one half of the splint while the other is opened out.

is turned back (see Fig. 6). The edges of the splint are then trimmed and it is reapplied by means of an ordinary bandage. In this condition it may be left until all danger of complications has passed, and then if desired it may easily be converted into an immovable plaster of Paris casing by applying an ordinary plaster of Paris bandage over the two lateral splints.

*Precautions.*—There are several small precautions necessary in order to put on this splint successfully. The plaster should be perfectly dry and of good quality and it is well to spread it out before a fire previous to use. In cutting out the splint, allowance should be made for the slight shrinking of the flannel that occurs when it is impregnated with the plaster. The best plan is to make the lateral pieces large enough to meet in the middle line front and back. When they are impregnated with the plaster of Paris they will shrink sufficiently to leave a slight gap down the middle line in front while they are in contact behind. Care should also be taken in applying the splint to see that the lateral halves do not overlap behind and that they hang evenly without creases along the side of the limb, so that when the bandage is applied they are moulded smoothly to its surface. The bed-clothes and carpets or floor of the room should be protected from the plaster by means of mackintoshes, sheets or newspaper, and the surgeon should wear a large apron to protect his own clothes. He will find it well to oil his hands before mixing the plaster, as this facilitates its removal subsequently; this is still further aided by the use of common brown sugar rubbed well over the hands as they are washed.

*Advantages.*—This method is a very valuable one, and in many cases has great advantages over any other plan. It is perfectly simple, the materials are readily obtainable, the splint can be applied with extreme rapidity, and, as it takes its purchase from the bony prominences of the limb, to which it fits perfectly, the fracture is absolutely immobilised and there is no undue pressure anywhere. It has, moreover, the merit of being extremely comfortable, and during the drying of the plaster not only is the sense of cold produced very agreeable to the patient, but the slight contraction that takes place tends to restrain the effusion. It is pre-eminently suited for fractures of the leg; in the thigh it is not so much to be recommended as, owing to the difficulty of getting proper purchase upon the bony prominences of the trunk, the same amount of immobility is not produced. It may be used for many compound fractures as well as simple ones, as it is quite easy to apply and re-apply dressings beneath it, the limb being held firmly by an assistant in one half of the splint whilst the other is turned back and the dressing changed. In those cases of compound fracture however where, owing to the amount of discharge, large quantities of dressing are necessary, it is perhaps better to employ some other method (see p. 34).

*Objections.*—An objection sometimes urged against Croft's splint, is that if there be much swelling when it is first applied, the casing may become too large for the limb when the swelling subsides. This can be easily met in any case in which the swelling is pronounced by allowing a larger interval than usual in the middle line in front between the opposite edges of the splints; then, when the swelling subsides, all that is necessary is to bandage the splints more closely together. A danger that is sometimes urged against this method, namely, that there is a risk of gangrene

of the limb or sloughing of the parts over the fracture from an increase of effusion beneath the unyielding case, can be entirely obviated by the most ordinary care. It should be a cardinal rule in all cases in which a Croft's splint is applied, that the splint should be opened up in the manner above described directly any symptoms of pressure are manifest; of these the condition of the toes is the most reliable guide. Should they become livid in colour or should there be tinglings or numbness of them, it must be taken as an indication to open the splint immediately. If there be great and steadily increasing pain referred to the seat of fracture, the splint should also be opened at once and the pressure relieved. In any case the splint should, as a matter of routine, be cut up at the end of twenty-four hours, and re-bandaged, after the fracture has been inspected.

*The second form of Croft's splint* consists of a somewhat trough-shaped posterior splint and a narrow anterior piece, and has the merit that it requires less nicety in application whilst it has the disadvantage that, composed as it is of an anterior and posterior portion, it is not so suitable for those recent fractures in which it is necessary to have more than the anterior part of the limb easily accessible to inspection. It is perhaps most useful for fractures in which a certain amount of consolidation has taken place; it is also very useful for fixing the limb in various cases of joint disease. It is made of house-flannel as before, and each anterior and posterior portion consists of two layers, both of which are saturated with plaster. The shape of the two portions of the splint is shown in Fig. 7. No accurate measurements are needed for either portion. The




FIG. 7.—CROFT'S SPLINT. *Shape of the anterior and posterior portions.* The upper one is the narrower anterior piece. The relative width of the two portions can be varied at will to suit the needs of any particular case.

posterior layer should embrace two-thirds of the circumference of the limb, the anterior a little less than one-third. When the flannel has been cut out, the two layers of the posterior portion are impregnated with plaster of Paris, mixed as above (see p. 16), held in position along the back of the limb, and bandaged on either with an ordinary muslin bandage or one of the book-muslin bandages used in the first method of applying Croft's splint. The two layers of the anterior portion are next similarly impreg-

nated with plaster, applied over the front of the limb (of course outside the bandage securing the posterior portion), and fastened in position by a second bandage. The whole apparatus is then allowed to dry thoroughly. This is a simpler plan than that often adopted of holding both anterior and posterior portions in position at the same time, and bandaging them on together (see Fig. 8); but the latter method is the one that would be adopted

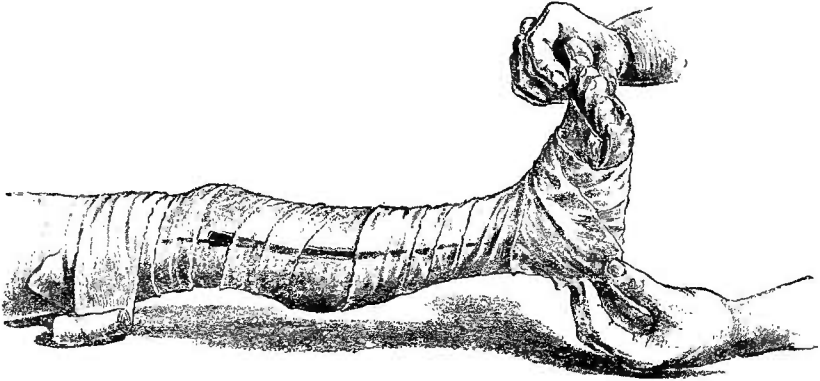


FIG. 8.—CROFT'S SPLINT. *Application of the anterior and posterior portions.* The illustration shows the interval down the side of the limb between the two portions.

for choice in recent cases of fracture, for instance in children, where the simultaneous bandaging of the two portions of the splint would involve less disturbance of the limb. The splint may be left undisturbed as long as may be found desirable; when it is removed, the muslin bandage is cut up on either side of the anterior portion of the splint, which thus is made to form a

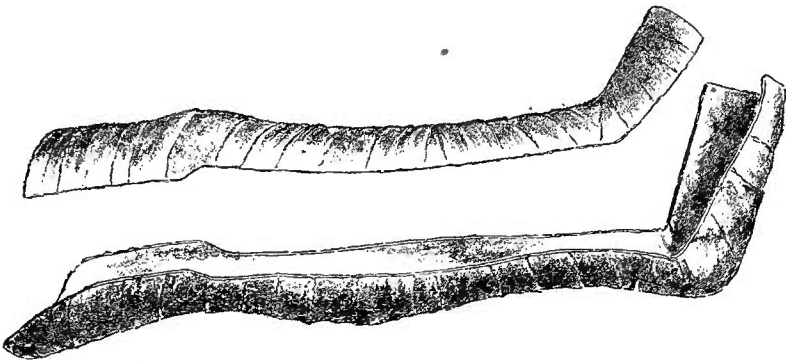


FIG. 9.—CROFT'S SPLINT. *The antero-posterior splint removed.* The figure shows the trough-like splint thus formed.

sort of lid to the trough formed by the posterior portion. (See Fig. 9.) All the superfluous bandage is then removed and the splint re-fastened in position by an ordinary bandage.

In a muscular or restless patient it may be necessary to further strengthen either form of Croft's splint. This may be done by incor-

porating with the splint strips of block tin or thin malleable iron bent in the required direction, and applied over the weakest spots. If these be not at hand a very efficacious method is to tease out tow into strips, dip them into the plaster and apply them to the parts that require strengthening. In the case of a splint for the lower extremity this will be about the ankle joint.

**The Bavarian splint.**—Another form of plaster of Paris casing is the Bavarian splint already alluded to. This is a very light and comfortable

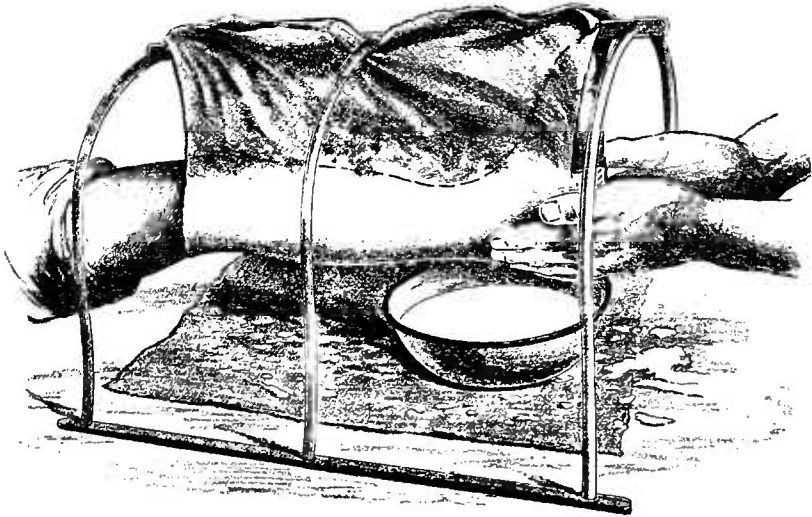


FIG. 10.—BAVARIAN SPLINT. *Method of application.* The inner layer of flannel is being smeared with liquid plaster. The outer layer is seen beneath the basin and is ready for application to the plastered surface.

splint, and may be employed where much strength is not required. It is made by suspending the limb in a sufficiently large piece of house-flannel fastened above to a cradle, and then stitching the flannel together over the front of the limb in the middle line down the leg, and along the front of the instep and the middle line of the sole. Plaster of Paris is then mixed as directed above, and the outer surface of the flannel is smeared with it to the requisite thickness (see Fig. 10). Outside this another layer of flannel is




FIG. 11.—BAVARIAN SPLINT. The splint has been removed from the limb and finished by binding the edges with leather, and punching eyelet holes in it.

immediately applied in a manner similar to the first. In this way an accurately moulded splint is formed, consisting of a layer of plaster of Paris of variable thickness enclosed between two layers of flannel. When the plaster has

thoroughly dried, the limb is taken down from the cradle, the superfluous flannel cut away, the stitches removed and the splint taken off by bending it open (see Fig. 11); the edges are then trimmed up and bound with leather, punched with eyelet holes, and the splint re-applied and laced firmly in position.

**Plaster casing.**—Plaster of Paris is also frequently used as a permanent immovable casing. For this purpose specially prepared bandages are requisite; they are made of crinoline muslin about four inches in width into the meshes of which plaster of Paris is rubbed. The limb is first enveloped in a bandage of boracic lint; a sufficiency of plaster is mixed in a basin as already directed, and the plaster bandages, which should have previously been immersed in enough cold water to cover them, are then rapidly applied to the limb, from below upwards. They should be applied evenly and not at all tightly. During the application of the bandage the surgeon from time to time smooths it out and adds liquid plaster wherever necessary. If the bandage require extra strengthening this may be supplied by means of block tin or tow saturated with plaster as already described (see p. 21).

Some surgeons employ this method from the first; it has, however, the great disadvantage that, besides being cumbrous and heavy, it takes a considerable time to remove, and it is generally necessary to employ either special shears or a saw for the purpose.<sup>1</sup> It is best, however, to confine the use of this form of casing to fractures in which sufficient time has elapsed for the risk of complications to have passed. Cases have occurred in which, in recent fractures, swelling has taken place beneath the plaster, and gangrene of the extremity has resulted. Another disadvantage is that, if it be put on a swollen limb, the splint becomes loose when the swelling subsides, and there is no means of remedying this, short of removal of the splint and the application of a fresh one. This is objectionable because, apart from the difficulty of removing the splint, it entails considerable disturbance of the fracture.

**The Silicate bandage**—A still lighter and more satisfactory material, which is very useful in the upper extremity or in fractures occurring in children, is the silicate bandage. In employing this, the limb is first enveloped in a bandage of boracic lint, and bandages of crinoline muslin, thoroughly soaked in a solution of silicate of potash, are then applied outside and left to dry. As a rule three or four thicknesses of bandage are sufficient to ensure a light and fairly firm casing. This splint has the disadvantage that it does not thoroughly set for at least four and twenty hours, and

<sup>1</sup> The easiest and most expeditious way of removing plaster of Paris casings of all kinds is by means of Gigli's wire saw. When the casing is applied, a piece of stout string is laid along the limb immediately outside the boracic bandage, between it and the plaster, and left there. When the plaster is to be removed, one end of the wire saw is attached to one end of the string, the other end of the latter is pulled upon, and the string is thus withdrawn, leaving the saw in its place beneath the plaster. The handles are then hooked on to the saw, and the casing may be cut through by it in a few seconds.

therefore, when it is used, a temporary splint should be fastened to one side of the limb so as to control the fracture until the bandage has set. It has, however, the great advantage of lightness combined with strength and easy applicability; in children it has the additional advantage that when applied to the thigh it does not so readily become softened and soiled with urine as does plaster of Paris.

**3. Extension apparatus.**—It is often a matter of considerable difficulty to prevent over-riding of the fragments and recurrence of the deformity when extension is taken off; this is more especially the case in fractures of the femur, where the thigh muscles are so powerful that they may overcome any fixation apparatus. The fractured ends are deeply seated and cannot be fixed by splints, and it is moreover extremely difficult to control the movements of the hip joint. In these cases, therefore, in order to obtain a satisfactory result it is necessary to employ one of two methods, namely, either extension, with the object of maintaining the reduction and tiring out the muscles, or operative measures which mechanically fasten the broken ends of the bone together.

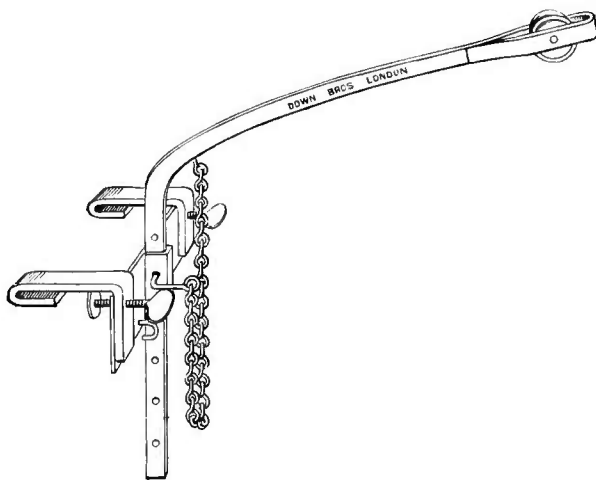


FIG. 12.—PULLEY ARM FOR WEIGHT EXTENSION. The apparatus is fixed to the frame of the bed, and can be raised or lowered at will.

As a rule most surgeons employ some form of extension apparatus in these cases. In fractures of the femur, extension may be made either by a weight passing over a pulley, or by traction applied from the end of a splint fixed to the limb. In all cases where extension is to be employed there must be not only the extending force which pulls the fragment down into position, but also some form of counter-extension to prevent the upper part of the limb and the trunk being displaced.

**Weight extension.**—Here the extension is applied by a weight at the end of a cord attached to the limb and passing over a pulley at the foot of the bed (see Fig. 12). The pulley should be so arranged that the cord

by which the extension is made lies in the long axis of the limb. The weight is connected with the limb by means of strapping applied in the following manner; we shall take as an example a fracture of the shaft of the femur.

The whole limb is first shaved so as to avoid the inconvenience that the adhesion of the strapping to the hairs would entail upon the patient. Two pieces of strapping are then taken, one for each side of the limb, and long enough to reach from about six inches beyond the sole to a point about four or five inches above the seat of the fracture. They should be broad enough to almost entirely cover the lateral surface of the limb on each side, and hence they will be wider in the thigh than in the leg, and will gradually taper as they approach the ankle.

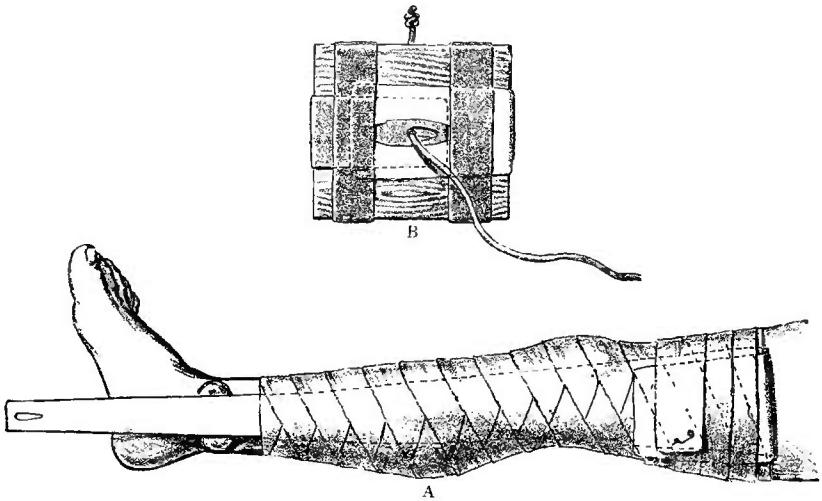


FIG. 13.—STIRRUP FOR WEIGHT EXTENSION. The lower figure A shows the shape of the lateral pieces of strapping applied to the limb by a bandage, and the manner in which the upper end is turned down and the bandage carried downwards over it. The pad above the malleoli is also shown. The upper figure B shows how the lower ends of the two lateral pieces of strapping are fixed to the footpiece. The end of one piece overlaps that of the other, the holes through the wood and the two pieces of strapping are superposed and narrow strips of strapping applied at right angles to the ends of the long ones bind them firmly to the wood.

The strapping is applied to each side of the limb so that the lower ends project six inches beyond the sole, whilst the upper end reaches to about four or five inches above the seat of the fracture. As ulceration is apt to occur over the malleoli from the pressure of the strapping, a pad of boracic lint should be interposed between the latter and the skin over the base of each malleolus, so as to ensure that the strapping shall pass clear over these prominences without touching them. A bandage is then applied firmly and smoothly from below upwards, and carried up to just below the seat of fracture. The free upper ends of the strapping are then turned down, and the bandage is continued downwards over them until they are completely covered (see Fig. 13, A). Some surgeons fix the lateral pieces by two or three circular strips of strapping applied above the



malleoli and just above and below the knee, and then put on a bandage outside this. No doubt this prevents the strapping from slipping more effectually than does the bandage alone, but as the strapping slips it pulls on the circular bands, and is therefore apt to lead to constriction of the limb.

A small square of wood, a little wider than the transverse diameter of the ankle and with a hole through the middle of it, is then attached to the free lower ends of the strapping. This is readily done by splitting these ends for about half an inch, and fixing them over the under surface of the piece of wood. The slit in each piece lies over the central hole in the wood, and through this hole is passed the cord from the weight extension; on the upper surface of the wood it is tied into a large knot so that it will not slip out. The fixation of the wood in the strapping is completed by narrow strips passing transversely around the broader pieces (see Fig. 13, B). This wooden foot-piece should be absolutely at right angles to the axis of the limb, and should not touch the sole anywhere. The free end of the cord is then passed over the pulley and the weights are attached to it, the pulley being so arranged that the cord and weights swing free of the

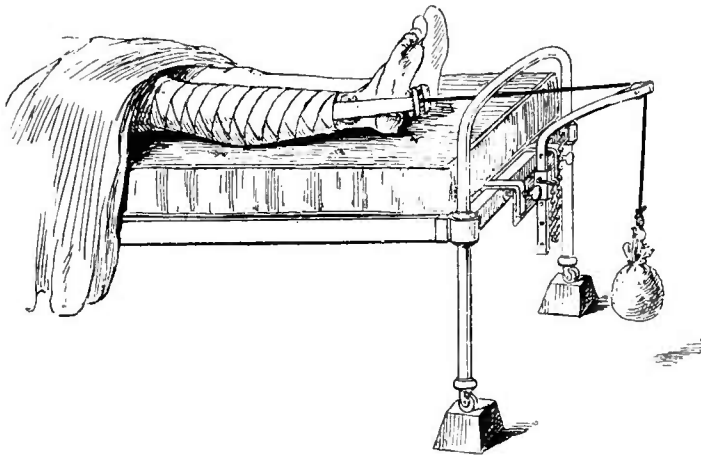


FIG. 14.—WEIGHT EXTENSION APPLIED TO THE LOWER LIMB. The limb, with the stirrup applied as shown in Fig. 13, is extended by means of a cord passing over the pulley shown in Fig. 12. The foot of the bed is raised on blocks to provide counter-extension.

bed. The weight employed depends upon the muscularity of the limb and the degree of contraction of the muscles; it usually varies from four to eight pounds. The apparatus should be carefully examined from time to time to see that it does not slip; it generally requires to be renewed every ten days or so. It is also important to see that the toes do not become pointed. The metatarsal bones should be supported by a sling, the ends of which are pinned to the bandage around the leg, and the pressure of the bed-clothes should be avoided by using a cradle. Further, it is im-

portant to see that there is no outward rotation of the limb unless that should seem desirable in order to bring the lower fragment into the axis of the upper.

Counter-extension is provided for by raising the foot of the bed on blocks so that the patient lies upon an inclined plane; the trunk tends to slide down towards the head of the bed and produces satisfactory counter-extension (see Fig. 14).

**Vertical extension.**—Vertical extension of the limb, as recommended by Mr. Bryant, may be employed for fractures of the femur in young children. The stirrup is here applied as before, but instead of being attached to a weight extension at the foot of the bed, it is fastened by a cord to a transverse bar above the cot. The limb is drawn up into the vertical position, and the cord tied to the bar so that the buttocks are lifted just free of the bed. The sound limb should also be tied up to the bar above the cot so that the child cannot relax the extension upon the fracture by putting the sound limb upon the bed and raising himself upon it. This method will be referred to in more detail under fractures of the femur (see Chap. VI.).

**Splint extension.**—In other cases the extension may be made by traction from one end of a fixed splint. The best example of this is known as Liston's long splint, and has the advantage over simple weight extension that it steadies the limb and can be made to prevent rotation; at the same time, however, the extension is apt to cause irritation and ulceration about the perineum. As this is essentially a splint for fractures of the femur it will be described when we come to deal with fractures of that bone (see Chap. VI.).

Whatever method of extension be employed, a point of great importance is that the patient's bed should be so arranged that it is impossible for the trunk to sink down into the mattress, as otherwise the fragments would be displaced and the traction which the extension has to overcome would be increased. To prevent this, the so-called "fracture boards" are made use of. They are firm, fairly stout planks of wood of a length corresponding to the width of the bed, and about a foot in breadth; they are placed transversely upon the frame of the bed immediately beneath the mattress, which should be firm and of medium thickness. If there be likelihood of bed-sores forming, a water-pillow should be placed under the lower part of the spine. A cradle should be placed over the affected limb to prevent the friction of the bedclothes and the pointing of the toes, which is very apt to occur from their pressure. A single blanket can be arranged over the limb so as to keep it warm, while the cradle supports the chief weight of the bedclothes.

**4. Mechanical fixation of the fractured ends.**—While the methods above described are generally satisfactory in the majority of cases, they nevertheless fail in some instances to keep the fractured ends in accurate apposition, and something further must be done to effect this.

In a considerable number of cases, moreover, notwithstanding the greatest care and ingenuity in fixing the fragments, true bony union may fail, or if it occurs there may be so much shortening and deformity as to seriously interfere with the usefulness of the limb. Formerly the danger of compound fractures was so great that both surgeon and patient contented themselves with the best results they could obtain without operation, but since the introduction of antiseptic surgery our views on the matter have undergone considerable expansion, and most surgeons at the present time do not consider it justifiable to leave the patient with an ununited or badly united fracture, if, by means of an operation, the fragments can be brought into and kept in proper position. Hence, in a large and increasing number of fractures, operative interference is being employed to obtain the best possible result. This is more especially the case in fractures accompanied by wide separation of the fragments, as, for example, those of the patella or the olecranon, and those in which the line of fracture is very oblique and the fragments over-ride considerably and are accompanied by so much deformity that a really good result cannot otherwise be obtained. Operative measures are also particularly necessary in fractures about joints—notably the elbow—where the displacement of the fragments interferes with movement, and where satisfactory re-position and retention of the fragments by manipulation and the application of splints cannot be obtained.

When operative interference is called for, it should be undertaken immediately after the accident; if it be delayed in the hope that a fairly good result may be obtained by non-operative measures, the most favourable time will have passed and it will be found a matter of great difficulty to rectify the displacement. Where the fragments are separated, as in old fractures of the patella, the muscles become shortened, and it is extremely difficult to get the fragments together again unless the muscle be partially divided; at the same time the fragments become so thinned and atrophied that they do not offer at all a good hold for the wires. If operation be delayed in oblique fractures with much overlapping or displacement, it will be necessary to saw through the union, and there will be great trouble in bringing the fragments into position, whilst it will be most difficult to exert enough traction upon the limb to overcome the shortening. And lastly, if operation be delayed in fractures into joints—for example, the elbow—it will be almost impossible to obtain a good result without chipping away portions of the articular surfaces or even excising the joint. All these difficulties can be avoided if operative interference be carried out soon after the fracture has occurred and before any consolidation has taken place—in fact, as soon as the surgeon sees that he cannot obtain a good result in any other way.

While in most cases—as, for example, where there is separation of the fragments—there need be no hesitation in operating at once, the surgeon may in others—as in oblique fractures—be tempted to wait. In the

latter case the decision may be greatly facilitated by skiagraphy, and all cases of oblique fracture should be examined by means of the Röntgen rays within two or three days of the accident; this can be done without removing the splints. If it be found that the position is bad, operative measures can be undertaken before much consolidation has taken place.

In performing these operations the first and most absolute essential is that strict antiseptic precautions should be employed; without them, of course, operation would be quite unjustifiable. The procedure consists in cutting down upon the fracture, clearing away all the blood-clot that is between and around the ends of the bone, removing any soft tissues that may have become interposed between the fractured ends, and then, bringing the latter into accurate apposition. As a rule, the mere getting the broken ends into position is not sufficient, and means must be taken to fix them firmly together until consolidation has occurred. This may be done by wiring them, by fastening them together with ivory pegs which are cut short and left in, with steel pins introduced temporarily and removed after some weeks, or with screws, as advocated by Mr. Arbuthnot Lane.

When there is separation of the fragments—such as occurs in fractures of the patella or the olecranon—it is sufficient to bring the fragments together and to pass a wire from one to the other in the manner which will be described later on. In fractures of the shaft of a long bone, however, particularly when they are oblique, wiring is not the best method. The wire to a certain extent no doubt keeps the ends of the bone together, but it is not sufficient to prevent movement between the ends, and besides, after a few days, the wire tends to cut through the bone, and shortening may subsequently recur. Hence in oblique fractures and those in the neighbourhood of joints, or where it is necessary to fix a small piece, pinning, pegging, or screwing the fragments together is the better plan. These methods will be referred to in greater detail when we discuss the operations for ununited fracture.

**THE PREVENTION OF ADHESIONS IN JOINTS AND MUSCLES** and the promotion of the nutrition of the parts. This important indication in treatment may be considered under two heads—(a) the after-treatment in cases of fracture where splints are chiefly relied upon, and (b) the after-treatment in cases where massage is chiefly employed.

(a) **In cases where splints are employed.**—Two important points still remain to be considered—namely, how long should absolute rest of the part be maintained, and how long should the use of splints be continued. The length of time which fractured bones require for bony union to occur varies considerably, but usually in the case of the upper arm displacement is not likely to recur after the lapse of four weeks, and in the case of the leg after about six weeks, and it is the practice with many surgeons to retain the splints for this length of time. After they are left off, a considerable time often elapses before the patient regains

the full use of the limb, partly because the muscles have shrunk from disuse and partly as a result of the hæmorrhage into them, while at the points where the muscles and other soft tissues pass over the fracture adhesions are apt to occur which are only got rid of with considerable difficulty. This is especially marked in fractures in the immediate vicinity of joints. In these cases, if the part be kept at rest during the whole time required for bony union, at least temporary stiffness of the joint is certain to occur, and, unless vigorous measures be taken, more or less permanent stiffness will ensue, notwithstanding that the fracture may have united in good position. Hence the tendency among surgeons now is to shorten the length of time during which splints are kept on, as far as is compatible with safety, or at any rate to take measures during the course of the treatment to prevent the occurrence of these adhesions. We shall indicate immediately the various steps of the procedure we are accustomed to employ to attain this end.

**(b) In cases where massage is mainly relied upon.**—A plan has lately come into vogue, chiefly among French surgeons, by which a case of fracture is treated from the first by massage, to the almost entire exclusion of the use of splints. In some cases, indeed, splints are practically not employed at all, whilst in most they are merely put on as a restraining apparatus in the intervals between the massage, the limb being quite free of them during that process. The massage is, of course, applied with the objects already detailed (see Part I., p. 22), namely, to produce absorption of the effused blood and inflammatory products, to ensure free movement of the neighbouring joints, tendons, and muscles, and to prevent the occurrence of adhesions or to break down any that may have formed; it is considered that the slight movement necessarily imparted to the fractured ends when these processes are employed is not prejudicial to the proper union of the fracture.

While we ourselves are not prepared to entirely discard splints, we are inclined to think that the use of massage and carefully regulated passive movement may be associated with their use to a far greater extent than has heretofore been the case, not only without any risk to the union, but actually with great advantage to the patient; it is thus comparatively easy to put the limb into a condition in which the patient is able to commence using it freely as soon as the surgeon has ascertained that the broken bone is sufficiently firmly united to bear the weight of the body. This is, as everybody knows, not the case as a rule when fractures are treated by splints alone for a long period. When the splints are discarded, the limb is generally very much crippled, both from the occurrence of œdema, which is often very extensive and recurs every time the limb is in the dependent position for any length of time, and also from adhesions of the torn muscles to the tissues near the seat of the fracture; when the fracture is near an articular end, there are not uncommonly considerable adhesions in neighbouring joints. For example, in cases of Pott's fracture,

or in Colles's fracture, the trouble in the treatment is not so much in the reduction of the deformity and the promotion of coaptation, as in restoring to the patient a useful functional limb; the after-treatment has to be carried out with the greatest care and assiduity for a period often measured by months.

It is claimed, and, as far as our own experience goes, we are inclined to think with some show of truth, that by using massage early, freely, and repeatedly, dispensing with splints and employing passive movement as soon as possible in the course of the case, the result is that union takes place as readily as when the case is treated by splints alone, and that, moreover, when union has occurred there are no difficulties such as stiff joints, muscles, or tendons to be treated. This method, of course, necessitates more attention, occupies more time, and calls for the application of more skill than does the ordinary method of reducing the fracture, putting it up in position, and maintaining the splints in place until satisfactory union has occurred; moreover, of course, it is not applicable to every case. The typical cases for which it is used are those in which the fracture is simple, is free from ordinary complications, is easily reduced and maintained in position by means of some simple splinting or retentive apparatus. We shall therefore describe the steps of the treatment in detail.

In putting up the limb it is well to choose some form of splint in which the strapping or bandages can be so applied as to leave the seat of fracture and the parts in its neighbourhood as thoroughly exposed as possible. In the first place, simple rubbing of the limb in an upward direction with the palm of the hand should be employed for about ten minutes at a time, once daily. This may be begun from the very first, and is frequently extremely soothing to the patient; after the first few days it may be done twice daily, and each sitting slightly increased in length. It is well also to flex and extend the toes in fractures of the leg, or the fingers in fractures of the forearm, at least once a day; this can be done without disturbing the fracture. The effect of the rubbing will be to rapidly bring about a diminution of the pain and swelling, and by the end of the first week it will be possible to remove the bandages from the extremity of the limb, so as to leave the ankle and foot, or the wrist and the fingers, free. In addition to the performance of simple rubbing, which should be carried on as before, passive movements of the joints should now be performed once or twice daily. This is a matter of great importance, and calls for considerable care. The seat of fracture should be carefully steadied by one hand, whilst the joint is moved with the other. Great care must be taken to extend the range of the movements only very gradually, and it is often found at first that there is some pain in its performance; this, however, soon subsides. This movement should be carried out until about the tenth to the fourteenth day after the injury; during this time, of course, the limb is not taken off the splint.

The next step is to carefully lift the limb off the splint and lay it

upon a firm flat pillow. The rubbing and the passive movements can now be carried out more vigorously than before; they may be repeated in sittings lasting from twenty to twenty-five minutes at a time, twice a day. After a week or two of this treatment—by which time the fracture will be about three weeks old—a fair amount of union will have taken place between the fractured ends, and some shorter form of splint, preferably a poroplastic one which does not embrace the joint below, may be substituted for the more rigid apparatus. If the fracture be in the lower extremity, the patient may get about on crutches with a patten on the sound foot; he should be encouraged to move the ankle as much as possible, although of course he must not bear any weight upon it. Massage and passive movement of the ordinary type should still be persevered with as before, until the consolidation is sufficient to allow the weight to be borne upon the limb, when the patient will regain practically complete use of the limb without any loss of time.

It is scarcely necessary to say that this form of treatment requires to be carried out with the greatest care, and by a trained masseur if the surgeon be unable to do it himself. In the cases for which it is specially valuable, namely, fractures in the vicinity of joints, such as Pott's fracture, Colles's fracture, or fractures in the vicinity of the elbow-joint, the treatment is if possible still more difficult to carry out satisfactorily than in the more ordinary forms, and demands greater care in preventing undue mobility of the fragments when the passive movements of the joints are carried out.

This method, which is the one we are accustomed to employ, seems to us the best, as it strikes a mean between the somewhat rash disregard of the use of splints, advocated by some of the French surgeons on the one hand, and the undoubtedly unsatisfactory method of their prolonged use on the other.

#### TREATMENT OF COMPOUND FRACTURES.

In compound fractures the first and absolutely essential point is to secure asepsis of the wound. In former days compound fractures were amongst the most dangerous of injuries, and it was in connection with their treatment that Lister began his antiseptic work. Unless the wound be rendered aseptic, it becomes the seat of septic inflammatory troubles, and the medulla of the bone being exposed, the most grave results very frequently arise. The septic inflammation does not remain limited to the soft parts, but may spread to the medulla and extend upwards as a violent septic osteomyelitis, which in many cases leads to a fatal pyæmia; or, if the patient survive after a prolonged and dangerous illness, necrosis of the bone results and perhaps after all amputation becomes necessary. Indeed, so dangerous was compound fracture in former times that many surgeons looked on amputation as the best routine practice in the great

majority of instances, even when there was no injury to vessels, nerves, etc. We now know that wounds exposing a bone or its medulla, if aseptic, are not more serious than wounds of the soft parts, and therefore there is no reason for amputation on account of the fractured bone alone, provided only that the wound can be rendered aseptic. In compound fractures, however, the wound has not been inflicted by the surgeon and is therefore usually soiled, and the problem is, not to prevent the entrance of micro-organisms, but to destroy those which have already gained admission; it will of necessity happen that in a certain, though fortunately only a very small, number of cases, the attempt to render the wound aseptic fails.

**WHEN THE WOUND IS CONSIDERABLE.—Treatment of the wound in the soft parts.**—We have already referred to these points (see Part I., p. 184) in considering the treatment of wounds inflicted accidentally, but it may be well to recapitulate them here. In the first place it will be necessary in all these cases to administer an anæsthetic, and a tourniquet should be applied. The disinfection of the skin for a considerable area around the wound is then undertaken; in the case of a fracture, say in the middle of the leg, the whole leg should be efficiently purified. With this object it is soaked with turpentine to remove fatty matter, and then thoroughly scrubbed with soap and strong mixture (see Part I., p. 46); the whole limb must now be shaved and again treated with turpentine and afterwards with soap and strong mixture and a nail brush. The edges of the skin around the opening which leads to the fracture should in most cases be cut away; they are certain to be soiled and, as they are contused, rapid healing is not likely to occur.

The wound should be enlarged as much as may be necessary to obtain thorough access to the injured parts. There need be no hesitation in making a very large incision if necessary in order to see the condition of the deeper parts. All blood-clots should be carefully sponged out and all foreign matter or dirt removed; any contused tissue should be clipped away and the whole wound thoroughly scrubbed out with strong mixture.

**Treatment of the fractured ends.**—The ends of the bone should next be examined, and any loose pieces removed; if the fractured ends be very dirty, a thin layer should be sawn or gouged off them. In any case they should be carefully swabbed with undiluted carbolic acid. All parts of the wound also, except the incisions made by the surgeon, should be carefully sponged with the pure acid. It is of course necessary to see that the carbolic acid does not run over the edges of the skin, as otherwise union might be interfered with.

After having thus made certain that the whole of the wound and all its recesses have been carefully investigated and cleaned out, the tourniquet may be removed and any bleeding points tied. The tourniquet is employed in these cases to arrest the oozing which, if allowed to go on, would wash off the pure carbolic acid as soon as it was applied and would therefore interfere with its germicidal action. The position of the ends of



the bones should next be carefully ascertained ; in most cases it will be found well to fix them together either by wires, pegs or screws (see p. 51). The greater part of the wound may then be stitched up, but a large drainage tube should be inserted at the most dependent part and, if necessary, a counter-opening should be made. This drainage is necessary lest the attempt made to purify the wound should fail. Ordinary cyanide gauze and salicylic wool dressings are applied and wherever possible it is well to use a splint of perforated block tin or wire netting (see p. 11) which has been thoroughly purified. The purification is best carried out by boiling, as the grease often present on the metal may somewhat interfere with the action of ordinary antiseptics. The splint should be carefully moulded to the part and should be incorporated with the dressings ; in this way the fracture will be kept at perfect rest. Another splint may be applied outside the dressings if additional security be desired, and the limb should be put in the position best calculated to obtain relaxation of the muscles.

**WHEN THE WOUND IS VERY SMALL.**—When the wound is extremely small, the surgeon is frequently tempted to simply disinfect the skin and syringe out the wound, and then to apply an antiseptic dressing. No doubt in some cases these measures suffice, particularly when the skin wound has been caused by the protrusion of a sharp bony fragment which has receded immediately afterwards ; it is most likely to be effectual in parts that are not covered by clothes. At the same time it is impossible to be certain of the result if this treatment be adopted, and in the majority of cases it is better, even though the wound be very small, to enlarge it sufficiently to enable the whole of the interior and the ends of the bones to be sponged over either with strong mixture or with undiluted carbolic acid. The wound made by the surgeon can be stitched up again, and no delay in healing will take place. Should, however, the surgeon yield to the temptation to simply disinfect the skin and syringe out the wound, some care must be taken in carrying out the method. In the first place it is necessary to be sure that the lotion comes freely into contact with and washes away the clots from the ends of the bones, and secondly, it must be able to escape freely, and must not be driven along the various planes of cellular tissue. It is well, therefore, to attach a gum-elastic catheter to the syringe, to introduce its point through the wound, and, by inserting it in various directions, especially deep down in the neighbourhood of the bones, to see that the lotion comes thoroughly into contact with all the parts. The lotion should not be forcibly driven into the wound, and if the latter be small it will be necessary to enlarge it somewhat in order to allow of the free escape of the fluid. A good plan to ensure that the fluid is not driven into the tissues under pressure is to use for the purposes of the irrigation a catheter connected with a glass funnel by a few inches of indiarubber tubing.

**After-treatment.**—If the attempt at securing asepsis be successful, the course of events will be the same as after ordinary operations on bone.

If blood comes through the dressing during the first twenty-four hours, the bandage and the outer layers of wool should be thoroughly soaked with 1-20 carbolic lotion, and a fresh gauze and wool dressing applied outside. In any case the wound should be dressed in four or five days and the drainage tube removed. The limb is put up again with a wire splint incorporated in the dressings as before, and it need not then be disturbed for several weeks.

**When the wound becomes septic.**—Should it be found, however, that the attempt to obtain asepsis has failed, the case must be treated as a septic wound. If a high temperature and signs of osteo-myelitis supervene, the question of amputation will arise, and this will probably prove the safest practice where the patient is getting progressively worse, more especially if there be rigors; the amputation will be performed through or above the joint next above the fracture.

It is however generally found that, even should the case become septic after the thorough treatment just described, the free drainage provided renders infection of the medulla to any extent comparatively rare, and the limb may still be saved. Under these circumstances it becomes a question whether the wire or pegs employed for fixing the bones together should be removed or not. This will be decided by ascertaining whether much irritation is resulting from their presence; should there be very little, they may be left *in situ* for some weeks, because they tend to steady the bones; but if irritation is caused they must be removed.

In these septic cases frequent changes of dressings are of course necessary, and means must be taken to fix the parts so that they shall be disturbed as little as possible during the dressing; unless this be done, non-union will inevitably result. This end cannot be attained simply by trusting to an assistant to steady the limb. When lateral splints are used, it is sometimes possible to keep the parts sufficiently steady by removing one splint while the assistant holds the limb firmly in contact with the one on the opposite side; the dressing is applied to the side thus exposed, and then, after re-applying the splint on that side and having the limb firmly held in contact with it, the opposite splint is removed and the change of dressing carried out there also (see Fig. 6). This is, however, sometimes a matter of difficulty when the wound in the soft parts is at all extensive, and under these circumstances the following arrangement will be found more satisfactory. Two or three rods of malleable iron are taken and are bent outwards into a semicircle over an area corresponding to the region of the wound. The two extremities of these iron bars are then bound firmly to the limb by being incorporated in a plaster of Paris bandage (see Fig. 15). A bandage of boracic lint is first applied to the limb above and below the wound; over this a few turns of plaster of Paris bandage are put on, and then the metal bars are adjusted and their ends are covered in by fresh turns of the plaster bandage. An interruption is thus formed of sufficient size to allow of free access to the wound. In this way a firm splint, taking its

purchase from the limb above and below the wound, is formed, the whole of the wounded area is easily accessible, and dressings can be renewed as frequently as may be necessary without disturbing the fracture.

**When there is necrosis.**—Necrosis of the fractured ends is very likely to occur in septic cases, and after a time the necrosed portions will become loose and should be removed. The time required for this detachment varies from about six weeks in the case of the fore-arm to about six months in the case of the femur. Non-union is very apt to result when necrosis of this kind occurs. Therefore, as soon as the wound has healed, the interrupted splint just described should be dispensed with, and the entire limb should be put up in an immovable plaster of Paris casing.

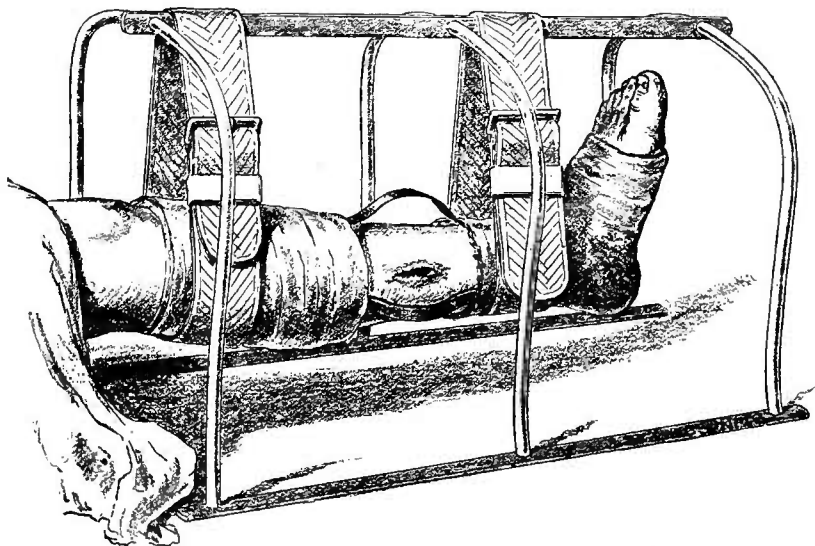


FIG. 15.—INTERRUPTED PLASTER OF PARIS SPLINT. A form of splint adapted to compound fractures, showing how the iron bars, incorporated with the plaster bandage, are bent to allow free access to the wound. The limb is slung from a cradle; as a rule the plaster bandage would be carried above the knee.

**WHEN THE DAMAGE IS EXTREME.**—While the methods just described may be looked upon as the normal treatment for compound fractures, cases nevertheless will arise even at the present day in which the question of *amputation* has to be decided first of all. Of course when a limb has been partially or completely torn off there will be no hesitation in deciding that the stump must be trimmed or the partially torn-off limb must be amputated. Similarly, when, in addition to extensive comminution of the bones, the main vessels, nerves and muscles are torn through, amputation will be the better practice; and again in badly lacerated wounds, such as machinery accidents, where the bone is much broken up and where the parts are badly lacerated and greatly soiled with greasy dirt, immediate amputation may also be called for. Again, in old persons or in those much enfeebled by constitutional disease, the quickest and most satisfactory plan of bringing

cases of bad compound fracture to a successful termination, especially when the bone is comminuted, is a primary amputation. But with the exception of these cases an attempt should always be made to save the limb whenever the surgeon feels that by careful purification and the establishment of satisfactory drainage he will probably be able to obviate the occurrence of septic infection and will therefore possibly be able to preserve a limb that will be useful to its owner. As will presently be mentioned, the mere rupture of the main vessels or nerves of the limb in addition to a compound fracture does not necessarily call for primary amputation. When the vessels are divided the case should be watched to see whether gangrene occurs, and amputation can be performed if it be found that within the first twenty-four or forty-eight hours this is inevitable. When the nerves are ruptured they should be sutured in the manner recommended for injuries of nerves (see Part II., p. 250) at the same time that the wound is purified.

It should also be mentioned that union is often considerably delayed in compound fractures, and it is not an uncommon thing to find that at the end of six or eight weeks the fragments still move upon one another. Indeed it may almost be said that this is the rule rather than the exception and that something like three or four months is necessary to obtain satisfactory union in the majority of compound fractures. It is somewhat difficult to understand why this should be, but probably it is due to the absence of the external callus, which plays a considerable part in the repair of simple fractures.

#### TREATMENT OF COMPLICATED FRACTURES.

The complications incidental to fractures may be divided into two groups—(1) Those that occur at the time of the injury and are due directly to it, and (2) those that occur during the subsequent progress of the case.

**IMMEDIATE COMPLICATIONS.**—The following are the chief complications occurring at the time of the accident. (*a*) The skin may be divided or torn in the vicinity of the fracture without, however, any communication with the fracture itself being established. (*b*) There may be an injury to the main artery of the limb. (*c*) Injury to the main vein. (*d*) Injury to the nerves. (*e*) Injury to a neighbouring viscus. (*f*) Injuries to joints. (*g*) Dislocation complicating the fracture. (*h*) Fatty embolism. There are other complications, but these are the most important.

(*a*) **Wounds of the skin not communicating with the fracture.** The treatment of a complication of this kind is simply that of a wound of the soft parts; the skin and the wound must be purified and the appropriate treatment for a lacerated wound must be adopted (see Part I., p. 191).

(*b*) **Injury to the main artery of the limb.**—In some cases the main artery of the limb may be completely torn across and profuse hæmorrhage may occur into the tissues. If the vessel be large and the tissues lax,

the patient may actually bleed to death. Failing this, a large blood swelling occurs, accompanied by loss of the pulse in the limb below and coldness and numbness of the extremity. In other cases the artery may be occluded by the pressure exerted upon it by one of the displaced fragments; or again, it may be punctured by a spicule of bone, with the result that hæmorrhage occurs from the aperture and a false or traumatic aneurysm ensues.

**Treatment.**—The treatment of these injuries is fully dealt with under injuries and disease of the arteries (see Part II., p. 293). In the case of a torn vessel it is very important to cut down upon and secure the divided ends or re-unite them as soon as possible. Delay will only render the operation more difficult owing to the infiltration of the tissues with blood and lymph; in addition, if the bleeding be allowed to continue, the interference with the circulation in the limb below the fracture will steadily increase and may, should the patient not succumb to the loss of blood, lead to gangrene from pressure upon the collateral circulation.

As soon therefore as the diagnosis is made, the skin should be thoroughly purified and the circulation controlled by an Esmarch's elastic tourniquet. A free incision is then made over the vessel, the clots turned out and the ends of the artery searched for and tied; if the latter be torn quite cleanly across, an attempt may be made to unite the divided ends (see Part II., p. 293). If the cavity formed by the extravasated blood be large, it is well to insert a drainage tube for the first two or three days.

The treatment of the fracture itself will follow the ordinary lines already indicated. If the fracture be oblique or if there be any difficulty in keeping the ends in position, it is well to take advantage of the incision already made and to fix the fragments together. After the wound has been stitched up, the limb should be put on a splint, the foot of which is slightly elevated.

In the second class of accident, where the circulation is interrupted by the pressure exerted upon the vessel by the displaced fragment—an accident which is indicated by loss of pulsation and by coldness of the limb below without the occurrence of any swelling at the seat of fracture—it is possible that, on effecting accurate coaptation of the fractured ends, the pressure will be removed and the circulation re-established. Should this not be the case, the limb below should be disinfected and wrapped up in salicylic wool, as described in the treatment of impending gangrene (see Part I, p. 64), and carefully watched to see whether the circulation returns or whether gangrene occurs. In putting the limb on a splint under these circumstances it is very important that no undue pressure should be exercised on any part, as otherwise, although the collateral circulation may be restored in the limb as a whole, sloughing readily occurs at any point where even slight pressure is exerted. Should gangrene occur, immediate amputation should be resorted to as soon as its extent can be gauged; as a rule it is well to amputate at or just above the seat of fracture.

(c) **False aneurysm.**—The treatment of false aneurysm has been

already fully described (see Part II., p. 297). Unless the aneurysm be rapidly increasing, it need not be operated upon until the fracture has undergone consolidation, for the occurrence of an aneurysm of this kind does not necessarily interfere with union, whilst the operation required for its cure might possibly do so.

(d) **Injury to the main vein.**—Injuries to the main vein occurring as complications of fracture do not materially aggravate the severity of the case. Repair and recovery usually take place uninterruptedly; all that is necessary is to facilitate the return of blood from the parts below by raising the limb slightly above the level of the trunk; at the same time the former should be enveloped in salicylic wool, so as to promote warmth. When both the main artery and vein are damaged simultaneously, the danger of gangrene is of course far greater than when the injury is limited to only one of these vessels, but usually, if proper care be taken to wrap the limb up in salicylic wool, to elevate it well, and to see that there is no undue pressure anywhere, recovery will occur.

(e) **Injury to the main nerve.**—The main nerves are sometimes torn by the fractured ends, and this accident is evidenced by the loss of sensation and motion in the part supplied by the nerves injured. When it is clear, on careful examination, that an accident of this kind has happened, the nerve ends should be sutured without loss of time (see Part II., p. 250). It must, however, be remembered that it is not always easy in a case of simple fracture to be quite certain that the loss of sensation in the parts below is due to actual rupture of the nerve and not to bruising or compression; if any doubt exists, it is well to set the fracture first and then to wait for a few days, or even as long as a week or two, to see whether recovery will take place. If at the end of this time no improvement occurs, it is probable that the nerve has been divided, and it will be well to cut down upon it at the seat of fracture without further delay. If it be found undivided, no harm will be done, whereas, if it has been torn, a long delay would only diminish the chances of a satisfactory issue.

Here, again, in putting up the fracture, it is very important to avoid undue pressure by the splint or other restraining apparatus, because parts which are imperfectly innervated are more prone to slough from pressure than are healthy tissues.

(f) **Injury to a neighbouring viscus.**—The treatment of a complication of this kind will, of course, be the treatment appropriate to the injury of the viscus affected, rather than anything specially directed to the fracture. The viscera which are most commonly injured are the lungs in fractures of the true ribs, the kidneys and spleen in fractures of the lower ribs, and the bladder and rectum in fractures of the pelvis. It is sufficient here to call attention to the fact that these injuries may occur; their treatment will be dealt with in the sections dealing with the injuries of these organs.

(g) **Wounds of joints.**—When a fracture is in close proximity to a joint, the articulation may be seriously injured. In simple fractures this may occur from the line of fracture itself running into the joint. For example, in fractures of the patella or the olecranon, the joint is, of course, necessarily implicated; this is also the case in fractures of the articular ends of bones, such as the condyles of the femur, the humerus, etc.

The difficulties that occur in these cases—with the exception of fractures of the patella and the olecranon, which will be subsequently referred to in detail—are not so much in promoting repair, as in preventing the occurrence of deformity and limitation of movement, which almost invariably result when these fractures are put up on splints in the ordinary manner. This is due to the fact that it is almost impossible, on the one hand, to get the fragments into proper position, and, on the other hand, to maintain them there when once they have been properly reduced. A very slight irregularity of the articular surface may lead to marked impairment of the movements of the joint; indeed, in many cases the resulting limb is so stiff and useless that the surgeon has subsequently to interfere and possibly to excise the joint. Hence when, on a careful examination under an anæsthetic of a fracture into a joint, it is evident that the fragments will not remain in accurate apposition after reduction, it is best to cut down upon the bones immediately, with rigid antiseptic precautions, and fix the fractured ends in position by means of wires, pegs, or screws.

Operation in these cases has the further advantage that the wires or pegs so introduced firmly fix the bones in proper position, and thus enable the surgeon to commence passive movements of the joint at a much earlier period than would otherwise be feasible. This prevents the occurrence of adhesions, which, apart from the displacement of the bony surfaces, is a very common cause of the subsequent disability of the limb.

Fractures may also be complicated by an injury to the joint in other ways; for example, a lacerated wound of the skin may extend into the joint, although the fracture itself does not. These cases must be treated on the lines appropriate for the treatment of wounds of joints, the fracture itself being put up and immobilised in the ordinary manner. When, however, in addition to the wound of the joint, we have a fracture also extending into it, the broken ends of the bones should invariably be fastened together when the joint is cleaned out, and in these cases free drainage must be provided, because there will always be a risk that the cleansing of the joint may not have been effectual.

(h) **Dislocation complicating fracture.**—This complication may be met with in two forms. In the first, the fracture may not be situated in the immediate vicinity of the dislocated joint, and under these circumstances the treatment is obviously to reduce the dislocation first and then to set the fracture and employ suitable retentive apparatus afterwards. Passive movement must here be begun at a very early period: if the limb

be kept at rest until the fracture has united, a hopeless amount of stiffness in the joint may have resulted. Movement can be practised with little risk to the union of the fracture, as the limb can be enveloped in a moulded splint and moved as a whole.

In other cases, however, as for example those in which the fracture is in the immediate vicinity of the dislocated joint, the complication is much more difficult to deal with. An example of this is seen in dislocation of the shoulder joint combined with fracture of the neck of the humerus. Under these circumstances it is exceedingly difficult to reduce the dislocation, for it is impossible to get a sufficiently good hold on the head of the bone to bring it into position. The old rule here was to put up the fracture with the long fragment in a line with the short one—*i.e.* the dislocated head—and, after the fracture had united, to attempt the reduction of the dislocation. If this attempt were unsuccessful, as was usually the case, excision was sometimes resorted to in order to get a useful limb.

The introduction of strict asepsis has, however, altered our views with regard to the treatment of this, as of many other injuries, and, considering the great difficulty and the frequent impossibility of reducing these dislocations after the fracture has sufficiently united to bear the necessary strain of reduction, it is now generally recognised that the best treatment is to cut down upon the head of the bone with all due antiseptic precautions at the time of the injury, to replace it in position, sew up the rent in the capsule, and then to reduce the fracture and treat it on ordinary lines. It is also best, if possible, to wire or to fix the ends of the bones together in some way at the time of the operation, so as to enable passive movements to be commenced comparatively soon, and thus to avoid the stiffness which is apt to result if the dislocated joint be not moved from an early period.

(i) **Fatty embolism.**—In severely comminuted fractures fat may enter the veins and be carried on in the circulation. This occurs to some extent in all fractures, but no bad effects result unless the quantity of fat which thus gains access to the circulation be great. When, however, large quantities pass into the veins, the fat globules may become impacted in the smaller vessels of the lungs, the brain, and the kidneys, and may give rise to very serious symptoms.

**Symptoms.**—The symptoms of fatty embolism following a simple fracture usually occur very shortly after the receipt of the injury. They generally come on within a few hours, and they naturally vary according to the seat of the embolism. When the emboli are lodged *in the lungs* there is the formation of infarcts, followed by œdema of the lungs and subsequent patches of pneumonia. In some very rare cases the emboli may be sufficiently numerous to kill the patient in the course of a few minutes. The symptoms of fatty embolism are sometimes difficult to distinguish from those of shock, but as a rule they do not come on for some hours after the injury, whereas the onset of shock is generally coincident with



the accident. The first symptoms are the occurrence of dyspnœa, which is generally very severe, accompanied by pain in the chest, cyanosis, and cough with frothy blood-stained expectoration. If the patient recover from this, signs of pneumonia develop.

When the fatty emboli occur *in the brain*, the symptoms are as a rule much more grave, and are essentially those of delirium, with coma later on. The pulse is small, rapid, and irregular, and the coma gradually deepens until death ensues; in some cases, however, the coma slowly passes off and recovery takes place.

The symptoms are rarely severe when the emboli are *in the kidneys*; at the most they may cause a certain amount of strangury and hæmaturia, but usually they manifest themselves only by large quantities of oil in the urine.

**Treatment.**—In all cases of fatty embolism the first thing obviously is to prevent as far as possible the further entrance of fat into the circulation. With this object the fracture must be reduced immediately and completely immobilised. When the patient is restless or inclined to be delirious, a Croft's splint (see p. 14) is the best apparatus to employ.

In the treatment of the embolism itself nothing specific can be done; all that is possible is to treat the symptoms as they arise. Stimulants are naturally strongly indicated, and they are best given by the mouth in the form of brandy, or in the more severe cases, when the brain is affected, in the form of subcutaneous injections of ether or brandy.

When the emboli are *in the lungs*, a very useful procedure is to cup the sides and back of the chest (see Part I., p. 6); later on, the application of a mustard leaf or mustard poultices (see Part I., p. 17) will help to relieve the dyspnœa. The patient should be kept warm and have plenty of fresh air. Inhalations of oxygen (see Part I., p. 196) should be employed if there be much cyanosis, and, later on, large poultices or fomentations may be applied to the chest. The bowels should be kept thoroughly open and the patient's strength supported by food, stimulants, and tonics.

**COMPLICATIONS OCCURRING DURING THE PROGRESS OF THE CASE.**—Various complications which require a brief notice may occur during the progress of a fracture. The following are the chief: (1) œdema of the part, pruritus and the formation of vesicles; (2) phlebitis and thrombosis; (3) gangrene; (4) the various septic complications, such as suppuration, erysipelas, cellulitis, tetanus, etc.; (5) œdema of the lungs and hypostatic pneumonia; (6) delirium tremens; (7) bed sores; (8) necrosis; (9) mal-union; (10) non-union; (11) inclusion of nerves in the callus; and (12) adhesion of muscles or tendons to the fractured ends.

(1) **œdema, pruritus, and vesication.**—The occurrence of œdema and the formation of vesicles over the region of the fracture are chiefly met with where the injury is due to direct violence, and where there has been much extravasation of blood. The conditions will of course be predisposed to by undue mobility of the fractured ends and by any pressure of splints or bandages.

**Treatment.**—The treatment consists in immediate reduction of the fracture and immobilisation of the limb in a slightly elevated position to favour the return of blood. If there be much tension of the skin and tendency to vesication, the splint should be so arranged that the affected part is accessible, and evaporating lotions, such as the ordinary spirit lotion or lead and opium lotion (see Part I., p. 8), should be applied. An ice-bag is often used, but great care must be taken in employing it on account of the depressing effect of the cold upon the already damaged soft parts, which may very readily undergo gangrene, and thus a simple fracture may be converted into a compound one. If used at all, it should only be in vigorous healthy subjects; some lint should be interposed between the skin and the ice-bag, and the condition of the parts frequently inspected.

If the itching be very troublesome, the skin should be dusted over with boracic powder, either alone or mixed with an equal quantity of starch, and the vesicles as they form should be pricked and the fluid let out; care should be taken that the epithelial covering of the vesicle is not removed. If the skin over the area of the fracture become eczematous, one of the best applications is diachylon ointment, or some simple ointment such as the quarter-strength boracic, or a dusting powder consisting of equal parts of oxide of zinc and boracic acid may be used.

Sometimes the tension is so great as to threaten gangrene of the skin; this is shown by increasing duskiness of the part, coldness, and anæsthesia. Under these circumstances gangrene may sometimes be avoided if the limb be thoroughly purified and free incisions be made through the skin into the subcutaneous tissues, so as to let out the blood and the inflammatory effusion and so to relieve the tension. If incisions be made in this way, the simple fracture will probably be converted into a compound one, and great care must therefore be taken to secure complete asepsis. The subsequent treatment will be that of compound fracture.

(2) **Thrombosis.**—This is a not uncommon complication, and is often unavoidable. It may occur either at the time of the accident, from injury to the veins, or may ensue later on as a result of the pressure of the effusion upon the veins of the part, and the occurrence of a slight amount of phlebitis. As a rule it is of little importance; at most it leads to some œdema of the limb below the seat of fracture. In some very rare cases, however, portions of clot may be detached and give rise to embolism elsewhere.

**Treatment.**—All that is necessary in the immediate treatment of this condition is to elevate the limb so as to favour the return of blood, to avoid tight bandages above the seat of fracture, and to keep the patient perfectly quiet so as to avoid the risk of detachment of portions of the clot. Care must afterwards be taken not to allow the patient out of bed too soon, as it is not at all uncommon in these cases to find that the result of getting the patient even on to the sofa is an extension of the thrombosis

from which detachment of the clot may result. The patient should be confined to bed or to a couch for a full fortnight after the spread of the thrombus has ceased.

(3) **Gangrene.**—This complication may arise as a result of the damage done to the main vessels at the time of the injury, or it may occur later from the injudicious application of splints or bandages. Some patients are particularly insensitive to pain, and if they have any, merely look upon it as a necessary consequence of the injury, and cases have occurred where fractures of the upper arm have been put up without any apparent tightness, and where subsequently œdema and gangrene of the hand have occurred without the patient complaining, until too late to obviate the mischief.

**Treatment.**—If this complication should occur from either of these causes the gangrene will be of the moist variety; its treatment is detailed elsewhere (see Part I., Chap. IV.). When the circulation is evidently imperfect, the limb should be disinfected immediately after the occurrence of the injury, and a gauze dressing applied; outside this a mass of salicylic wool is put on, and the limb raised on suitable pillows. If it be evident, after doing this, that gangrene will occur, amputation should be performed. There is no object in waiting, for it is obvious where the injury to the vessels has occurred, and in the course of two or three days at most it will be quite clear whether recovery will result. If amputation be necessary it should be performed at or about the seat of injury to the vessels, which will be at the seat of fracture.

(4) **Septic complications.**—These are of course much more likely to follow a compound than a simple fracture, but they may occur in simple fractures complicated by injuries of the skin, even when the latter are mere abrasions. When they do occur, even though they be mild in type, they naturally complicate the case to a marked degree, because the dressings must be repeatedly changed, and a considerable disturbance of the limb must result. Hence in all cases of fracture it is of great importance to examine the skin carefully for the presence of abrasions; if any be found, the wound in the skin should be thoroughly disinfected, an antiseptic dressing applied, and the limb afterwards put up in a proper retentive apparatus.

**Treatment.**—The treatment of these complications has already been dealt with elsewhere (see Part I.).

(5) **Œdema of the lungs and hypostatic pneumonia.**—Congestion of the bases of the lungs ending in a low form of pneumonia is a very troublesome and dangerous complication, especially in old people who are the subjects of a fracture of the lower extremity which confines them to bed in the horizontal position. Apart from this, pneumonia may also be caused by direct injury to the lung in cases of fractured ribs, but this form is usually only slight, limited and transient, and a fatal result seldom occurs from it except when the chest wall has been so extensively injured that respiration cannot be properly carried on. Pneumonia may

also occur in fractured spine high up in the dorsal region, and it is here one of the most frequent causes of death. It is due partly to the want of expansion of the lung as the result of paralysis of the intercostal muscles, and partly also to some trophic influence upon the nutrition of the lung itself. Its onset is often very rapid and it quickly ends fatally.

Œdema of the lung in old people confined to bed in consequence of a fracture is induced by the want of proper expansion of the bases of the lungs; the œdema usually commences about the end of the first fortnight after the receipt of the injury. If not treated immediately, it is apt to spread rapidly and bring about a fatal result, the bronchial tubes becoming choked with mucus, and the patient dying practically of asphyxia.

**Treatment.**—The great danger of this form of pneumonia after fracture of the lower extremity in old people should be borne in mind; it occurs most commonly after fractures of the neck of the femur, when it is necessary to subordinate attempts to obtain union of the fracture to treatment directed to avoiding this lung complication. Hence, even before any signs of congestion of the lungs occur, care should be taken to place the patient in such a position that the lungs may expand as freely as possible. Splints, if employed, should be so arranged that the patient may be propped up in bed almost in the sitting position; in fractures of the neck of the femur usually all that can be done in the first instance is to employ light extension, as any really efficient splint would prevent the patient being propped up. If the patient be simply raised on pillows he will slip down in the bed, and in a short time become almost horizontal; hence, in addition to a proper bed-rest, a foot-rest should be fixed opposite the sound limb so as to prevent this. At the same time the chest should be enveloped in layers of cotton wool, and nourishing food and stimulants administered.

If symptoms of pneumonia arise, it is well to surround the bed with a curtain or tent and to place a steam-kettle inside it, so that the patient shall breathe moist air. A tent can readily be improvised by means of screens roofed in by a sheet. Diffusible stimulants, such as ammonia combined with expectorants should be given, and brandy may be administered in doses of half an ounce every three hours or oftener as necessity arises. The following prescription may be used with advantage.

℞	Ammon. carbonatis,	gr. v.
	Spirit. ætheris nitrosi,	ʒss.
	Vini ipecac.,	ʒx.
	Tinct. scillæ,	ʒxv.
	Aq. Menth. pip.,	ad ʒj.
	Misce. Ft. mist.	Every four hours.

If the lung trouble increases, a large jacket poultice of linseed meal renewed every three or four hours should be substituted for the cotton wool, and when there is much cyanosis, oxygen inhalations (see Part I, p. 196) should be employed. When, however, the affection reaches this advanced

degree, the chances of recovery are very slight indeed. It is very important to get all these old people up as soon as possible, as they may be attacked by this complication at any time ; in speaking of fractures of the neck of the femur we shall refer to forms of apparatus that may be employed with this object.

(6) **Delirium tremens.**—This is a very common complication of fractures in subjects who are addicted to alcoholic excess. The attack often comes on within a few hours of the receipt of the injury, and at first manifests itself by extreme restlessness, marked loquacity and disinclination to remain in bed. This is followed by the well-known symptoms of delirium tremens, such as hallucinations of vision, muscular tremors, etc. It is noticeable that in these cases the patient constantly tries to move the fractured limb, and apparently these attempts do not cause any pain. One risk of this constant disturbance of the fracture, namely fatty embolism, has already been referred to. Non-union is also prone to occur, and of course a simple fracture may readily be made compound. As a rule the affection runs a course of three or four days and spontaneously subsides. In bad cases, however, especially in elderly people who are the subjects of habitual intemperance and in whom the kidneys are diseased, the gravity of the condition goes on steadily increasing, until the patient falls into a comatose, typhoid state, and dies unconscious.

**Treatment.**—A most essential point in the treatment is to thoroughly immobilise the limb as soon as possible, and for this purpose there is nothing so efficacious as a Croft's splint, applied as soon as the fracture is seen or as soon as the first symptoms of delirium tremens set in. In the latter case it is usually necessary to administer an anæsthetic to keep the parts at rest until the plaster has properly set. If this be done, the limb can then be fastened down to the bed, and the patient's restlessness restrained by an attendant.

The medical treatment consists essentially in supporting the strength by nutritious food, and in trying to induce sleep. The patient should be isolated and kept in a dark room ; a strong attendant should be present to restrain his attempts to get out of bed. Narcotics should be given with the view of obtaining sleep, and probably the best is chloral in doses of 25 grains by mouth or double that quantity by the rectum ; this may be repeated if necessary every three hours until it takes effect. Morphia as a rule should be avoided ; in some cases, however, in persons who are extremely restless, who do not respond to the use of chloral, and in whom the kidneys are healthy, opium given by mouth may sometimes act extremely beneficially. Every effort should be made to make the patient take as much nourishing food as possible ; this should be concentrated and highly nitrogenous, beef-tea, strong soups, milk, egg and brandy, and underdone meat or raw meat juice being administered from time to time. If the patient refuse to take nourishment properly, it must be administered either by the rectum or by the stomach tube. pre-

ferably in both ways. It is sometimes a good plan, if there be an intense craving for stimulants, to spice the food with cayenne or other condiments in order to gratify the desire for stimulation of the palate. When the case does not go on well and the pulse becomes feeble, rapid, and compressible, the administration of alcohol is called for. An ounce of brandy may be given every three or four hours; some recommend the use of port wine in doses of an ounce every hour.

(7) **Bed-sores.**—In many cases of fracture, particularly in elderly people, the prevention of bed-sores is of the highest importance. The prophylaxis and treatment of bed-sores have been already referred to in detail (see Part I., p. 66).

(8) **Necrosis.**—This is a very common complication of compound fractures in which asepsis has not been obtained, and suppuration has taken place; it results from the occurrence of periostitis and osteomyelitis. The treatment of these complications will be fully dealt with under diseases of bones (see Section II.).

(9) **Mal-union.**—By the term mal-union is meant the union of a fracture with the fragments in faulty position. There may be either shortening from overlapping of the fragments or some angular deformity. In most cases the mal-union does not give rise to any marked disability, but in others the limb may be crippled; this is most likely to be the case if the mal-union has occurred in the neighbourhood of a joint, in which case the movements of the latter may be more or less completely interfered with.

**Causes.**—Mal-union may be due to (1) imperfect reduction and coaptation of the fracture in the first instance; (2) the fracture may be put up in perfect position, but, owing to imperfect apparatus or the occurrence of spasm of the muscles, etc., deformity may subsequently recur; (3) it may result from the yielding of the callus that has formed during the consolidation of the fracture; this may be either the result of too early removal of the splints (in which case the patient bears weight upon the limb before it is strong enough), or from some constitutional condition which prevents the formation of sufficiently firm bone.

**Treatment.**—It is obvious that this mal-union is preventible in the majority of cases. When it results in interference with the usefulness of the limb, an attempt must be made to rectify the faulty position. An angular deformity detected before consolidation is complete can generally be easily remedied by splints properly adjusted along the concavity of the limb, combined with elastic pressure exerted over the seat of fracture. Care must of course be taken not to employ too great a pressure, as otherwise ulceration beneath the elastic band will occur; when the union is pretty firm, it is best to administer an anæsthetic first of all, and to bend the soft callus so as to straighten the limb before applying retentive apparatus. The exact form of apparatus employed must be devised to suit the individual case and it is impossible to lay down

definite rules upon the point. Usually the employment of an anæsthetic and forcible bending of the bone are necessary if more than a month has elapsed since the fracture ; before that, elastic pressure will probably suffice to reduce the deformity.

When complete consolidation has occurred with angular deformity, the bone must be re-fractured before it can be got into proper position ; this may be done with or without a cutting operation. In adults, when the fracture is situated about the centre of the shaft of the bone, it is sometimes possible, by means of a sufficiently powerful arrangement (such as that known as Butcher's osteoclast), to re-fracture the bone, but this method is uncertain. It is apt to cause serious bruising of the soft parts, the fracture it produces may be comminuted, and in children, especially if the fracture be near the articular end of the bone, the epiphysis may separate before the union gives way. It may be laid down as a good general rule that, whenever the union is strong enough to resist re-fracture by means of the hands alone, the fracture should be cut down upon and the union divided either by a chisel or a saw, preferably the former. In an oblique fracture with one end overlapping the other an operation of this kind is absolutely essential.

Definite rules for operations of this nature cannot be formulated, because everything depends upon the nature of the deformity and the bone affected, but the following points should be borne in mind.

(1) Every operation must be done with strict antiseptic precautions, as otherwise most disastrous results may follow.

(2) The division of the bone should be effected with as little disturbance of the parts as possible ; it can usually be best effected by means of a chisel and hammer. If done in this way, the bone need not, except in oblique fractures, where pegging is necessary, be lifted out of its bed.

(3) In oblique fractures it is generally necessary to divide all the soft tissues connected with the bone in the neighbourhood of the fracture. The great difficulty in these cases is the shrinking of the soft parts, and, after the fracture has been divided, it will be necessary to exert as much extension as possible, either by the help of an assistant or by means of pulleys, and then to cautiously divide all tight bands which interfere with the proper reduction of the fracture, taking care of course not to divide important structures, such as large vessels or nerves.

(4) In all cases, whether the fracture was originally oblique or not, it is advisable to divide the bone obliquely, so as to have a larger surface for union and less chance of displacement.

(5) In all oblique fractures, and in any case where there may be difficulty in keeping the bone ends in proper apposition, pegs, screws, or wires should be employed to fix them.

(6) Very free incisions should always be made, so that the surgeon is enabled to see exactly what he is doing, and is not hampered by want of room.

(7) The wound should be stitched up without any drainage, and a large mass of antiseptic dressing applied. The limb should be left undisturbed for several weeks; if, however, much blood oozes through at first, one dressing at most is all that need as a rule be done, and the greatest care must be taken not to disturb the fracture.

(8) It should be borne in mind that, after all these aseptic operations for mal-union or non-union, union is usually delayed, and it is seldom sufficiently firm after the ordinary period of six weeks to justify the patient in leaving off apparatus. Unless the surgeon be absolutely certain that firm union has occurred, a further period of five or six weeks should be allowed to elapse before the limb is again disturbed for examination.

(9) After union is complete, massage should be employed to increase the strength and nutrition of the muscles and to loosen any adhesions that may have occurred between them and the bone.

(10) **Non-union of fractures.**—By this is meant the want of proper consolidation between the broken ends of the bone; the term is applied to a large group of cases, in some of which there is inefficient union, while in others no attempt at repair has taken place at all:

**Pathological changes.**—The following are the most common conditions found:

(1) The union may be merely delayed; when the part is examined at the end of six or eight weeks, little or no union may be present, but as time goes on the fracture gradually consolidates. This is really a case of delayed rather than non-union, and it is important to bear in mind the fact that want of union at the end of six or eight weeks, or even three months, does not necessarily imply the establishment of an ununited fracture.

(2) The callus which forms after the accident may be normal in amount and of the usual structure, but instead of going on to ossification it may remain soft, and consolidation may not occur.

(3) The callus may become converted into fibrous tissue, so that the union between the ends of the bones consists of fibrous or ligamentous material, which varies in extent and in strength according to the position of the fracture and the condition of the patient.

(4) In some cases there is the formation of an actual false joint between the ends of the bones. The adjacent ends become firmly bound together by a strong fibrous capsule, in the interior of which there is a cavity into which the broken ends project, and this cavity may actually contain synovial fluid.

(5) Cases are met with where there is no real attempt at union whatever, and where the ends of the bone become thin, pointed, and atrophied.

**Causes.**—The causes of non-union are variable, and may be divided into local conditions interfering with union, and general constitutional states of the patient.

*Local.*—The local causes may be classified as follows—(1) Imperfect



immobilisation of the limb during repair. (2) Undue separation of the fragments, either from over-lapping or from retraction of the ends, as in fracture of the patella. (3) The presence of foreign material between the ends of the bones, such as a piece of muscle, fibrous tissue or tendon, or even, as in comminuted fractures, a piece of loose bone. (4) Imperfect blood supply to the lower fragment when the fracture is situated near the nutrient artery of the bone ; perhaps the best example of this is when there are two fractures in a long bone, the upper of which involves the nutrient artery. The upper fracture will probably unite satisfactorily, the lower may not.

*Constitutional.*—Among the constitutional causes of non-union may be mentioned: (1) Specific fevers occurring during the progress of the case ; these are especially apt to lead to non-union, if they commence about the time of the injury. (2) Alcoholism, apart from the occurrence of delirium tremens and the resulting disturbance of the fracture, may of itself distinctly retard union after fracture ; this is more likely to be the case when there are degenerative changes in the kidneys. (3) In rickets there is often abundant callus thrown out, but normal ossification does not take place and the seat of fracture remains yielding. Other causes, such as scurvy, gout, anæmia, general debility, old age, paralysis, etc., are described.

**Treatment.**—In determining the question of treatment, it is first of all necessary to be absolutely certain that the case is one of non-union and not one in which union is merely delayed. As we have already pointed out, union may sometimes be a very slow process. Hence when there is no evident cause for the occurrence of non-union, such as a piece of muscle between the ends of the bone, separation of the fragments, etc., a fracture should not be considered an ununited one until at least twelve or eighteen months have elapsed, and during that time the limb should be put up in a suitable apparatus, such as a silicate or plaster of Paris casing renewed from time to time, until it is certain that union will not occur. The patient should not be confined to bed, but may be allowed to get about upon crutches or to be wheeled about in a bath-chair so long as his movements do not interfere with the absolute immobility of the fractured bones. Massage to the limb and to the body generally, with the administration of tonics, nourishing diet, stimulants, thyroid tabloids, etc., should be employed. Massage is a very important element in the treatment. While it is being employed care should be taken not to disturb the fracture.

When it is certain that the fracture will not unite, some treatment with a view to bringing about union must be adopted : this may be both local and general.

**General.**—The general treatment consists in administering a light, easily digestible and nutritious diet, securing fresh air and good hygiene generally and adopting the appropriate medical measures for any constitutional defect such as gout, scurvy, syphilis, anæmia, etc.

**Local.**—The local treatment is essentially directed towards irritating the ends of the bones so as to lead to fresh exudation from them, and

also to remove any local cause which may be interfering with union. It is well in all cases to precede the operative measures by a course of massage and galvanism with a view to improving the circulation and the muscular tone of the limb; in some cases it will be found that during this treatment consolidation takes place.

In former times a variety of methods were employed for producing irritation at the seat of fracture. These were the introduction of a seton, which is naturally a most dangerous proceeding; rubbing the ends of the bones forcibly together with a view to tearing up the fibrous tissue and producing a raw surface—a method which we have seen in two cases followed by fatal results from fatty embolism; and the injection of various irritating substances. Of these plans the only one that we shall refer to is the last.

**Injections.**—This is sometimes efficacious when there is little separation between the fractured ends. A syringe fitted with a needle of suitable length is employed for the purpose, and the needle is introduced through the skin and thrust between the ends of the bones. From 20 to 30 minims of tincture of iodine are then injected at various points around the seat of fracture. The limb is put up in proper retentive apparatus, and in some cases it will be found that the amount of irritation thus produced is sufficient to lead to proper consolidation of the fracture.

**Operative measures.**—If this plan fails or is unsuitable, operative measures must be had recourse to. These consist essentially in cutting down on the seat of fracture, and removing all the soft material between the fractured ends along with a thin layer of bone, so as to obtain a fresh surface. When this is done, the fragments are brought into apposition and secured there.

*When there is only a single bone, e.g. the femur or the humerus, the chief steps in the procedure are as follows:*

(1) The operation must be carried out with the strictest antiseptic precautions; the skin should be thoroughly disinfected, and all the other steps described in Part I., p. 161, should be taken.

(2) The surgeon makes a free incision over the fracture at a point where he will gain the most satisfactory access to the bone. Considerable help in planning the incision may sometimes be gained by the use of skiagraphy. The incision should be a very free one, so as to enable him to see exactly what he is doing, and it should be made in the long axis of the limb. The soft parts are separated until the fracture is reached, and the region of the fracture is then exposed without at first detaching the periosteum.

(3) Then with a chisel and hammer a thin layer of bone is chiselled off each fractured surface, and the slices of bone, with the intervening fibrous tissue, are removed.

(4) If the fractured ends are overlapping, extension must be made either by an assistant or by means of pulleys, and any tense bands which interfere with the proper reduction of the fracture carefully divided, provided they do not contain structures of importance.

(5) Care should be taken when cutting the bone to do so in such a manner that, when the two refreshed surfaces are applied to one another, the limb shall be in the correct position as regards rotation. In these ununited fractures the lower fragment is very apt to be rotated in the wrong direction—generally outwards, and if the bone surfaces are cut so that, when applied to each other, the position of the lower fragment remains as before, the limb may be in a faulty position. This is a point to be very carefully attended to.

(6) After having refreshed the ends of the bone in this manner and brought them into proper position, it is well in all these cases to use some mechanical means to retain them in that position. Ununited fractures unite very slowly after operation, and, apart from the increased security from the fixation of the bony surfaces by means of wires, pegs, etc., the presence of these foreign bodies assists union by keeping up a certain amount of irritation at the seat of fracture.

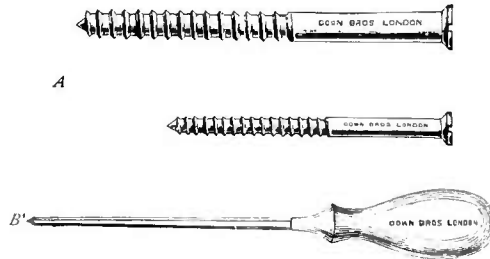


FIG. 16.—SCREWS AND DRILL FOR FIXATION OF FRACTURES.—

A shows the form of screw (natural size) recommended by Mr. Arbuthnot Lane for these operations. The screw is practically the same width throughout its whole length,—*i.e.* it does not taper at all—and has only a very small head, so that very little counter-sinking is required for its reception. These screws are first coppered and then plated with silver.

B. "Reamer" or drill for enlarging the hole in the bone to fit the shank of the screw. These drills should correspond in size to the screw used.

*Fixation methods.*—Various methods are employed for fixing the bones together. When the fracture is very oblique, the use of *screws*, as suggested by Mr. Arbuthnot Lane, answers very well, but care must be taken not to drill the screw holes too near the edge of the fracture, as otherwise the bone is apt to split when they are inserted. The bone is first bored with an awl of suitable size; it is very important to have a series of awls corresponding to the various sizes of screws, and the one selected should be a trifle smaller than the screws that are to be used. If a fine awl be used for boring for the reception of a stout screw, there will be great risk of splitting the bone. This risk of splitting is still further guarded against by broaching out that portion of the drill hole that will receive the shank of the screw by means of the "reamer" illustrated in Fig. 16. A counter-sink should also be used to provide for the reception of the head: should no such instrument be available, its place may be supplied by a small gouge. The best form of screw is that shown above (see Fig. 16): the

thread is wide, the shank long, and the head small, while the whole screw only tapers very slightly; they are first coppered, and then plated with silver. Ordinary screws can be quite safely used if they are thoroughly disinfected by boiling before use, but the screws usually met with are too large in the head and shank and taper too rapidly, and so are more likely to split the bone than those illustrated above. The size of the screws and the number inserted will, of course, vary with size of the bone operated upon.

*Ivory pegs* may also be used, but they very soon become loose and allow a certain amount of movement. This may be to some extent avoided by using pegs square in section and fitting the drill hole tightly. They are much more easily driven in than if they were round, and get a firmer hold, while the intervals left between the round hole and the square peg permit of the escape of lymph or blood. The pegs are usually made 3 inches in length, but it is well to have them quite 6 inches long, as they are then driven in by the mallet much more conveniently and with less danger of bruising the soft parts. When in position, the projecting end is cut off flush with the surface of the bone by cutting pliers.

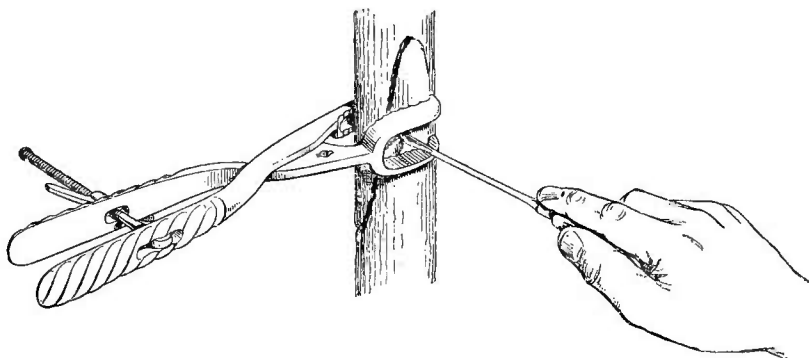


FIG. 17.—PETERS'S FORCEPS. As shown in the diagram, the fragments can be held firmly in apposition while the bone is being drilled. These forceps are provided with an extra blade which can be made to replace the one shown uppermost in the figure. The one here represented is the larger, and is employed when screws are to be used; the smaller one is designed for use when wires are to be inserted.

*Wires* are also sometimes used for oblique fractures, but they are seldom so satisfactory as the other methods just mentioned; if used, they should be inserted as follows. Two holes are bored side by side through each of the fragments; the corresponding holes in each fragment should come opposite each other, and are best made by one insertion of the drill through the entire bone, the fragments being held in exact apposition while they are drilled. A special pair of forceps for holding the fragments together during wiring or screwing is shown in Fig. 17. The end of a stout piece of wire<sup>1</sup> is then passed through the corresponding holes in each

<sup>1</sup>The size of the wire will of course vary with the bone operated upon; the sizes generally employed are Nos. 5, 6, and 7 French gauge, *i.e.* 5, 6, and 7 mm. in circumference.

fragment on one side, and then back through the corresponding holes on the other side (see Fig. 18, *A*). The loop of wire thus binds the fragments fairly firmly together. The ends are pulled tightly together, twisted, cut short and hammered down so as to lie flat on the bone. In transverse fractures the wires are not so necessary, but they are of

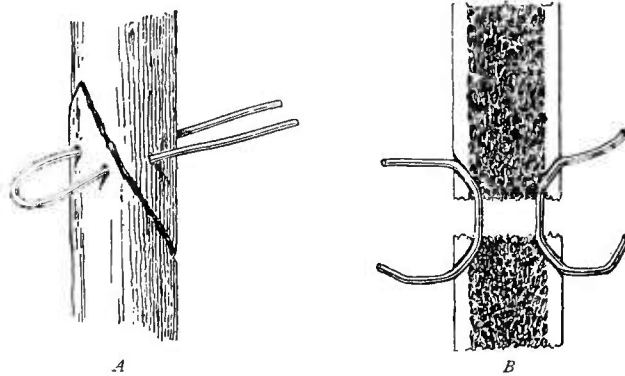


FIG. 18.—METHODS OF WIRING A LONG BONE. In *A* is shown the most efficacious plan for wiring the fragments in a case of oblique fracture. In *B* the fracture is transverse and the fragments are best kept in position by introducing wires as shown in the diagram.

advantage, because, although they do not fix the bones firmly together, they tend to prevent the sliding of the fragments upon one another, and so obviate lateral displacement. Usually it is sufficient to pass a couple of single wires through opposite sides of the bone, bringing the ends out through the medulla above and *vice versa* below (see Fig. 18, *B*), the ends being twisted, cut short and hammered down as before.

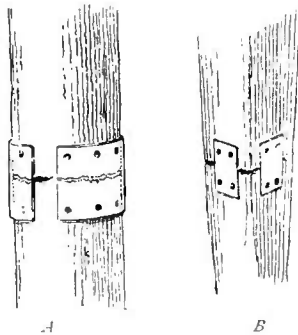


FIG. 19.—SECURING A TRANSVERSE FRACTURE BY ALUMINIUM PLATES. In *A* the cylindrical bone—the femur—is surrounded by a collar of aluminium. In the case of the tibia—shown in *B*—its place is taken by two separate plates of the same metal.

When there is great tendency to lateral displacement, a better fixation can be obtained by taking an *oblong plate of aluminium* which has holes bored in either end, applying it over the two fragments held properly in position, and then, with ordinary tintacks (previously nickeled), nailing the

plate to the two fragments (see Fig. 19, *A*). If the bone be cylindrical, a single piece of aluminium encircling about three-fourths of its circumference should be employed; otherwise it is better to use two narrow plates, one on either side of the bone (see Fig. 19, *B*). Complete fixation can be obtained by this plan, which is of great value when there is a marked tendency to rotation of the lower fragment. It is well not to detach the periosteum from the ends of the bone; no doubt there is less risk of bleeding if it be detached, but it is possible that the delay in union is to some extent increased by this detachment, and the aluminium plates can be fixed quite as firmly outside the periosteum as beneath it.

*Bone-grafting.*—When the ends of the bone are atrophied, or when there is a considerable interval between them, bone-grafts may be employed with advantage. These are best obtained from the ends of the bones themselves. Portions of the bone along with the periosteum are chipped off by a chisel and wedged in between the fragments; naturally, wiring or pegging the bones cannot be attempted here. This method of introducing bone-grafts between the fragments is sometimes extremely successful; in a case which we had not long ago, where several unsuccessful operations on the ununited fracture had been carried out, union was obtained by simply removing the soft tissue between the bones, chipping off a piece of bone from one surface and driving it like a wedge between the two fragments.

*When the non-union affects a part, such as the leg or fore-arm, in which there are two parallel bones,* care must be taken that the ends of both bones come into apposition. This is usually easy if both bones be ununited, but, when the non-union affects one bone alone, it will be found, on refreshing the fractured ends, that they do not come into proper apposition on account of the rigidity of the other bone; the best plan here is to divide the sound bone and remove enough of it to correspond with the interval left between the fragments of the one ununited. It is well also to wire each of the bones so as to prevent lateral displacement of the ends. When however the interval is very small, we would recommend the insertion of bone-grafts between the fragments, in cases where only one bone is affected, as preferable to the division of both bones, because the sound bone acts as a very efficient splint and much better fixation of the fragments is obtained than if both be divided.

*After-treatment.*—When the ends of the bone have been fixed together, the wound should be stitched up and steps taken to immobilise the limb. The best plan is first of all to incorporate in the dressing splints of block tin or wire-netting rendered aseptic by boiling and moulded round the limb so as to fix the neighbouring joints in the manner already described for compound fracture (see p. 33). Outside these splints further fixation apparatus may be employed if necessary. Unless much saturated with blood, the dressing need not be changed for about six weeks. If it be necessary to change it soon after the operation, it is well to give the patient anæsthetic and to change everything, washing the splints with a 1-20

carbolic solution or boiling them, and reapplying the apparatus before the patient is allowed to come round from the anæsthetic.

In these cases of ununited fracture complete union at the end of six weeks must not be looked for. As a rule it is necessary to keep the limb immobilised for three months or longer before thoroughly satisfactory union is obtained.

**(11) Inclusion of nerves in the callus.**—The large nerves which run in grooves along or in close proximity to the bone may be surrounded by callus which, as ossification goes on, exerts considerable pressure upon them and gives rise to pain and to a certain amount of loss of function. This may require some operative interference for its relief.

**Treatment.**—The treatment of this condition has already been referred to in dealing with affections of nerves (see Part II., p. 245).

**(12) Adhesion of muscles and tendons to the fractured ends.**—As has been pointed out already, there is considerable damage to the soft parts in the neighbourhood of fractures, and as a result there may be extensive adhesion of tendons or muscles to the bones; it is important to take measures to prevent the resulting disability of the limb where this has occurred.

**Treatment.**—The treatment of this condition has been dealt with in detail in discussing the question of massage in fractures (see p. 30).

## CHAPTER II.

### FRACTURES OF THE CLAVICLE AND SCAPULA.

#### FRACTURES OF THE CLAVICLE.

THE clavicle is more often fractured than any other bone in the body. This is of course due to the fact that the whole weight of the body is transmitted to it in falls upon the hand or elbow; it would probably be much more frequently fractured than it is but for its particular shape and its comparatively free mobility. Fracture is most common in infancy and childhood and in the male sex, but it occurs frequently at any age, and in both sexes. The fracture may occur at almost any point in the bone, but its usual situation is at the junction of the two curves near the centre of the bone, and, far less frequently, at the acromial or the sternal extremity. All these fractures may be due either to direct or indirect violence; they may be simple, compound, greenstick or comminuted.

**DISPLACEMENT.**—**In the ordinary form.**—In the common fracture at the junction of the two curves—which is generally due to indirect violence—there is a characteristic displacement of the fragments. The shoulder, and with it the outer fragment, is depressed, rotated forwards and drawn inwards towards the middle line. The inner fragment retains more or less completely its normal position, as it is held by the unbroken rhomboid ligament. In some cases it is said to be drawn slightly upwards from the pull of the sterno-mastoid muscle; this is however very doubtful.

**In fracture of the acromial end.**—In fractures between the conoid and trapezoid ligaments there may or may not be displacement from the first. In any case the displacement downwards and inwards characteristic of the ordinary fracture is absent; the only one that occurs is rotation forwards of the shoulder, which may be some days before it becomes very marked. This point is important to remember, because, owing to the absence of displacement, the accident may at first be overlooked, and the diagnosis may not be made until deformity becomes evident.

**In fracture of the sternal end.**—When the fracture is internal to the



rhomboid ligament there is little or no displacement, but there is a slight projection forward of the inner fragment which practically consists of the articular portion of the sternal end of the clavicle.

**COMPLICATIONS.**—Complications are rare and usually only occur when the fracture results from very severe violence. The most frequent is injury to or *pressure upon the brachial plexus*, leading to severe neuralgia of the upper extremity and, in bad cases, to actual paralysis. Paralysis due to this cause is present before the fracture is reduced; when it occurs after reduction it is generally due to an unduly large pad in the axilla exerting pressure upon the nerves there. When the fractured ends are much comminuted from severe direct violence, there may be a *wound of the subclavian artery*, which may lead to immediate death from hæmorrhage, to the occurrence of a large hæmatoma, or to the formation of a false aneurysm. True aneurysm has also followed a fracture of the clavicle as a result of bruising of the coats of the artery. *Wounds of the pleura and even of the lung* have also been described in connection with these fractures, but they are of great rarity and generally occur when there is also fracture of the first rib.

**TREATMENT.**—**Of the ordinary form.**—Bearing in mind the triple deformity in fracture of the clavicle in the common situation, the treatment must be directed towards correcting it, that is to say, the outer fragment must be carried outwards, upwards and backwards. As a rule the results of treatment are by no means perfect as regards appearance, but the fracture always unites quite readily and the functional result is almost invariably good.

*Recumbency.*—In the case of ladies, to whom the question of evening dress is important, it may be very desirable to avoid any deformity at all; this can be done by placing the patient in bed in the absolutely recumbent position on a hard flat mattress with a small narrow hard pillow or pad between the shoulder blades and another supporting the head only. The width of the pillow beneath the spine must be such that the edges of the scapulæ do not rest upon it; the weight of the shoulder thus carries the outer fragment backwards much more completely than could be done in any other way. A small pad should also be placed in the axilla, and the elbow raised and fastened at the side. This position must be kept up for two to three weeks; it is naturally very irksome, and few patients will submit to it. In some cases however it may be imperative, as for example when both clavicles are fractured, and there is therefore no sound shoulder from which to support the elbow on the affected side.

*The Handkerchief method.*—Probably the next best method of avoiding deformity is the old plan of pulling back the shoulders by means of handkerchiefs. Two handkerchiefs are taken and folded to the centre until each is about three inches wide. In order to avoid the possibility of chafing, it is well to fold them over a roll of cotton wool which should be about a foot long and should occupy the centre of the handkerchief: in fact the

handkerchiefs are prepared much in the same way as for a perineal band. The handkerchiefs thus prepared are fastened loosely around each shoulder, passing beneath the axilla and over the point of the shoulder, and care is taken that they do not encroach upon the seat of fracture. The ends of the handkerchiefs are then tied firmly together between the scapulæ; in this way the shoulders can be pulled back to any degree required. The axilla should be shaved or the hair cut quite short, and then powdered thickly over with boracic powder, and a pad of moderate size placed in it; the arm is supported by a large handkerchief sling which raises and pushes forward the elbow



FIG. 20.—THE HANDKERCHIEF METHOD FOR TREATING FRACTURED CLAVICLE. The shoulders are well pulled back by the handkerchiefs looped around them (compare also Fig. 21), a pad is placed in the axilla and the arm is supported by a large elbow sling—tied over the sound shoulder. The forearm is sometimes carried obliquely up across the front of the chest until the band rests on the anterior fold of the opposite axilla; this can be done by pinning the sling suitably. The apparatus is completed by the handkerchief encircling the thorax and binding the arm to the side.

and is fastened round the neck. A third handkerchief, binding the arm to the side and passing around the trunk just above the level of the elbow, completes the apparatus (see Fig. 20). Extremely satisfactory results are obtained with this arrangement, but it is rather irksome because of the pressure of the knot in the middle of the back; this may be remedied to some extent by sewing the ends of the handkerchiefs together instead of knotting them. The most satisfactory method is that illustrated in Fig. 21. Here the shoulder loops are buckled together, and the tension can be

varied at will. On the whole we decidedly recommend this method for use in adults in preference to all others. The sling supporting the elbow should pass over the sound shoulder only, and should not press anywhere on the region of the fracture.

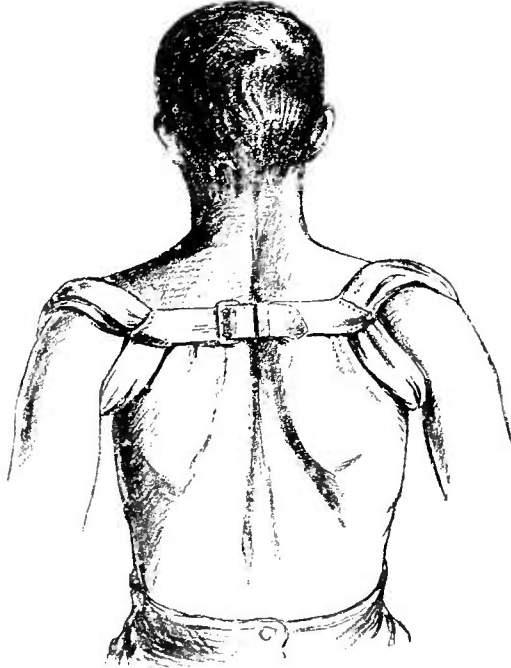


FIG. 21.—APPARATUS FOR PULLING BACK THE SHOULDERS IN FRACTURED CLAVICLE. This is merely a more convenient method of applying the loops around the shoulders described in the text and illustrated in the preceding figure. The loops are made by encasing wool in several folds of muslin, and the requisite amount of retraction of the shoulders is easily regulated by the strap and buckle connecting them. This apparatus is more easily altered and gives rise to less chance of pressure than the ordinary knotted handkerchiefs.

*Sayre's method.*—The method most commonly employed in fracture of the clavicle is that known as Sayre's. When the patient is an adult, the arm and chest should first be carefully shaved, and the hair in the axilla cut short and powdered with boracic powder. A strip of adhesive plaster, three inches broad for an adult, and two inches for children, is looped around the arm about its centre, with the non-adhesive side next the skin, and the ends of the loop pinned to prevent it slipping. If the strapping be merely wound round the arm constriction will occur when it is pulled on and will cause trouble; the loop must be wide enough to allow three fingers to be inserted between the strapping and the skin of the back of the arm. A pad of salicylic wool is then placed in the axilla and the arm is pulled back as far as possible by traction on the strip of plaster (see Fig. 22). In Sayre's original method no pad was inserted in the axilla, but this is a defect, as it leaves the inward displacement uncorrected. When the arm

has been pulled back as far as possible, the free end of the strapping looped around the arm is carried horizontally across the back of the chest and brought round beneath the opposite axilla across the front, so as to completely encircle the thorax, and is finally pinned to itself just beyond

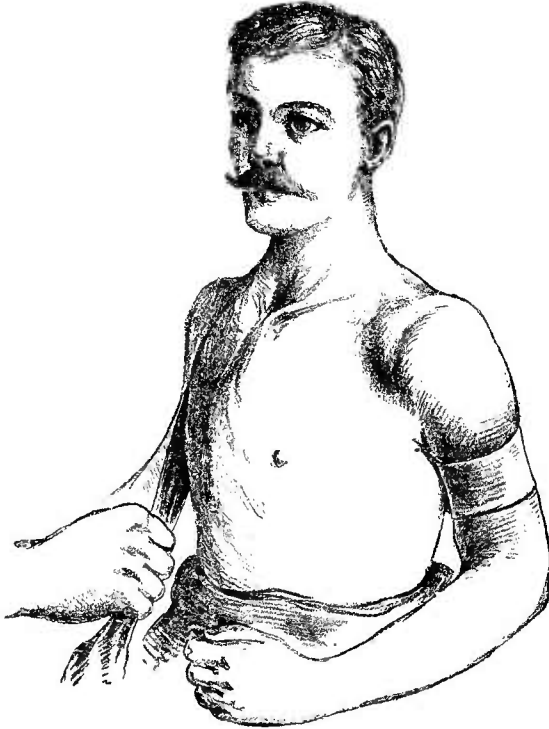


FIG. 22.—SAVRE'S APPARATUS FOR FRACTURED CLAVICLE. *Applying the arm loop.* The arm is pulled forcibly backwards by traction upon the strapping, which is afterwards fastened as shown in the following figure.

the loop around the arm. The strapping thus applied acts as a fulcrum, so that, when the elbow is pushed forwards, the shoulder with the outer fragment of the clavicle is carried backwards. This is done by an assistant, who also flexes the elbow, carrying it forwards and upwards until the fingers nearly reach the opposite shoulder, while the forearm lies across the front of the chest (see Fig. 23).

A second strip of strapping is next carried over the sound shoulder obliquely downwards across the back to the point of the elbow, where it is split for an inch or so for the reception of the olecranon; thence it is carried up to its starting-point over the sound shoulder, and the two ends are pinned or sewn together (see Fig. 24). This completes the apparatus, but it is advisable in addition to apply a bandage over all and, if the apparatus is to be left undisturbed for some time, it is well to sew the

adjacent edges of the bandage together and to rub a little starch solution into it, so as to make it firm and prevent it from slipping.

This apparatus should be kept on for about three weeks; should it become loose in the interval it must of course be renewed. At the end of three weeks it may be left off and the arm carried in a large elbow-sling for another week or ten days. Union takes place very rapidly, and an ununited fracture of the clavicle is of very rare occurrence.

Other forms of apparatus have been devised for this fracture, but the methods above described are on the whole the best.

**Of fracture of the acromial end.**—When the fracture occurs in the neighbourhood of the conoid and trapezoid ligaments, either the handkerchief arrangement or Sayre's apparatus should be applied, even though no deformity exists when the patient is first seen; this is necessary to prevent the tip of the shoulder rotating forward at a later period.

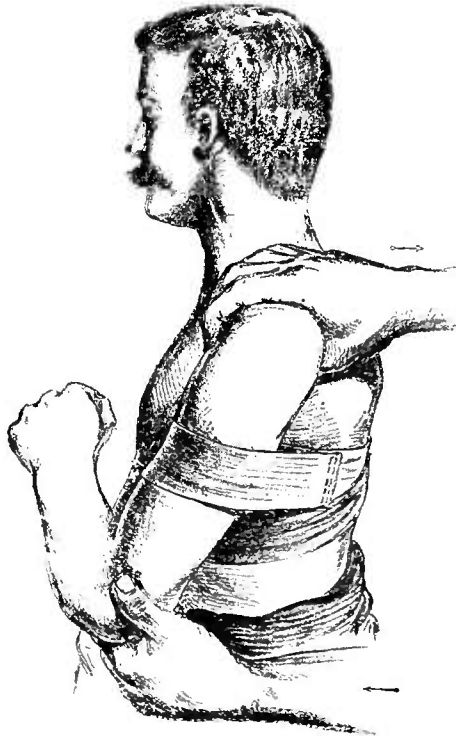

FIG. 23.—SAYRE'S APPARATUS FOR FRACTURED CLAVICLE. *Pushing forward the elbow and pulling back the shoulder.* The arm loop acts as a fulcrum. The arrows show the direction in which the hands exert pressure.

**Of fracture at the sternal end.**—When the fracture is at the sternal end, the treatment largely depends upon whether there is any deformity and whether there is any other fracture present. Usually there are other injuries, so that the patient is confined to bed; it then suffices to keep

him lying on his back with a pad between the scapulæ. When there are no other injuries, Sayre's method is the most suitable.

**Green-stick fracture.**—Green-stick fractures should be treated in the same manner as the complete varieties, and special care must be taken to reduce the deformity properly. This is best done by seizing and carrying back the shoulder firmly with one hand and pressing on the projection with the other until the deformity has entirely disappeared.

**Compound fracture.**—If the fracture of the clavicle be compound the case must be treated by the methods ordinarily employed for compound fracture (see p. 31). The wound and, if necessary, the ends of

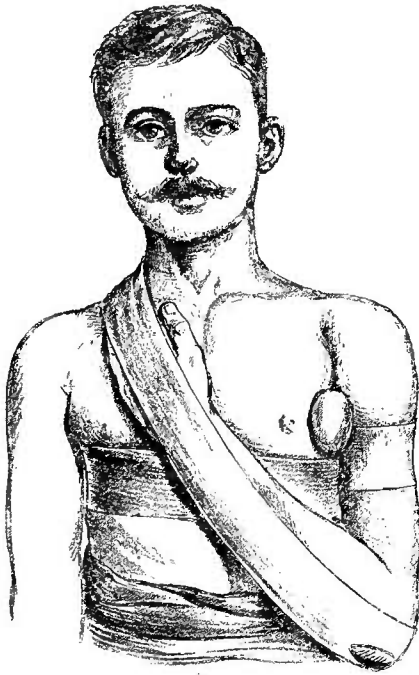

FIG. 24.—SAYRE'S APPARATUS FOR FRACTURED CLAVICLE. *Supporting the elbow.* The apparatus is now complete except for a bandage over all. The hand need not necessarily be included as shown in the figure.

the bone are thoroughly purified, and, in addition to this, the fractured ends should be drilled and secured together by silver wire. The wound is then stitched up, a drainage tube introduced, for fear that complete asepsis has not been secured, and suitable dressings applied. The patient should be laid upon his back with a narrow pillow along the spine, and the bandages should be so arranged as to pull the shoulders well back, while at the same time the elbow is supported; good union usually takes place. It must however be borne in mind that union in compound fractures is not so rapid as in those that are simple, and the apparatus should be kept on for at least six weeks.

## FRACTURES OF THE SCAPULA.

**VARIETIES.**—Fracture of the scapula may be met with in four situations, namely, the body, the neck, the acromion or the coracoid process.

**Fracture of the body.**—The body of the scapula is very rarely fractured, owing no doubt to its extreme mobility and to the protection afforded by the muscles over it. When it does occur it is generally due to direct violence, such as a severe blow upon the back in buffer accidents and the like. It is very commonly complicated by other fractures in the vicinity, such as fracture of the ribs beneath. Fractures of the body of the scapula are not uncommonly comminuted and they occur more frequently in the infra-spinous than in the supra-spinous fossa.

**Fracture of the surgical neck.**—This form of fracture is generally produced by a fall upon the out-stretched hand, but is sometimes due to a fall directly upon the point of the shoulder.

**Fracture of the acromion.**—Here the cause is generally direct violence, such as a fall or a downward blow upon the point of the shoulder.

**Fracture of the coracoid process.**—The coracoid process is also sometimes detached, but, as it is deeply seated and well protected, this is usually merely an accompaniment of other injuries, such as fracture of the clavicle or the upper ribs, or dislocation of the humerus, and is due to direct injury.

**SYMPTOMS.**—**Fracture of the body of the scapula** is characterised by extreme pain, and inability to move the shoulder. There is also generally considerable swelling, and crepitus is sometimes felt when the hand is placed over the shoulder and the arm freely moved. **In fracture of the acromion process** there is inability to raise the arm from the side and the shoulder presents a slightly flattened appearance. The fractured portion is pulled downwards chiefly by the deltoid muscle. **In fracture of the coracoid process** the detached fragment is often drawn downwards and inwards by the three muscles attached to it; but in some cases where the ligaments between the coracoid process and the clavicle remain intact, little or no deformity is met with. **Fracture of the neck of the scapula** is one of the injuries which has to be distinguished from dislocation of the shoulder. It is generally accompanied by some flattening of the shoulder, but the arm is lengthened instead of being shortened. The contour of the shoulder is readily restored by pushing up the elbow, and crepitus generally occurs at the same time; as soon as the elbow is again allowed to hang, the deformity is reproduced. When the fracture runs through the surgical neck, the coracoid process also descends with the arm. In some cases, but extremely rarely, fracture takes place through the anatomical neck of the scapula and the coracoid process remains connected with the rest of the bone.

**TREATMENT.**—In fractures of the body of the scapula the important point is to keep the bone at rest until union has taken place. With this object the elbow, supported by an assistant, is held slightly away from the side, and a thick layer of cotton wool is applied over the back of the scapula and firmly secured in position by a firm broad bandage or by strips of strapping applied around the side of the thorax, so as to bind the bone to the chest wall. After powdering the axilla with boracic powder, the fore-arm is put in a sling which supports the elbow, the arm is brought to the side, a ring-pad inserted between the internal condyle of the humerus and the ribs, and the arm bandaged firmly to the chest. Some starch solution is then rubbed into the bandages to prevent them from slipping.

This apparatus should be kept on until the end of the third week, when the patient may be encouraged to move the arm freely.

**Fracture of the acromion process** is a much more difficult matter to treat. The ideal treatment, no doubt, is to place the patient in bed in the horizontal position, with the arm stretched out at right angles to the side of the chest, so as to fully relax the deltoid, and thus to prevent it from pulling the fragment downwards. But this position is most irksome, and will hardly ever be tolerated; the best alternative is to push up the head of the humerus against the under surface of the acromion, and to fix it there, with the object of keeping the fragment as nearly as possible in its normal position. No pad should be inserted in the axilla, as otherwise the head of the humerus will not act properly on the acromion; a small pad should be placed between the internal condyle and the ribs, and the fore-arm should be flexed across the chest. Then both the arm and the fore-arm are firmly bound to the side by a bandage or by strapping. It is well to keep the arm in this position for a month at least, but in many cases a certain amount of deformity persists, the point of the acromion being somewhat tilted downwards. This, however, gives rise to no real disability.

**Fracture of the neck of the scapula** is readily reduced by pushing up the elbow, which should be kept in that position until union occurs. The axilla should be powdered and a pad placed in it; the arm is then supported by a large elbow-sling and is bound to the side by a handkerchief or bandages. If bandages be employed, they should not only encircle the chest and arm, but should also pass diagonally below the elbow on the affected side and over the opposite shoulder, so as to give additional support to the arm. This apparatus must be kept on for at least four or five weeks; if removed earlier, the deformity is almost certain to recur. As, however, stiffness of the shoulder joint is very liable to result from the presence of adhesions within the capsule, it will be necessary after the lapse of about a week to commence passive motion, taking care to fix the fragment with one hand in the axilla while the arm is moved by the other or by an assistant. This passive movement should at first be very gentle



and moderate in range, and it should be repeated daily for the first week, after which time it may be employed more frequently and more freely. In the intervals the arm should be kept in the sling or apparatus above described, which should not be wholly discarded for about five weeks.

**Fracture of the coracoid process**, if accompanied by comparatively slight displacement, is best treated by carrying the elbow as far forwards and upwards as possible, so as to relax the pull of the muscles upon it. The position of the arm is practically that employed in cases of fracture of the clavicle. The arm should be firmly bound to the side and the elbow supported. If, however, there be very considerable displacement, and no contra-indication to operation exists, the best plan will be to cut down over the anterior edge of the deltoid, expose the coracoid process and wire it to the scapula. This fracture, however, is extremely rare, and is often complicated with other severe injuries, so that this operation would seldom be called for.

## CHAPTER III.

### FRACTURES OF THE HUMERUS.

FRACTURES of this bone are usually divided into those affecting the upper end, the shaft, and the lower extremity. This classification will be followed here.

#### FRACTURES OF THE UPPER END OF THE HUMERUS.

**VARIETIES.**—These comprise fracture of the surgical neck, fracture of the anatomical neck, separation of the upper epiphysis, and separation of the great tuberosity. Fractures of the upper end of the humerus may result from direct or indirect violence. Most commonly the fractures of the surgical neck are produced by indirect violence, such as falls upon the hand or elbow, while the other fractures generally result from direct violence.

**Fracture of the surgical neck.**—This fracture is the most important and most frequent of the various injuries. It may result from either direct or indirect violence, in the former case from a fall upon the shoulder, in the latter from a fall upon the outstretched hand or elbow. The line of fracture is usually transverse, and the fractured ends are not always separated from one another; in some cases impaction of the lower fragment into the upper takes place. The displacement that occurs depends largely upon whether or not the fragments are entirely disentangled. When separation of the fragments is complete, the following are the chief displacements. Opinions seem to differ considerably as to the displacement of the upper fragment, some holding that it is but slightly altered in position, whilst others assert that it is abducted and rotated outwards by the muscles inserted into the great tuberosity. The tendency to rotation outwards is however counterbalanced to a considerable extent by the pull of the subscapularis, and the probability is that, unless the bone be displaced by the violence producing the fracture, it remains much in its normal position. The lower fragment is drawn upwards either in front of or

behind the upper fragment. In the large majority of cases it passes up in front, and is felt below the coracoid process, forming a projection beneath the anterior fold of the axilla. Below the projection formed by the lower end of the upper fragment there is a depression corresponding to the insertion of the deltoid, and the elbow is directed somewhat away from the side. This accident is sometimes complicated with dislocation of the head of the bone; it is probable that the dislocation occurs first and that the fracture takes place subsequently.

**Fracture of the anatomical neck.**—This is an injury of some rarity; it is more frequently met with in old people and corresponds in them to fracture of the neck of the femur. The line of fracture follows more or less completely that of the anatomical neck of the humerus and is therefore wholly or mainly within the capsule. The injury usually results from severe direct violence, such as falls or blows upon the point of the shoulder, and the resulting deformity is comparatively slight. The head of the bone not uncommonly remains connected with the tuberosity by bands of untorn periosteum. Sometimes, however, it is completely separated and may be actually completely rotated, so that its cartilaginous surface is in contact with the fractured end of the lower fragment, in which case of course there is no prospect of union. The shoulder is slightly flattened. The lower fragment is drawn somewhat upwards under the acromion, and the head of the bone may be driven into the tuberosity.

**Separation of the upper epiphysis.**—This occurs in young subjects before the age of 20, and corresponds very closely in its characters to fracture of the surgical neck.

**Separation of the great tuberosity.**—As the result of severe violence the great tuberosity may sometimes be detached without any loss of continuity in the shaft of the bone. There is then considerable broadening of the shoulder, the fragment being drawn upwards and backwards by the muscles attached to it.

**TREATMENT.—Of fracture of the surgical neck.**—The treatment employed for fracture of the surgical neck of the humerus (which is the most common form of fracture in this situation) is in the main the one most suitable for the other fractures about the upper end of the bone.

**Reduction.**—It is necessary in the first place to reduce the fracture carefully, and, in order to accomplish this satisfactorily, the patient should be put under an anæsthetic. The scapula and shoulder are fixed by an assistant whilst the surgeon proceeds to reduce the fracture by making sufficient extension to bring the lower fragment down to its proper position; the latter is then manipulated outwards and backwards by the left hand in the axilla, until it has been brought accurately into line with the upper fragment, the extension being meanwhile steadily maintained. When the line of fracture is transverse, there is no great tendency to a recurrence of the displacement after reduction has been properly effected: when

however the fracture is oblique, displacement is likely to recur, and the limb requires very careful immobilisation.

**Retentive apparatus.**—Various measures may be employed to retain the fragments in position after the fracture has been properly reduced. If the fracture be transverse, a very simple arrangement will suffice. A pad should be placed in the axilla (which is dusted with boracic powder) and kept in position by means of a handkerchief or broad bandage applied



FIG. 25.—METHOD OF SECURING A PAD IN THE AXILLA. A piece of bandage is fastened to each end of the axillary pad and these are made to form a figure-of-eight as shown above.

as in Fig. 25; this will prevent displacement inwards of the lower fragment. The elbow is then flexed, and the arm brought to the side, with its long axis parallel to that of the body. A large triangular bandage is taken and its base is fastened horizontally around the arm and trunk just above the elbow, while its apex hangs downwards. The latter is then turned up around the fore-arm and the point of the elbow, between the limb and the chest, turned over and pinned to the base of the handkerchief which surrounds the trunk (see Fig. 26). The wrist is supported by a narrow sling.

In this form of fracture there is no need for any special extension apparatus. For greater safety however it is also well to put on a shoulder-cap, which may be made as follows. A large sheet of brown paper of suitable size is taken and applied to the sound shoulder, and from it is cut a pattern for the shoulder-cap (see Fig. 27, *A*). This should extend from the root of the neck above to within an inch or two of the elbow joint below, and

at the front and back above should extend well over the pectoral and scapular regions. Lower down it should encircle from half to two-thirds of the circumference of the arm (see Fig. 27, *B*). When the pattern has been cut, it is laid upon a sheet of guttapercha, poroplastic or leather of suitable size, which is cut to it. The splint is then softened; if guttapercha, it is immersed in hot water, or if poroplastic, it is warmed before a hot fire or steamed in a steriliser; if leather it is immersed in vinegar. Poroplastic is on the whole perhaps the most manageable and most comfortable material. Whilst the splint is still soft it is applied to the injured side and rapidly fitted, moulded and bandaged in position. If guttapercha or poroplastic be used, care must be taken not to apply it direct to the skin for fear of causing burning. It is well to first envelop the part in a layer of cotton wool or, if that be not at hand, an ordinary folded bath-towel.




FIG. 26.—BANDAGES APPLIED IN TRANSVERSE FRACTURE OF THE UPPER END OF THE HUMERUS. The left-hand figure shows how the triangular bandage is applied horizontally around the thorax after the fracture has been reduced and a pad placed in the axilla. The other figure shows the apparatus completed. The point of the triangular bandage is turned up around the fore-arm, between it and the chest, and turned over and pinned, as shown above. A narrow wrist-sling is then put on, with a shoulder-cap over all.

When the splint is properly moulded and before it becomes quite hard, it should be removed from the limb, and a number of holes punched in it to allow for the escape of perspiration: these need only be punched in

leather or guttapercha splints; poroplastic is sufficiently porous without them. Care should be taken to punch these holes from the inner surface, as if done in the reverse direction the points of the punctures will irritate the skin. After the splint has thoroughly hardened, it is padded and fixed to the shoulder by tapes attached to the upper part and passed under the opposite axilla; it is fastened around the arm by straps and buckles. A bandage may then be applied around the shoulder over all.

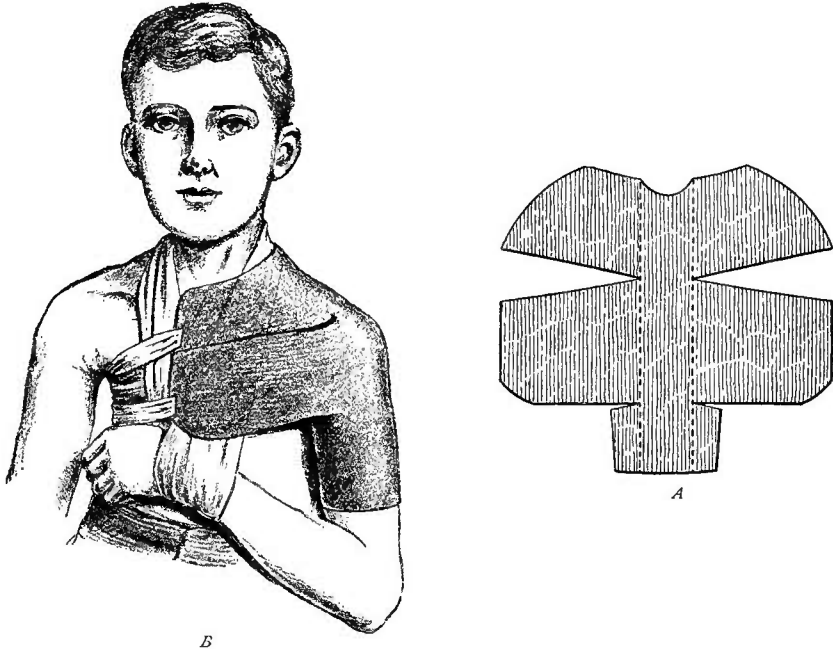


FIG. 27.—SHOULDER-CAP FOR USE IN FRACTURES OF THE HUMERUS. *A* shows roughly a simple pattern suitable for a shoulder-cap. The arrangement is shown applied in *B*. The wrist-sling is placed beneath the shoulder-cap in order to obtain better fixation of the wrist. The splint is secured around the arm by a strap or bandage not shown in the figure.

*After-treatment.*—The apparatus should be kept on for at least a week without being disturbed, unless it causes pain from pressure, or unless it shifts its position. At the end of a week it may be taken down, the axilla and arm washed, and gentle passive movements made. In doing this, one hand in the axilla should grasp the region of the fracture while an assistant should steady the scapula. The fracture should then be put up again, and the apparatus ought not to be discontinued until about five weeks have elapsed. During the progress of the case the splint should be taken off at first once a week, but after the lapse of three weeks it should be removed daily for passive movement.

**Extension apparatus.**—When the fracture does not keep in place satisfactorily after reduction, as may be the case when there is considerable obliquity or much comminution of the fragments, some arrangement must

be made to provide for suitable extension. This is generally done by inserting a pad in the axilla, fixing on a shoulder-cap as before, and supporting the wrist and hand by a narrow wrist-sling. The elbow is left free, in order that the weight of the limb may to some extent act as an extending force. This method of producing extension is not however entirely satisfactory; the bands which fasten on the shoulder-cap prevent the weight of the limb from really acting to any considerable extent upon the fracture, and if there be much over-riding of the fragments, some more efficient extension must be employed. The importance of this will be readily understood if the great disability which follows fractures that are not kept in good position be borne in mind. For the first few days therefore, if the patient will assent to it, he should be kept in bed, and a pulley extension apparatus applied to the upper arm, taking purchase just above the elbow. The arm should be kept somewhat away from the side, and the cord to which the weight is attached should pass over a pulley at

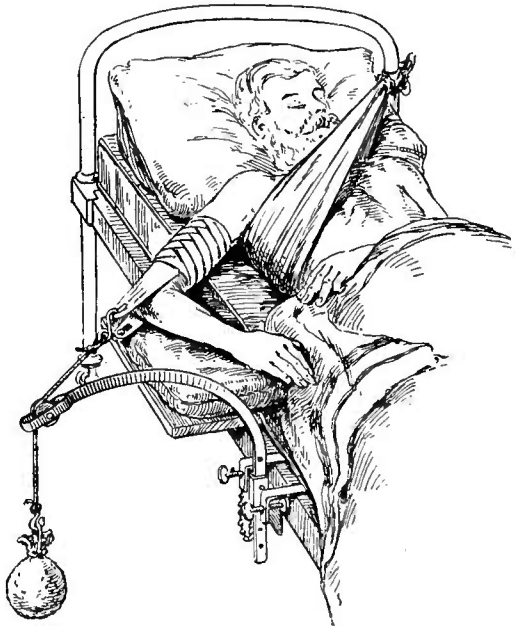

FIG. 28.—WEIGHT EXTENSION IN FRACTURE OF THE UPPER END OF THE HUMERUS. *Extension applied while the patient is in bed.* This shows a simple method of applying extension. The pulley-arm is attached to the side of the bed and extension is made with the arm somewhat abducted. The counter-extension is made from the end of the bed in a line parallel with that of the extension; a large sling or a jack-towel is used for this purpose, and fixes the scapula and thorax.

the side of the bed; a weight of three or four pounds will generally be sufficient. Counter-extension is made by passing a well-padded sling round the axilla, and fastening the ends to the head of the bed (see Fig. 28).

At the end of the first week the patient may be allowed to get up, wearing a shoulder-cap; during the day, extension is made from the elbow

by means of a weight of about three pounds, the hand being kept in a sling (see Fig. 29). At night the pulley extension is replaced. At the end of the third week the weight extension may be left off entirely, but the shoulder-cap should be kept on until five weeks have elapsed since the fracture.



FIG. 29.—WEIGHT EXTENSION IN FRACTURE OF THE UPPER END OF THE HUMERUS. *Extension applied while the patient is up.* The weight is attached to the stirrup and a shoulder-cap and wrist-sling are put on. At night the two latter can be taken off and the extension applied as in the preceding figure.

**Mechanical fixation of fragments.**—If in spite of these measures the displacement recurs, there need be no hesitation in cutting down upon and fixing the fragments in proper position. This will be more especially called for in the rarer cases in which the fracture runs obliquely upwards through the tuberosities. A skiagram should be taken two or three days after the injury, without removing the splints, and if much over-riding be found, operative interference should be resorted to. For this purpose an incision is made along the anterior border of the deltoid, curving outwards and backwards below; the muscle is firmly retracted, and its insertion may be partially detached to allow of proper access to the fracture. The fractured ends are then brought into position by means of extension carried out by an assistant. The ends of the bone are next fixed by a couple of pegs, or, still better, by two fine plated screws (see p. 51). The flap containing the deltoid is then replaced, and the divided portion of the muscle united by a few catgut sutures (see Part II., p. 199). A large dressing is applied, and the limb put up again in the shoulder-cap and fixed to the side in the manner described above.

**Of fracture of the anatomical neck.**—Here good union is hardly to be expected, and the chances of its occurrence are not sufficiently good



to encourage the surgeon to run the risk of getting a stiff joint. Therefore, the chief attention should be given to passive movement from a comparatively early period. The retentive apparatus in these cases will be very much the same as that described for fracture of the surgical neck (see p. 67), except that it is hardly necessary to use an axillary pad; if there be much tendency to inward displacement, a small one may, however, be called for. The elbow should not be supported, only a narrow wrist-sling being employed. The shoulder-cap should be used and the arm should not be fastened to the side. When the head of the bone is loose in the glenoid cavity—a condition that a skiagram will make evident—and where it is therefore certain that no union will take place, the best treatment is no doubt to cut down and remove the head of the bone. A freely movable joint may be thus obtained, and a much better result is insured than if the case were treated without operation.

**Of separation of the great tuberosity.**—In this fracture the continuity of the head of the bone with the shaft is, of course, unimpaired. The fragment is seldom completely detached, and is often held fairly well in position by untorn bands of periosteum. The position most favourable for good union is to carry the arm out from the side nearly to a right angle, and to rotate it well outwards; and this is the position frequently recommended. A wedge-shaped pad, the upper angle of which is a right angle, or a well-padded splint of a similar shape, is placed in the axilla with its apex upwards in order to keep the arm in this position; a thick flat pad is placed over the great tuberosity, and the whole fixed in position by a bandage. This position is a most irksome one, and as there may also be difficulty in getting the fragment into position, the only really satisfactory method of treatment is to turn up a flap containing the deltoid—which is divided near its insertion into the bone—and by means of screws or pegs to fix the detached tuberosity in its place. This form of injury is however very rare, and the force which produces the fracture is generally so severe that other injuries in the vicinity are likely to be present and may therefore modify the treatment.

**Of separation of the upper epiphysis.**—This injury resembles fracture of the surgical neck so closely both in its appearance and its treatment that what has already been said with regard to the one may be taken as applying in all respects to the other. This particular injury of course possesses an added gravity in that there may be an arrest of development in the humerus as a result of the damage to the epiphyseal line, and, as a considerable proportion of the growth in the bone takes place at the upper epiphysis, this arrest of development may lead to very considerable shortening.

**COMBINED FRACTURE AND DISLOCATION.**—Before leaving these fractures about the upper end of the humerus, it will be well to refer to cases occasionally met with, in which dislocation of the shoulder is combined with fracture of the surgical neck of the humerus.

**Treatment.**—The general rule of treatment up to the present time has been that if the head of the bone cannot readily be got into position by manipulation under an anæsthetic with the hand in the axilla, the fracture should be put up with the lower fragment in a line with the displaced head and upper fragment, and that when consolidation has occurred, a second attempt should be made to reduce the dislocation. But, as will be seen when we speak of dislocation of the shoulder joint, it is a matter of common experience that it is not only difficult but very dangerous to reduce a dislocation after the lapse of even a few weeks from the injury. Certainly, by the time that the fracture has united firmly enough to permit of sufficient force being applied to reduce the dislocation, reduction would be impossible, on account of the changes that have taken place in the capsule and the adhesions that have occurred between the head of the bone and the surrounding structures. Hence it is far better practice to cut down, replace the head of the bone at once and suture the rent in the capsule, and then to secure the fractured ends together. The steps of the operation for reduction of the dislocation will be described when we discuss dislocations (see Part IV.).

#### FRACTURES OF THE SHAFT OF THE HUMERUS.

**CAUSES.**—The shaft of the humerus is most commonly broken just below the insertion of the deltoid, but fracture may occur at any part; it may be due either to direct or indirect violence. The most common cause is a direct blow upon the arm, but the fracture may also result from falls on the hand or elbow.

**DISPLACEMENT.**—The displacement varies according to the obliquity and situation of the fracture and the nature of the force producing it. If the bone be broken just above the insertion of the deltoid, the upper fragment is usually drawn inwards and forwards by the pectoral and other muscles, whilst the lower is pulled upwards and outwards, and the elbow is directed away from the side, so that there is a marked depression just above the insertion of the deltoid. When the fracture takes place below the insertion of the deltoid the upper fragment is usually abducted and somewhat rotated outwards, whilst the lower fragment is drawn upwards to the inner side of the upper.

**COMPLICATIONS.**—These fractures are usually unaccompanied by any complication, but sometimes the musculo-spiral nerve may be injured. This may occur at the time of the fracture from direct injury to the nerve as it lies in the musculo-spiral groove, but it more commonly becomes involved subsequently in the callus; the result of the pressure thus exerted upon the nerve is paralysis of the extensors of the hand. Fortunately, however, this is not of common occurrence.

**TREATMENT.**—These fractures demand special care because there is a marked tendency to the occurrence of ununited fracture in this

situation. Probably the chief cause of this is neglect to properly fix the elbow joint after reducing the fracture. It is well to employ an anæsthetic, both to overcome the muscular contraction and to enable the surgeon to apply the splints properly. The bone at the seat of fracture should be surrounded by four splints—an internal straight one reaching from the axilla to just above the internal condyle; anterior and posterior ones, also straight, extending the whole length of the arm; and a shoulder-cap which is prolonged below into an external angular splint reaching as far down as the lower third of the fore-arm. The short splints should together be about two-thirds of the diameter of the limb in width, should

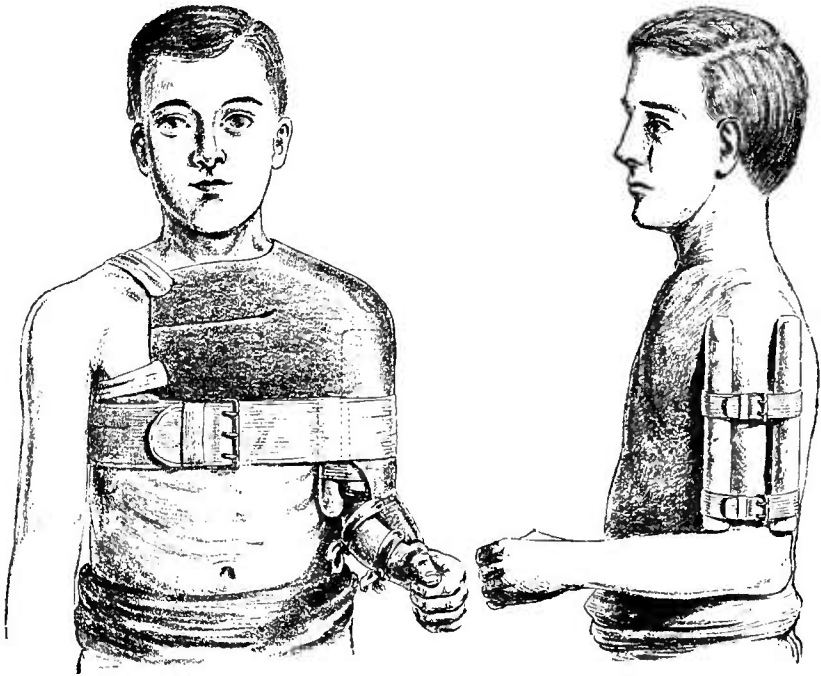


FIG. 30.—APPARATUS FOR FRACTURES OF THE SHAFT OF THE HUMERUS. In the right-hand figure is seen the first stage; anterior, posterior, and internal straight splints are applied. In the left-hand figure a shoulder-cap, prolonged downwards into an external angular splint, has been put on over these. The forearm is shown with its long axis parallel to the antero-posterior plane of the body. The apparatus is completed by a wrist-sling.

be well padded, and should be fixed around the arm with two or three straps and buckles. The elbow is flexed to right angle, and the fore-arm is put up in a position midway between pronation and supination. The hand should be supported in a sling, and the arm fastened to the side by a handkerchief or broad bandage (see Fig. 30). It is necessary that the arm should hang vertically at the side with the long axis of the fore-arm parallel to the antero-posterior diameter of the trunk; if the fore-arm be brought at all forwards across the chest, rotation of the lower fragment upon its vertical axis is apt to take place.

The splints should be kept on for about four or five weeks because of the liability to non-union already mentioned, but they should be removed daily after the first fortnight, so as to carry out passive movements of the elbow and shoulder joints, during which the fracture should be carefully steadied with one hand.

If the fracture be oblique, there is a great tendency for the fragments to over-ride, and it is well to have a skiagram taken (which can be done without removing the splints) after two or three days, so as to see whether the ends of the bones are in proper position. If there be any serious over-riding, the fracture should be cut down upon and the bones fastened together. The spot chosen for the incision will depend very much upon the position of the fracture and the direction of the obliquity. The best plan, wherever possible, is to expose, not the line of fracture, but the face of one of the fragments, as it is thus much easier to introduce pegs or screws. The incision will generally be a vertical one; if preferred, a flap may be raised on the outer side of the arm. After the soft parts have been divided, the triceps is separated from the brachialis anticus and the deltoid by the finger, and the fractured ends are exposed. In doing this, care must be taken to avoid damage to the musculo-spiral nerve when the fracture is low down. When the fractured ends have been got into proper position, they may be pegged or screwed as may be necessary. After the wound has been sewn up and the usual dressings applied, the method of fixing the limb will be the same as that employed for cases of simple fracture.

*Injury to the musculo-spiral nerve.*—When there is evidence of injury to the musculo-spiral nerve at the time of the accident, and when no sign of recovery is apparent in the course of a few days, the fracture should be exposed and the condition of the nerve ascertained. If the latter be torn across, the divided ends should be brought together and sutured (see Part II., p. 251); if it be merely bruised and the sheath distended with blood, the latter should be evacuated by a vertical slit in the sheath. The after-treatment will be that for contusion of nerves (see Part II., p. 248). When the fracture has to be exposed for this purpose, the surgeon will naturally take the opportunity of fastening the fragments together.

When the nerve becomes involved in the callus at a later period, it will also be necessary to cut down upon it without delay, as otherwise extensive and permanent degeneration may occur. The incision should be a vertical one on the outer side of the arm (for the steps of the operation see Part II., p. 273); the nerve is exposed, traced to the seat of fracture and its relation to this ascertained. Any mass of callus surrounding the nerve should be carefully chipped away, the greatest care being taken to avoid damaging the latter in the process. If the nerve be simply stretched over a mass of callus, enough should be chiselled away to remove all chance of pressure.

## FRACTURES OF THE LOWER END OF THE HUMERUS.

**VARIETIES.**—Fractures in this situation are fairly common and are generally produced by indirect violence, such as falls upon the out-stretched hand. They may also occur from direct violence and then usually result from falls upon the elbow. These injuries are of great importance, chiefly because they are extremely likely to lead to considerable interference with the movements of the elbow joint, and it depends largely on the method of treatment adopted whether the patient be left with a stiff elbow or a useful one. The following are the chief fractures which occur in this region :

(1) **Supra-condyloid fracture.**—This is perhaps the most common of the fractures about the lower end of the bone. The fracture runs across the humerus just above the joint; its line may be somewhat irregular but it is always more or less oblique, usually from above downwards and forwards. The fore-arm and elbow are carried upwards and backwards as the result of the force, and the lower fragment goes with them, being drawn up behind so that the lower end of the shaft of the humerus comes to lie in front of the elbow, generally more or less closely in contact with the ulna. The lower fragment is also bent somewhat forwards. The result is that the fracture cannot be properly reduced by traction on the fore-arm owing to the flexion of the lower fragment, and unless reduction be effected, the movements of the elbow joint are greatly interfered with; some power of extension may be retained, but flexion beyond or even up to a right angle is practically lost.

(2) **Separation of the lower epiphysis.**—In young subjects this may take the place of the fracture just described. These cases are rarely simple separations of the epiphysis, as usually the line of fracture, like the one just mentioned, extends obliquely upwards and backwards. The displacement is practically the same as that of the supra-condyloid fracture.

(3) **T-shaped fracture into the joint.**—It sometimes happens after severe injuries that, in addition to the supra-condyloid fracture just described, there is also a vertical fracture of the lower fragment into the joint,—an addition generally spoken of as a **T-shaped fracture** of the lower end of the humerus. The direction of this vertical fracture varies; sometimes it is more or less oblique but usually it enters the joint between the two condyles.

This fracture is of the highest practical importance, because in it we have to do with a comminuted fracture of the lower end of the humerus, and in it there is not only backward displacement of the fragments as a whole, but the two portions into which the lower fragment is split up are displaced on one another and the consequence is that little or no movement in the elbow joint is likely to result, except where the most perfect reduction has been obtained and maintained. The conformation of the elbow joint is

such that very slight irregularity of the joint surfaces is sufficient to largely prevent movement.

(4) **Fractures of the condyles.**—Fractures of either the external or the internal condyle of the humerus may also occur. The line of fracture starts above the condyle and runs obliquely downwards into the elbow joint, terminating between the condyles. Here also there is generally a considerable displacement of the broken fragment which it is very difficult to overcome satisfactorily; serious interference with the movements of the joint is very likely to result.

(5) **Fracture of the internal epicondyle.**—The internal epicondyle may be broken off as the result of direct violence, and the detached fragment is usually pulled forwards and downwards by the action of the muscles attached to it. The resulting disability is not very great because the displacement is usually only slight, but if the separation be considerable there may be more or less marked loss of power.

**TREATMENT.**—The important points in the treatment of these fractures about the elbow are to secure accurate adaptation of the broken surfaces, to maintain the fragments in position whilst consolidation is occurring and at the same time to prevent the occurrence of adhesions, which, if unchecked, might render it impossible to obtain a moveable joint. The difficulty is much increased by the small size of the fragments and the impossibility of bringing proper pressure to bear on them to maintain them in position.

(1) **Of supra-condyloid fracture.**—This fracture should always be reduced under full anaesthesia. Although reduction is fairly easily effected by flexing the elbow to a right angle and then making extension with one hand whilst the fragments are manipulated into position with the other, recurrence of the deformity is very apt to occur, owing to the obliquity of the fracture. Evidence obtained by means of skiagraphy is steadily accumulating to show that the fully flexed position is the only one that is likely to maintain the fragments in good position. After the fracture has been reduced, the elbow should be flexed as far as the swelling will permit, and, if necessary, a pad may be placed in the bend of the elbow over the lower end of the upper fragment, and another behind over the point of the olecranon; these pads are secured by a figure-of-eight bandage. The point of the elbow will thus be pulled forward, and the lower end of the upper fragment pushed backwards. In order to maintain the flexed position, a Croft's splint, consisting of an anterior and posterior portion reaching from the upper third of the arm to the lower third of the fore-arm, should be put on (see Fig. 8), and if necessary this may be strengthened opposite the elbow by pieces of block tin or strands of tow impregnated with plaster incorporated in the splint; this splint is better than one of guttapercha or poroplastic material. The elbow and fore-arm should be supported by a large sling and fastened to the side.

It is very important to ascertain by means of a skiagram, after the

lapse of two or three days, whether the bones are in good position. If this be the case, the splints may be removed at the end of a week, and passive movement and massage begun. This should be carried out daily from that time forward, the lower end of the humerus being grasped so as to fix the fragments, and the splint being re-applied after each sitting. For details as to the method of carrying out massage and passive movement the reader should refer to the section dealing with the treatment of fractures by massage (see p. 29). This fracture is one in which the massage treatment there detailed is likely to prove exceedingly valuable.

Union generally occurs rapidly, and with reasonable care there is no danger of disturbing the fragments; if the splints be reapplied each time after the massage and passive movement no displacement is likely to occur. In about a fortnight the arm may be brought down to a right angle, and after a short time longer the angle may be gradually increased; the back splint, which must be put on afresh after each change in position, should however be worn for something like four weeks after the injury, at the end of which time the arm may be kept in a sling and the patient encouraged to move it. Usually a prolonged period of massage and passive movement is required, as not only do adhesions occur in the joint, but a considerable mass of callus is thrown out, which for a time interferes mechanically with movement, but which gradually becomes absorbed.

(2) **Of T-shaped fracture.**—The difficulty in treatment is here much increased, and, in fact, it is so great that it is almost hopeless to attempt to obtain a useful moveable joint by treating the fracture merely by splinting and massage; the only probability of getting a really good result is by operative interference. This consists in cutting down upon the fracture and securing the broken ends in proper position.

Before proceeding to operate, the fullest information possible regarding the size, shape, and position of the fragments should be obtained by means of a series of skiagrams. The parts are best reached by free lateral incisions, one over each condyle, but care must be taken not to detach the tissues too freely from either condyle, as otherwise the nutrition of the fragments might be interfered with; when one or both fragments are small it will be better to cut down in the middle line behind, split the triceps, peel it off to a slight extent from the olecranon without cutting it across, and so to gain access to the fracture without unduly denuding the condyles.

The skin is purified in the ordinary manner, but after the joint is opened it is well to use a weak sublimate solution (1-8000) for the further steps of the operation, so as to avoid irritation of the joint surfaces. Any small loose fragments are removed, and all blood-clot sponged or irrigated out of the articular cavity. The two fractured condyles are then pegged together. In order to do this, it is best, when a median vertical incision is employed, to make a smaller lateral incision over one condyle in

addition; through this a drill is passed while the bones are held in accurate apposition and is made to perforate the two condyles transversely from side to side. When lateral incisions are used, the drill is passed through one of them.

Into the drill hole is driven either a plated steel pin, the end of which projects from the opening to permit of its subsequent removal, or a square ivory peg, which may be cut short and left in. Through the posterior incision the condyles, thus united to one another, should be fastened to the shaft of the bone by suitable pegs or screws if the obliquity of the fracture allows; if not, a wire must be employed. Generally the antero-posterior diameter of the bone at the seat of fracture will be so small that the use of the smallest screws or pegs is out of the question, and a wire or wires must be inserted. The steps of the operation must, however, vary according to the circumstances of each individual case, and cannot be described in fuller detail. Sometimes the course of the line of fracture is such that the best hold will be obtained by merely screwing each condyle separately to the shaft without joining them to each other first.

The wound is sewn up without a drainage tube after all the bleeding has been arrested, and the limb is put up in a Croft's splint in the fully flexed position. The operation must of course be done with strict attention to antiseptic precautions, and the wound should heal by first intention. The subsequent treatment is the same as where no operation has been performed, namely, the use of massage and passive movement. If a metal pin has been inserted it may generally be removed about the end of the third week, but there is no reason why movements and massage should not be carried out without reference to it, provided that a piece of gauze soaked in a 1-2000 sublimate solution be carefully wrapped around the end of the pin and the wound in the skin during the performance of massage.

(3) **Of fractures of either condyle alone.**—The joint is here of course necessarily involved, and the surgeon has the choice of two procedures, either to put the patient under an anæsthetic, manipulate the fragments into proper position and then put up the limb much in the same position as that recommended for supra-condyloid fracture, applying a pad over the front of the fractured condyle to keep it in place, or to cut down and secure the fragments accurately in position. The latter is undoubtedly the better method, for, as has already been pointed out, a very slight irregularity in the joint surfaces will lead to serious disability.

We therefore recommend that operation under strict aseptic precautions should be undertaken without loss of time. A flap with its convexity forwards should be raised over the fractured condyle and turned back until the latter is exposed. The soft parts over the condyle are separated from it to the necessary extent at the upper part by a periosteum detacher and retracted, the elbow being flexed whilst this is done. The line of



fracture is then exposed, the finger inserted, all blood-clot cleared out, the joint washed out with a stream of 1-8000 sublimate solution, and any loose portions of bone that may be felt in the interior removed. The parts are then held in accurate apposition by an assistant while the surgeon runs a drill across the lower end of the humerus from one condyle to the other in a direction transverse to the long axis of the bone. A square ivory peg is then inserted and cut short, or, if the bone be too thin for this, a plated steel pin may be used; the subsequent treatment is the same as before. The limb is put up at right angles on an angular lateral splint reaching to the fingers; in the case of the internal condyle the fingers should be flexed so as to relax the muscles arising from it. Passive movement should be carried out from the end of the first week as already described.

(4) **Of fracture of internal epicondyle.**—The fracture is here entirely outside the joint, and if there be no very marked separation, it is generally sufficient to put the arm up on an external angular splint, with the wrist and the fingers flexed so as to relax the flexor muscles; an attempt may be made to press the fractured portion of bone back into position by means of a suitable pad and strapping. If, however, there be any difficulty in getting the fragment back into place, it is easy to expose the tip of the condyle and fasten it in position by a silver wire.

## CHAPTER IV

### FRACTURES OF THE FORE-ARM AND HAND.

#### *FRACTURES OF THE BONES OF THE FORE-ARM.*

##### FRACTURE OF THE OLECRANON.

**CAUSES.**—This accident is generally caused by direct violence from falls upon the tip of the elbow, the olecranon coming into violent contact with the ground. Sometimes however it may occur from muscular action alone, the olecranon being snapped off by the sudden contraction of the triceps when the arm is bent at right angles. The fracture usually occurs near the base of the olecranon, but in some cases the tip alone may be broken off, while in others the fracture runs obliquely from below upwards and forwards into the joint near the front of the greater sigmoid cavity.

**DISPLACEMENT.**—The process is generally completely separated, but sometimes the fibrous expansion of the triceps and anconeus muscles over the back of the bone may remain intact, when only very slight separation of the fragments occurs. When the tip of the olecranon is broken off and the fascia is torn, the small piece of bone is often drawn up the arm for some considerable distance. In fractures in the usual situation, near the base of the process, the amount of separation depends upon how far the fibrous tissues are intact; in those still lower down, in which a part of the curved articular surface of the ulna remains in connection with the olecranon, the separation is not very marked, particularly when the arm is straight, as the curved articular surface prevents displacement upwards. In any case, however, the separation of the fragments is increased when the elbow is bent.

Fracture of the olecranon entails more or less inability to extend the fore-arm. When bony union does not take place, the patient is unable to throw, to forcibly extend the arm, to carry heavy weights and so forth. In fact the limb, even when the separation is not great, is much feebler than its fellow; its range of movement is also not infrequently much

hampered by the presence of firm adhesions in the joint. Hence it is of importance to obtain bony union if possible, for in the majority of cases treated by apparatus, union occurs only by fibrous tissue, which is apt to stretch afterwards, until in the long run the case is practically one of ununited fracture.

**TREATMENT.**—**In recent cases.**—The best treatment is to cut down on the fracture, to remove any structures interposed between the fragments, and then to fix the olecranon in place by a silver wire capable of standing considerable strain.

**Operative.**—As soon as possible after the fracture is diagnosed, the patient should be put under an anæsthetic, the parts disinfected in the usual manner, and the fracture fully exposed. The elbow joint is semiflexed and the forearm is carried across the chest, while the surgeon stands upon the affected side. The limb may be extended while the flap is being marked out, but access to the joint in the subsequent stages is facilitated by the semiflexion.

The *incision* should be curved, with its convexity downwards; a straight one does not give such free access to the fracture, and it has the further disadvantage that the wire is apt afterwards to penetrate the thin scar which then lies directly over it, and, should refracture occur, the scar is liable to give way and to lead to a compound fracture. The incision should begin on one side of the olecranon just below the line of fracture, and should run upwards across the back of the elbow to about an inch above the tip of the olecranon, and then downwards on the opposite side to a point corresponding to that from which it started<sup>1</sup> (see Fig. 31). The flap thus marked out should consist of skin and fascia only, and is turned down so as to give free access to the parts; when the fracture is reached, the torn fascia and the gap between the fragments are at once evident. The rent in the fascia should then be examined; if it be incomplete, it is well to enlarge it. The torn edges of the fascia will be found

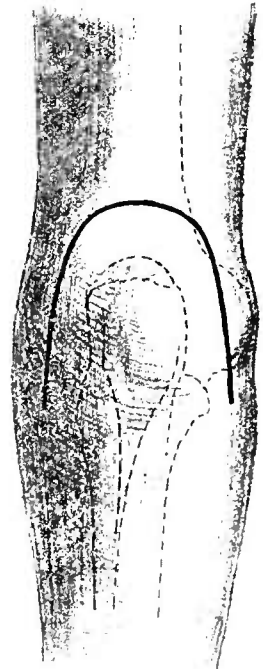


FIG. 31.—INCISION FOR WIRING THE OLECRANON. The dotted lines indicate the outline of the bones.

<sup>1</sup> It is not a matter of much importance whether the incision be made as above and a flap thrown down, or whether a flap be turned up by making an incision with its convexity downwards on the fore-arm reaching well below the line of fracture. In recent cases the one described above is perhaps preferable, as the cicatrix does not lie over a subcutaneous bone surface anywhere. In long standing cases, however, where there is great separation, it may sometimes be advisable to turn the flap upwards because it is then easy to prolong the ends of the incision up along the back of the arm if it should be necessary to lengthen the triceps (see p. 88).

inverted over the fractured surfaces, and must be turned out of the way; all clots must be removed from the joint and from between the fractured ends, the joint must be thoroughly washed out, and preparations made for wiring the bone. As an additional safeguard against infection constant irrigation of the joint should be employed during the operation, the fluid used being 1-6000 or 1-8000 sublimate solution, at about the body

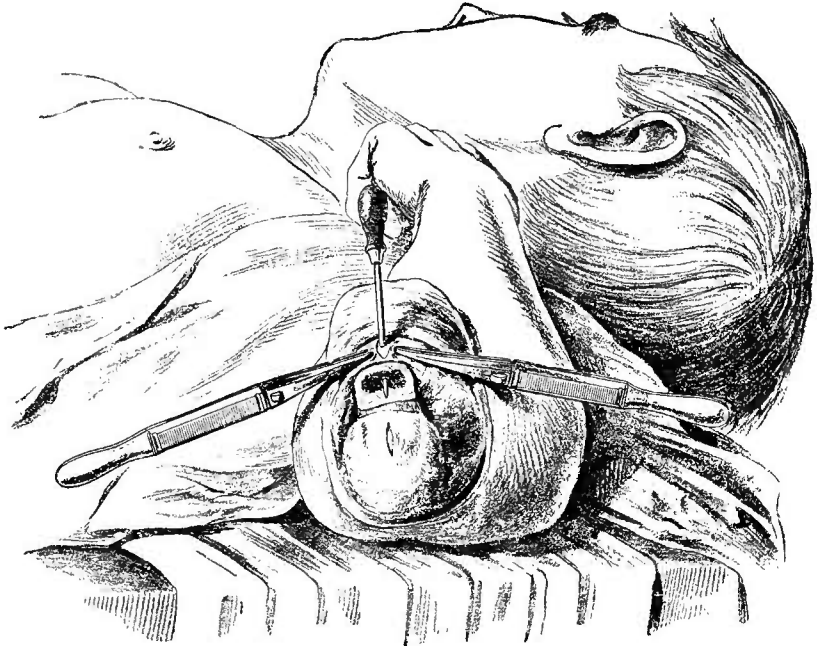


FIG. 32.—OPERATION FOR WIRING THE OLECRANON. *Drilling the bone.* The catch-forceps are shown in position on either side of the vertical incision through the periosteum, the edges of which they hold apart as the drill is passed. The point of the drill is seen emerging just behind the articular cartilage. A vertical slit has been made in the soft parts over the fractured process, which has not yet been drilled.

temperature. The advantage of this is that, while it prevents dust falling into the wound from the air, it at the same time washes out all the blood-clots which are almost certain to have formed in the pouches of the synovial membrane, and so diminishes the chance of subsequent adhesions.

*Wiring* is done as follows: a median vertical incision a quarter of an inch long is made through the periosteum of the ulna about half an inch below the line of fracture, and, before the knife is removed, the two edges of the incision are seized with catch-forceps and held apart, so as to expose the bone beneath (see Fig. 32). Then a hole is bored obliquely through the bone with a bradawl,<sup>1</sup> the point emerging on the fractured surface just behind the

<sup>1</sup>Almost any form of bradawl or drill may be used, but the one we prefer is the square variety used in making bird cages. This is quite similar to the "reamer" shown in Fig. 16.

cartilaginous surface of the joint. After having ascertained the spot on the upper fragment exactly corresponding to this puncture by pushing the fractured ends accurately together, the bradawl is withdrawn, a vertical median incision is made dividing the periosteum over the upper fragment about half an inch above the line of fracture, and its edges are seized with forceps as before. The bradawl is then introduced obliquely through the bone here and made to appear on the fractured surface exactly opposite the hole previously made through the base of the process. A silver wire about a twentieth of an inch in diameter (No. 13 English or No. 5 French gauge) is then pushed through the hole on the posterior surface of the fractured process, and a good length of it is pulled out between the fractured surfaces ;

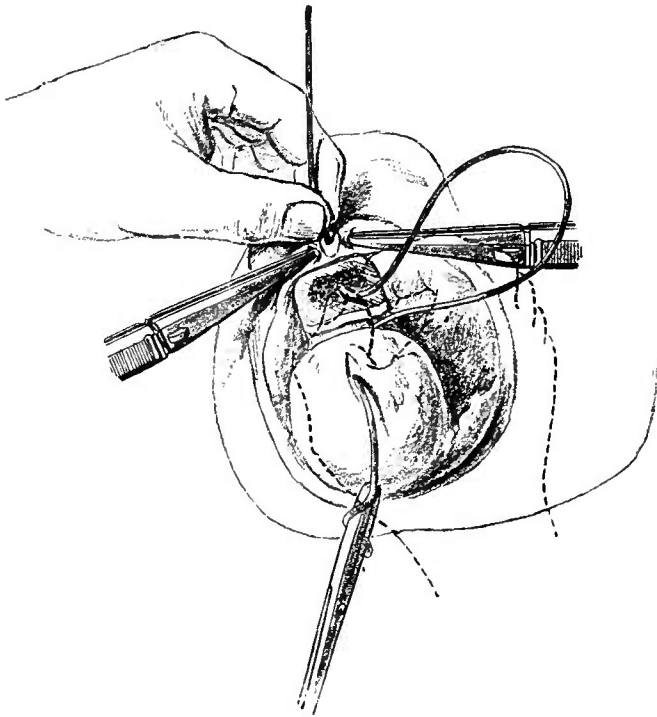


FIG. 33.—OPERATION FOR WIRING THE OLECRANON. *Method of passing the wires.* The elbow is fully flexed to increase the space between the fragments. After the wire has been passed through the hole in the detached process, a long loop, as shown in the figure, is pulled out, and the end of the loop is pushed through the hole in the base of the olecranon from the fractured surface. The catch forceps are in position, as in the preceding figure; those on the detached process have been taken off after the passage of the wire. The hand is put in in dotted outline in order to render the detail more clear.

this is bent into a loop so as to allow the end to be pushed through the corresponding hole on the opposite fractured surface, and thus to be made to emerge from the aperture at the base of the process (see Fig. 33). During the passage of the wire it is necessary that the edges of the slits in the periosteum and fascia made before introducing the bradawl should be held

aside by forceps as recommended above. Otherwise, on attempting to introduce the wire through the first hole it may be very difficult to find the aperture in the bone, and when the end emerges from the second hole it may very easily become entangled in the fascia and may be pushed down the arm for a very considerable distance; the little manoeuvre just described obviates the possibility of this. During the passage of the wire the manipulations are much facilitated by fully flexing the elbow and so increasing the gap between the fragments.

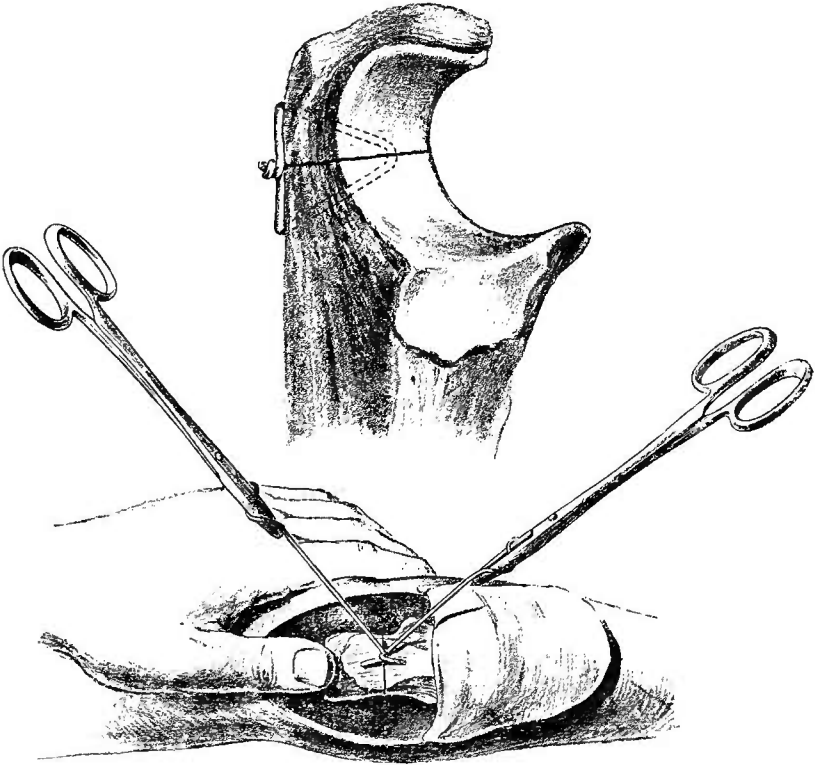


FIG. 34.—OPERATION FOR WIRING THE OLECRANON. *Twisting the wire.* The lower figure shows the elbow joint extended fully and the fractured process pushed down in place by an assistant, as the wire is twisted. The upper figure represents diagrammatically the direction of the wire and the manner in which it brings the fragments together when it is twisted.

When the wire has been introduced, the elbow is extended, and traction is made on the two ends of the wire by grasping them in strong forceps, by which it is pulled quite straight; an assistant pushes the fractured surfaces together, brings them into accurate apposition and the wire is then bent round and twisted into two or three turns (see Fig. 34). The wire is cut off short and the ends are hammered down on to the bones with a small tack-hammer, so as to be completely buried in the fascia. The wound is sutured without a drainage tube and the usual antiseptic

dressings are applied. A considerable mass of dressing should be put on, so that when it is secured by the bandage, the movements of the joint will be considerably hampered; it is well to put on the dressings and bandage with the elbow flexed almost to a right angle. The wire of course will prevent any separation of the fragments, and the rectangular position is better than the straight as far as the subsequent movement is concerned; no splint is necessary. The arm is placed in a sling, and if the patient moves the elbow joint a little inside the bandage he cannot do so enough to interfere in any way with the healing of the wound.

*After-treatment.*—This dressing should be kept on for about a week, and when it is taken down the wound will have healed; the stitches are then removed and a collodion dressing is applied. The arm is replaced in the sling, but before doing so it is well to employ a little passive movement; as a general rule, no adhesions of any consequence will be found. After the lapse of another two or three days, in all about ten days after the operation, the patient may be allowed to dress, to put the arm into a sleeve, to move it for purposes of feeding and so forth, and, while he is enjoined not to lift or move heavy weights, no marked restriction need be placed on its use; in two or three weeks after the injury the arm is generally found to be quite as useful as it was before. Of course at this time there is no bony union, but if a sufficiently strong wire be used and firmly tightened it does not yield at all, and normal bony union occurs in spite of the movement of the joint. In this way adhesions are avoided, and there is no necessity for the employment of forcible movements and massage later on.

*Choice of cases for operation.*—As a rule it is best to wire all cases of transverse fracture of the olecranon. It is certainly quite necessary to wire fractures of the tip of the process and fractures in the ordinary situations with marked separation. But it is also well to wire even fractures lower down with little separation, because, although there is no separation when the arm is straight, it occurs during flexion, and unless wiring be done the limb has to be kept on a splint for several weeks in the extended position to prevent union with angular deformity. This interferes with the due performance of passive movement, the result being that there are often very considerable adhesions and more or less permanent stiffness.

**Palliative.**—When there is some grave constitutional disease, such as diabetes, which prohibits the use of anæsthetics or operative interference, or when the patient is very old or declines an operation, some form of apparatus must be used. Should skiagraphy show that the fracture is starred or comminuted, as it sometimes is, it will also be better to employ apparatus. The simplest is a straight splint along the front of the upper and fore-arm, with a pad in the bend of the elbow, so that the arm is not absolutely straight; otherwise the position becomes so irksome and painful that the patient insists on discarding the apparatus. An attempt should also be made to bring the upper fragment into contact with the lower by strapping. The arm is abducted to a right angle, and narrow strips of strapping are

applied with their centre above the fragment (over which is placed a small pad of boracic lint) and the ends are brought obliquely downwards to the sides of the splint below the elbow; it is well to make a small notch in the splint on either side to prevent the strapping slipping up. By this means the two fragments may be kept in apposition for a time if there is not much separation. The strapping will require daily inspection and frequent renewal. If there be much effusion into the joint—as is very apt to happen in cases not operated upon—an ice-bag or Leiter's coils may be applied over the point of the elbow.

*After-treatment.*—The chance of bony union is, however, comparatively slight because the torn fascia is turned in over the broken surfaces and prevents accurate apposition. The fracture will have to be kept in this position for something like six weeks; the limb must of course be taken off the splint from time to time, so as to allow of the employment of passive movements. When these are carried out, the upper fragment must be very carefully fixed and pressed downwards in contact with the lower whilst the elbow is being bent. Even in spite of passive movement there is often a considerable amount of stiffness left, and this is partly due to adhesions in the joint and partly apparently to some irregularity in the cartilaginous surfaces of the bone, or to some comparatively trifling contraction of the triceps muscle. It may be necessary to employ an anæsthetic to break down these adhesions; the greatest care must be exercised to avoid the risk there always is of tearing through the weak ligamentous union between the fragments.

**In old cases.**—Besides these, cases treated by apparatus are met with in which the fibrous tissue has become so stretched that there is no effective union between the fragments at all; these may be looked upon as ununited fractures. As a result, the patient sometimes suffers a considerable disability; this is more likely to be the case if he has to earn his living by manual labour. These patients not infrequently apply for relief, especially when the right arm is affected. The only effectual treatment is that afforded by operation, but favourable results are much more difficult to obtain than in recent fractures.

**Operation.**—In operating in these cases a flap should be raised by the curved incision already described (see p. 83); this may have to extend up the arm some considerable distance before the loose upper fragment with the tendinous and muscular tissues inserted into it is thoroughly exposed.

The fibrous material intervening between the fractured surfaces is first cut away and the ends of the bones are refreshed by removing a thin slice from each surface with a saw or chisel, until the whole area of the fracture shows normal bone. An attempt is then made to approximate the fragments; as a rule it is extremely difficult to bring down the upper fragment into contact with the lower and in some cases it is quite impossible to do so without dividing the triceps.

*Lengthening the Triceps.*—If the muscle be divided transversely the



upper fibres will contract and a gap will be left in the muscle which may lead to much functional disability. The incision should therefore be V-shaped or zig-zag (see Fig. 35); two V's or serrations, with their apices upwards, carried through the breadth of the muscle are sufficient. It is done as follows: An incision commencing at the left edge of the triceps is carried obliquely upwards and to the right through the muscle for about two inches, according to the amount of shortening present; the termination of this incision should be distant from the left edge one quarter the entire

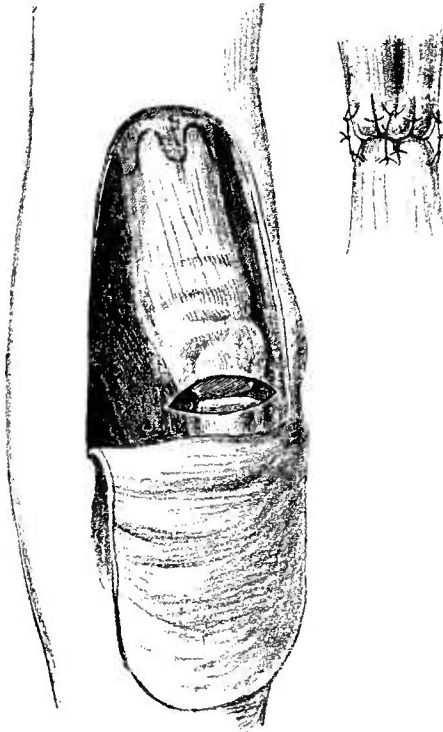


FIG. 35.—METHOD OF LENGTHENING THE TRICEPS IN THE OPERATION FOR WIRING LONG-STANDING CASES OF FRACTURE OF THE OLECRANON. The larger figure shows the long flap required for the exposure of the Triceps, and the serrated division of the muscle described in the text. The smaller figure shows the method of approximating the serrations above and below, and how the muscle is elongated. The apices of the serrations are made blunt in order to secure a larger surface for union.

breadth of the muscle. From this point a second incision is carried obliquely downwards and to the right, terminating in the centre of the muscle on a level with the starting-point of the first. A third incision then runs obliquely upwards, and also to the right, terminating at the three-quarter point, and the division is completed by carrying another from this point obliquely downwards to the right again, and bringing it out through the right edge of the muscle. This gives a series of serrations above and below the line of incision, and when the fragment with the tendon attached to it is pulled down, the apices of the serrations should

be in contact if the incision has been properly planned. The adjacent sides of the serrations above and below are stitched to each other, so that two blunt cones are formed, one above and the other below the line of division of the muscle; the apices of these blunt cones are then stitched together by the muscle suture described in Part II., p. 199. The incision is best made in the lower part of the muscle, so that the apices of the upper serrations include some portion of the tendinous expansion; the best union is obtained if muscular fibres be included in the incisions instead of making them entirely through the tendon.

When the fragment has been brought down by these means, holes must be drilled in it and the wire passed in the manner already described (see p. 84). It is generally found that the bone, especially the detached fragment, is much softer than in recent fractures, and the holes must be bored as far away as possible from the fractured surfaces, so as to get a sufficiently firm hold, for otherwise the wires are apt to cut out. Before the wires are inserted it is well to flex the elbow thoroughly so as to break down all adhesions.

*After-treatment.*—The subsequent treatment is much the same as that already described for recent fractures, but greater care must be taken in carrying out movement, because of the softness of the bone; it is also well to put on a splint for a few days. At first the limb should be put up almost straight, but every two or three days a slight increase in the flexion should be made. As soon as the arm has been brought to a right angle, the splint may be abandoned and a sling substituted for it. In about a fortnight after the operation the patient may be allowed to move the arm to some extent; flexion beyond a right angle should be delayed until bony union has occurred, as otherwise the wire may cut its way through the soft bone.

The difficulty in getting a useful arm in cases of ununited fracture serves to emphasize the necessity for immediate operation in recent cases, provided always that the surgeon can trust his antiseptic precautions to prevent suppuration in the joint; should such an accident occur the result is likely to be disastrous. All that can then be done is to remove most of the stitches, insert a drainage tube, take out the wire and thoroughly drain the joint cavity. Unless, however, the surgeon feels practically certain that suppuration will not occur he should not undertake the operation.

#### FRACTURE OF THE CORONOID PROCESS.

**CAUSES.**—Fractures of the coronoid process are of very rare occurrence and practically only occur in connection with dislocation of both bones of the forearm backwards. The point that leads to the diagnosis of this condition in backward dislocation of both bones is that, while the dislocation is easily reduced, the bones of the forearm tend to slip back again unless steps are taken to prevent it. In addition to this, in some cases the loose fragment of the coronoid may interfere with full flexion of the limb.

**TREATMENT.**—The treatment is very difficult, for union practically always takes place by fibrous tissue. The best plan is to flex the joint fully after completely correcting the backward displacement; the brachialis anticus is thus relaxed and the broken surfaces brought as nearly as possible into contact. A pad is applied over the olecranon to prevent the bones of the fore-arm slipping backwards and then a back splint of poroplastic material should be moulded on while the limb is in the flexed position. As the union is by fibrous tissue, there is no need to keep the parts at rest too long, and passive motion should be begun within the first fortnight and kept up daily for about four or five weeks, when all apparatus may be left off.

This injury does not usually give rise to any marked disability except when much callus is thrown out; this may form an obstacle to flexion. Occasionally ossification seems to extend upwards in the tendon of the brachialis anticus, and a spurlike process is formed which greatly hampers movement, and may necessitate removal of the offending portion of bone. The best access to the bone is then obtained by lateral incisions, one on either side of the joint, just over or slightly in front of the condyles of the humerus. Care must of course be taken not to injure either the median or the musculo-spiral nerve in dissecting down. The muscles are peeled off the condyles and the soft parts pulled forwards from the front of the joint with a spatula; the brachialis anticus with the coronoid process embedded in it is thus exposed, and the mass of bone may then be shelled out. It is not easy to perform this operation satisfactorily, unless an external incision be made as well as one over the inner condyle; this greatly facilitates matters, because, by means of the finger pushed in through the external incision, the muscle and its tendon can be displaced to the inner side and rendered much more readily accessible. The connection between the muscle and the base of the coronoid process is not disturbed in this operation, and the full power of flexion will therefore be regained.

When there is bony union with exuberant callus, the latter must be chipped off and the detached portion dissected out.

#### FRACTURES OF THE HEAD AND NECK OF THE RADIUS.

**Causes.**—Fractures in this situation are rare but of great importance; they usually result either from direct violence or from injuries occurring in connection with dislocation. In young children a fall upon the hand may produce dislocation of the radius or separation of its upper epiphysis. In adults the injury is generally caused by a direct blow on the outer side of the arm, and we have seen cases of vertical fracture of the head of the radius with detachment of a portion of the head, which was lying free in the elbow joint. In this accident there is practically no chance of getting union, while the loose fragment causes a mechanical obstruction to movement and leads to great pain and thickening of the tissues of the joint, and the

formation of adhesions. The diagnosis of a loose piece of bone in the elbow is materially facilitated by the use of skiagraphy.

**Treatment.**—It is well to cut down upon the detached fragment and remove it as soon as possible. The best method of gaining access to the head of the radius is by an incision on the posterior and outer surface of the elbow joint close behind the outer condyle of the humerus. It should commence just above the external condyle and run downwards and a little backwards towards the posterior border of the ulna for about three inches. This incision should lie between the triceps and the radial extensors of the fore-arm above and over the interval between the extensor carpi ulnaris and the anconeus below. When these two latter muscles are separated, the capsule of the head of the radius with the orbicular ligament are exposed. The capsule is opened by a horizontal incision, the parts are held aside and the head of the radius is snipped off with a pair of cutting pliers. If a considerable portion of the articular surface of the radius be intact there is no need to take this away; the detached portion should merely be removed and the wound in the joint sutured. If however the portion remaining attached to the shaft be very small, it is best to clip it away and thus to excise the head of the radius. The slight shortening that occurs does not in any way interfere with the movement of the arm. The incision in the capsule is sutured with fine catgut, and the skin wound stitched up without a drainage tube.

*After-treatment.*—The after-treatment will be the same as that already described for fracture of the olecranon (see p. 87); passive movements must be resorted to early and maintained persistently.

**When the epiphysis has been separated** the arm should be put up in the position of full supination upon an anterior angular splint; a posterior straight splint should be also applied along the back of the fore-arm and passive movement should be carried out after the first ten or fourteen days.

#### FRACTURES OF THE MIDDLE OF THE FORE-ARM.

Either bone of the fore-arm may be fractured separately, or fracture of both bones may occur at the same time.

##### FRACTURE OF THE ULNA ALONE.

**DISPLACEMENT.**—This is a comparatively rare injury and is generally due to direct violence. The displacement depends to a great extent on the direction of the force and the situation of the fracture, and may not be at all marked. The upper fragment is often tilted forwards by the brachialis anticus, while the lower one is pulled outwards towards the radius by the pronator quadratus. The subcutaneous position of the bone allows the displacement to be readily made out by manipulation.

Fracture of the ulna may be complicated with dislocation of the head of the radius. When this happens the usual condition is a fracture of the

ulna at the junction of the upper with the middle third and a forward dislocation of the head of the radius.

**TREATMENT.**—Of a simple fracture.—The treatment should be directed first to bringing the fractured ends into apposition by manipulation, which is best accomplished under an anæsthetic. The arm is then put up on an internal angular splint with the elbow at right angles and the fore-arm midway between pronation and supination. More comfortable than the ordinary wooden splint is a moulded one of poroplastic material which partly encircles the arm and holds the fore-arm in proper position; the fingers should be left out and should be actively exercised. This splint should be kept on for four or five weeks, after which time the patient may be allowed to use the arm.

**When there is also dislocation of the head of the radius.**—*In recent cases* reduction of the dislocation is very readily effected under chloroform, provided that the lesion be recognised; any doubt as to the exact nature of the case may easily be cleared up by a skiagram. The head of the radius is pulled into place by simple extension, and at the same time the fracture is reduced. The fractured ends are then manipulated into position, a pad is placed in front of the head of the radius to prevent recurrence of the dislocation, and splints are applied. The fore-arm should be put up more nearly in the supinated than in the pronated position, with the elbow at a right angle. For this purpose a moulded splint is much more efficacious than the flat internal or external angular splint. Passive movements, especially those of rotation, should be begun within the first fortnight.

*In long-standing cases*, where an unreduced dislocation of the radius exists, it is usually necessary not only to cut down and divide the fracture of the ulna, but to remove the head of the radius. It is sometimes possible to get the head of the radius into proper position after dividing the fractured ulna, but, if not, the loss of the head of the radius does not materially affect the movement of the elbow joint. For the method of exposing the head of the radius, see p. 92. Access to the fracture of the ulna will be got by cutting down directly on it over the subcutaneous surface.

#### FRACTURE OF THE RADIUS ALONE.

**CAUSES.**—This generally occurs from indirect violence, such as a fall upon the hand, and is far commoner than fracture of the ulna alone.

**DISPLACEMENT.**—The displacement varies according as the fracture is above or below the insertion of the pronator radii teres muscle. In the former variety the upper fragment will be in a position of complete supination; this is due to the action of the biceps and the supinator brevis muscles. It is also somewhat flexed by the action of the former. The lower fragment, on the other hand, will be pronated by the two pronator muscles, and it will also be drawn somewhat inwards towards the ulna. On the other hand, if the fracture be below the insertion of the pronator

radii teres, the upper fragment remains in a position midway between pronation and supination, while the lower is completely pronated and drawn inwards towards the ulna.

**TREATMENT.**—Of fracture above the insertion of the pronator teres.—The elbow must be flexed to a right angle and the fore-arm put in the position of complete supination. This can be done by an anterior rectangular splint and a posterior straight one reaching from the olecranon to the back of the hand. A pad should be placed over the lower end of the upper fragment, so as to keep it back in position, and the elbow and fore-arm should be supported by a large sling.

These splints should be kept on for about four weeks, when passive motion may be commenced; it is well not to discard the anterior splint altogether until about six weeks have elapsed from the time of the injury.

Of fracture below the insertion of the pronator teres.—The fore-arm should be put up at right angles in a position midway between pronation and supination. The best splint is an external angular poroplastic one, moulded to the arm and fore-arm, and made to surround the limb more or less completely; it is moulded to the limb while the latter is held in proper position. It should extend almost up to the axilla above, and below it should fix the hand, but the fingers should be left free. A Croft's plaster of Paris external splint may also be used, or failing either of these, an ordinary wooden internal angular splint with an external straight splint over the posterior surface of the fore-arm.

#### FRACTURES OF BOTH BONES OF THE FORE-ARM.

**CAUSES.**—This is not an uncommon form of injury and may occur either from indirect violence, as in a fall upon the out-stretched hand, or from direct injury.

**DISPLACEMENT.**—This is generally only slight and is influenced largely by the force producing the fracture. The fracture of the radius is often oblique, and there may in some cases be a good deal of over-riding of the fragments.

**TREATMENT.**—There are two important points in the treatment of these fractures in the middle of the fore-arm. In the first place, it is in this situation that ununited fracture of the radius is fairly common, and this no doubt results from want of proper fixation of the elbow; the movements of pronation and supination are insufficiently guarded against. In the second place, there is a tendency for the four fractured surfaces to be drawn towards one another, and union may actually take place between them, and thus there may be complete loss of pronation and supination. Non-union is avoided by fixing the elbow joint so that pronation and supination are impossible. Fusion of the fractured ends may be prevented by avoiding all lateral pressure on the bones after proper coaptation.

In all these cases it is well to give an anæsthetic before reducing the fracture. This enables the fragments to be got into better position and

ensures their keeping in place until the splints have been applied. The next important point is the determination of the position in which the fore-arm shall be put up; this depends upon the situation of the fracture in the radius.

When the fracture is above the insertion of the pronator radii teres, the fore-arm must be in the position of full supination, and an anterior angular and a posterior straight splint should be applied. When the fracture is below this point, the limb should be midway between pronation and supination, and either the moulded splint or internal angular and external straight wooden splints should be employed. In other words, the limb is put up as if for a fracture of the radius alone (see p. 94). The width of these splints should be somewhat greater than the transverse diameter of the fore-arm, so that the bandage fixing them cannot exert any lateral pressure upon the bones; at the same time the splints must not be too broad, as otherwise the arm might slip about from side to side if the bandages become loose, and thus the deformity could readily recur. Whenever wooden splints are employed they should be cut to the shape of the fore-arm, and should be wide enough to project about half an inch beyond it everywhere; hence they must be much broader above opposite the bellies of the muscles than about the wrist. The ordinary splint as supplied by instrument makers is not at all suitable; if used, it must be cut to fit the arm.

It is very often recommended that a pad should be applied between the bones along the middle of the fore-arm in front, so as to prevent union of one bone to the other; this is quite useless, for no pad which does not exert injurious pressure on the circulation could separate the bone ends. The surgeon must rely for success upon proper reduction and immobilisation of the fracture.

*After-treatment.*—In putting up these fractures, the pressure of the splints must not be so severe as to cause a risk of gangrene; the fingers must always be left out of the splint, which should not extend further down than the transverse crease of the palm, so as to allow of active and passive movement of the fingers being practised from an early stage. The fore-arm should be placed in a sling supporting both the elbow and the hand. The splints may be left undisturbed for about three weeks, at the end of which time they should be taken off in order to practise active and passive movements of the wrist and elbow joints. The splints must not be altogether discarded until about the fifth or sixth week, and not then unless the union be firm. This is a point of considerable importance, as there is not the same risk of stiffness in the joints or about the tendon sheaths as in the fractures lower down, whilst the risk of non-union is very considerable.

**Green-stick fracture.**—This is of common occurrence in children; the treatment is practically the same as in the fracture just described. The bones must be forcibly straightened before the limb is put up, and this is best done under an anæsthetic. The splint need only be kept on for three weeks; after that the arm should be worn in a sling for another ten days.

**Mal-union in fractures of both bones.**—When the bones have become fused together by callus so that pronation and supination are lost, it may be necessary to expose the seat of fracture and chisel away the uniting medium; this will free the bones and permit restoration of their movements. The best route to the bones is through an anterior oblique incision in a line from the internal condyle of the humerus to the styloid process of the radius over the situation of the fracture; this will enable the surgeon to pull the pronator upwards and the flexor muscles of the wrist and hand downwards and inwards. The incision must be free, and the muscles on the front of the fore-arm should be fully relaxed by flexing the elbow, the wrist, and the finger joints. When the superficial muscles have been pulled out of the way, the callus will be easily defined, and may be carefully cleared by a rugine from the middle line outwards, and thus the seat of fracture is exposed. The redundant callus is then chiselled away, and it may be possible to do this without dividing the union between the fragments of the individual bones if the fracture has united in good position; should there be angular deformity, however, the union must be cut through and the position rectified. This may perhaps be done through the original incision, but it may be necessary to make one or more additional incisions directly over the lateral aspect of the fractures, in order to get proper access to it.

After the wound has healed, passive motion should be commenced at once; as the fracture will have already united previous to operation, there is no necessity for keeping the limb in splints.

In badly united fractures with marked deformity and loss of usefulness of the hand it may also be necessary to expose the fracture and divide the union with a chisel. Two incisions must be made, one over each side of the limb. As it is often very difficult to get union after the operation, it is well to divide the bones very obliquely so as to have large cut surfaces in apposition. These can then be secured together either by wires, applied as in Fig. 18, or by means of a couple of fine screws (see p. 51). When the patient is young and the bones are small, wires are probably better, because screws are apt to split the ends of the bone, whereas a wire inserted as already described (see p. 52) will hold them very satisfactorily.

**Ununited fracture.**—To secure union in ununited fractures of the fore-arm an operation is necessary, and the best access to the bones may be got through longitudinal incisions over the outer and the inner borders of the fore-arm. When the bone has been ununited for some time, a quarter or half an inch of the dwindled ends must be removed. When one bone only has been broken, the removal of this amount will cause a gap between the ends because of the unyielding sound bone; it will therefore be necessary to divide the latter at a corresponding spot, and to remove enough of it to enable the fragments of the fractured bone to come into position. The treatment of the divided bone will be the same as that just described for mal-united fractures.



In both ununited and badly united fracture it is as well after operation to fix the elbow joint as well as the hand, and a Croft's splint is the best method of doing this. The splint should extend as high as the axilla; if it does not the elbow joint will not be properly fixed. As soon as the wound has healed, the arm should be put up in a silicate casing which extends as high as the axilla, fixes the elbow at a right angle and keeps the fore-arm midway between pronation and supination; the wrist joint should also be fixed, with the hand extended upon the fore-arm and the fingers left free. This apparatus should not be left off until union is complete. It must however be confessed that it is extremely difficult to get firm union after an operation for an ununited fracture of the fore-arm.

#### FRACTURES OF THE LOWER THIRD OF THE FORE-ARM.

The following injuries may be met with in this situation. Fracture of both bones a little distance above the wrist; separation of the epiphysis of the radius; fracture of the radius near its lower end—Colles's fracture; and fracture of the styloid process of the ulna.

##### COLLES'S FRACTURE.

This is by far the most important fracture in this region; it occurs at the lower end of the radius, usually from three quarters to one and a half inches above the articular surface. It is accompanied by a characteristic displacement of the lower fragment and the hand, and is often complicated by rupture of the internal lateral ligament, or by fracture of the tip of the styloid process of the ulna.

**CAUSES.**—The fracture is fairly common and is more frequently met with in old people than in young; it is much more frequent in women than in men. The usual cause is a fall upon the palm of the outstretched hand when the elbow is somewhat flexed; this accident in younger subjects is more likely to produce an injury about the elbow or shoulder joints, but, as life advances and the lower end of the radius becomes more brittle, it usually gives rise to a Colles's fracture.

**DISPLACEMENT.**—In falls upon the palm the force is transmitted from the thenar eminence to the radius, and the bone breaks at its weakest part; at the same time the lower end of the radius is driven backwards and upwards, and is also somewhat rotated, so that the articular surface looks downwards, backwards and somewhat outwards instead of directly downwards. The fracture is usually but not invariably impacted. When impaction occurs, the upper fragment is driven into the lower and it is not uncommon to find the latter considerably split up, the fracture often extending into the joint. The line of fracture is usually more or less transverse from side to side, but is oblique from below upwards and backwards. There is frequently rupture of the internal lateral ligament of the wrist joint and in some cases the attachment of the triangular fibro-cartilage to the ulna is also torn through.

**TREATMENT.**—The following are the chief points requiring attention in the treatment of these fractures. 1. The fracture is commonly impacted and its reduction requires considerable force; it is most essential that reduction should be complete. Care must also be taken to see that the wrist joint moves freely and that the movements of pronation and supination are restored. 2. There is always a great tendency to subsequent stiffness of the wrist and fingers because of the close connection of the tendon sheaths with the lower end of the radius in the neighbourhood of the fracture. Teno-synovitis is a more or less constant result, and is frequently followed by adhesion of the tendons to their sheaths. The tendons in front of the wrist are most liable to be thus affected, and the greatest care must be taken to avoid it. 3. Adhesions will generally occur in the synovial membranes of the wrist.

**Reduction.**—This is the first point of importance; reduction often calls for the exercise of considerable force and it is therefore advisable to place the patient under an anæsthetic, when it is easy to reduce the fracture by simple extension. If no anæsthetic be given, reduction may be effected by grasping the limb and placing it palm downwards across the front of the knee with the styloid process of the ulna in contact with the patella, and then, by partly flexing and partly adducting the hand, the impaction may be broken up. Care must be taken to see that the displacement of the articular surface is completely overcome; the best guide to this is to make sure that the styloid processes of the radius on the two sides occupy the same relative level. After the fracture has been reduced, the fragments can readily be kept in place by grasping the lower end of the bone between the thumb and fingers; the thumb is placed on the back of the wrist and presses forward the lower fractured end, whilst the fingers press backwards the lower end of the upper fragment.

**Splints.**—The simplest and best that can be employed are anterior and posterior splints about the width of the fore-arm. There is here no fear of pressing the ends of the bone together, as in the last form of fracture described, and better fixation is obtained with splints the same breadth as the fore-arm. They should extend along the front and back of the fore-arm from the elbow to the metacarpo-phalangeal joints, that is to say, to the knuckles behind, and almost to the transverse crease of the palm in front. They should be cut to the shape of the arm (see p. 95), and the anterior splint should be hollowed out or cut away opposite the thenar eminence, so that the thumb can hang down in a position of more or less opposition. A pad of boracic lint should be placed over the posterior surface of the lower fragment, and a somewhat longer narrow pad should be placed along the front of the upper fragment reaching down to its lower end; the splints are then fixed on firmly. The fingers should be left out, and the patient should be encouraged to move them himself from the day following the accident; the surgeon should also move them freely every day, so as to avoid the risk of immediate adhesion of the tendons to their sheaths.

*After-treatment.*—At the end of the first week the splints should be taken off daily, and passive movement of the wrist, combined with pronation and supination, carried out, care being taken at the same time to avoid displacement of the fragments by grasping the lower end of the fore-arm with one hand and making pressure forwards over the lower fragment with the thumb, and backwards over the lower end of the upper fragment with the fingers; the fracture is thus quite immobilised. At the same time the splints may be shortened a little, the anterior one being cut away so that it ends opposite to the radio-carpal joint. The posterior splint should be continued and the hand bandaged to it; this bandage may be removed twice a day to allow of active and passive movement of the wrist, while the anterior splint need not be disturbed as it does not interfere much with flexion.

During this time the fore-arm should be carried in a sling. At the expiration of three weeks the splints should be left off, the patient encouraged to practise active and passive movements of the fingers and wrist, and massage should be begun. The arm should be carried in a sling for another fortnight during the day, but at night the splint should be re-applied. Considerable œdema often remains for some time after these fractures, but the steady use of careful massage will very soon overcome it.

Various special splints have been introduced for the treatment of this fracture, but nothing will be found better than that we have just recommended. Carr's splint (see Fig.

36) is one that is very popular; it consists of an anterior portion terminating in an obliquely placed bar which is grasped by the hand, and a narrow posterior one, which is applied along the dorsal surface of the radius, from its upper end to just beyond the wrist joint. The outer or




FIG. 36.—CARR'S SPLINT FOR COLLES'S FRACTURE. The splint illustrated is for the left limb. The oblique bar at the end of the anterior splint *A* is grasped in the hand. The radial border of the splint is considerably thicker than the ulnar. There is a depression in the radial side of the splint just behind the oblique bar into which the lower fragment is pressed by the posterior splint *B*.

radial border of the anterior splint is thicker than the inner, and is hollowed out below for the reception of the lower fragment. The oblique bar at the lower end is grasped by the hand, which it brings into a position of adduction. The old "pistol splint" has nothing whatever to recommend it.

**Mal-union.** Non-union is practically never met with in this fracture, but there may be considerable mal-union, either because the fracture has never been reduced or because reduction has been imperfect; the hand is thereby much disabled. We have in two such instances succeeded in removing the deformity and restoring movement by operation. This is best done through a long incision over the lower end of the radius; the line of union is then chiselled through with the same obliquity as the fracture usually has (*i.e.* obliquely from behind downwards and forwards),

and the fragment is completely detached and forced into position. No wire or pegs are required, as the surfaces are broad and union will readily occur.

After the wound has been stitched up, splints are applied as just described (see p. 98). In these cases the splints should be kept on somewhat longer than in a simple fracture, but equal care must be taken to carry out active and passive movements of the fingers and wrist. It is as well to keep the splints on for about five weeks, shortening them as already described. Passive motion of the fingers should always be begun from the very first, and of the wrist after about ten days.

#### SEPARATION OF THE LOWER EPIPHYSIS OF THE RADIUS.

**CAUSES.**—Separation of the lower epiphysis of the radius sometimes occurs in young subjects and is more often due to direct than to indirect violence. If any of the epiphyses give way in the latter form of violence, it is usually that of the lower end of the humerus. The line of separation is more transverse, the displacement is more directly backwards, and there is not the characteristic rotation of the lower fragment, nor do the fragments over-ride as in cases of Colles's fracture.

**RESULTS.**—Bad results not uncommonly follow this accident from arrest of development of the radius; this may be very considerable and may necessitate the removal of a portion of the lower end of the ulna at a later period, in order to keep the articular surfaces in their proper relative positions and to prevent deviation of the hand to the radial side.

**TREATMENT.**—This is essentially the same as that of Colles's fracture (see p. 98).

#### FRACTURE OF THE STYLOID PROCESS OF THE ULNA.

This may occur in connection with Colles's fracture, but it may sometimes be met with as the result of a direct blow over the inner side of the wrist, as for example by a stick.

**TREATMENT.**—The treatment consists in putting up the limb with the hand in the adducted position so as to relax all tension upon the internal lateral ligament of the wrist joint. Union most often occurs by fibrous tissue.

#### FRACTURES OF BOTH BONES.

Fracture of both bones at the lower end of the fore-arm is not common, and usually results from severe direct violence. The treatment is practically the same as that for Colles's fracture (see p. 98).

*FRACTURES OF THE BONES OF THE HAND.*

## FRACTURES OF THE CARPAL BONES.

**CAUSES.**—Any of the bones of the hand may be fractured by direct violence. Fractures of the carpal bones generally result from severe crushes; the injury is then usually a complex one and is very often compound.

**TREATMENT.**—This will be the ordinary treatment of a compound fracture and of a wound of a joint. Any dirt or foreign body must be carefully removed and the question of amputation will of course have to be decided. This will depend upon the amount of injury and on the risk of sepsis, etc.

Cases of simple fracture of the carpal bones may very easily escape notice, but if the lesion be recognised, the wrist joint must be fixed on an anterior splint with the metacarpus thrown somewhat backwards, and cold applied to diminish the swelling. Adhesions, of course, will be very apt to form in these cases, and they must be treated on the ordinary lines.

## FRACTURES OF THE METACARPAL BONES.

**CAUSES.**—Generally these are the result of direct violence, but sometimes they may be due to indirect violence, as in a fall upon the closed fist.

**DISPLACEMENT.**—The first, second, or fifth metacarpal bones are most commonly broken; sometimes there is very little deformity, sometimes there is some overlapping of the fragments. When the third or fourth metacarpal is fractured the displacement is very slight, because the adjacent bones act as splints and keep the fragments in position.

**TREATMENT.**—If there be any tendency to over-riding, the fracture should be reduced by extension of the corresponding finger; it then usually suffices to place a large ball of wool or worsted in the hand and forcibly flex the fingers over it, fixing them in this position with a stump bandage. A dorsal splint may also be put on to fix the wrist joint, but it is seldom necessary unless there be some deformity over which it is desired to apply a certain amount of pressure. There is a tendency for the extensor tendon to adhere to the bone in the region of the fracture, and, with a view of avoiding this, the fingers should be released at any rate once a day so as to allow the patient to extend the finger. At the end of a fortnight the apparatus may be discontinued unless the case be one of very oblique fracture of one of the outer metacarpals, when it should be kept on for a week or so longer. After the splint has been discontinued, the patient should carry the arm in a sling for another week or two and should be encouraged to move the fingers both actively and passively. Massage is also beneficial

in promoting the free mobility of the fingers, and may with advantage be practised from the first.

#### FRACTURES OF THE PHALANGES.

**CAUSES.**—Fracture of the phalanges by direct violence is not at all uncommon. The first phalanx is most commonly fractured owing to its greater length and mobility. The displacement varies according to the cause of the fracture, but in most cases it is comparatively slight.

**TREATMENT.**—After the fracture has been reduced, all that is necessary is to apply a well-moulded block-tin or guttapercha splint. The block-tin splint is the more useful and should be put on the anterior surface and cut so that it covers the greater part of the palm; this palmar portion fixes the metacarpo-phalangeal joint (see Fig. 37). The splint is carefully padded and bandaged on; it should be kept on for three or four weeks. After the first week the fracture should be taken down daily, and, whilst the fragments are fixed, the joints should be well moved and the patient encouraged to flex them; this is necessary to avoid

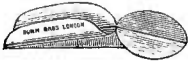


FIG. 37.—METAL SPLINT FOR FRACTURES OF THE PHALANGES. The trough receives the finger while the flattened rounded portion goes into the palm of the hand.

adhesion of the tendons as a result of teno-synovitis set up in the immediate vicinity of the fracture, and also to avoid adhesions of the tendons to the broken bone. Union usually takes place with extreme readiness. If the fracture be compound the treatment must of course be that for compound fracture in general.

## CHAPTER V

### FRACTURES OF THE PELVIS.

THESE injuries are generally of a very serious character on account of the lesions of various important organs that may accompany them. They may best be considered under the heads of fractures of the pelvic ring as a whole, and fractures of the individual bones of the pelvis.

#### FRACTURES OF THE PELVIS AS A WHOLE.

**SEATS.**—Fracture of the pelvic girdle may be produced in a variety of ways; it is commonly caused by the passage of a heavy body, such as a cart, over the pelvis, so that the latter is crushed between it and the ground. The fracture is not uncommonly bilateral; it may be situated on either side of the symphysis, or just outside the symphysis on one side and close to the sacro-iliac synchondrosis on the other. The fracture outside the symphysis generally passes through the horizontal ramus of the pubes and the ascending ramus of the ischium, these two points being the weakest in the pelvic girdle.

**COMPLICATIONS.**—When fracture occurs, one portion of the broken pelvis is often driven inwards and damages the parts immediately beneath. Various structures may be injured in this way; the one most commonly involved is the urethra, the condition of which must always be investigated in all fractures of the pelvis. The existence of a laceration is indicated by bleeding from the meatus; the laceration is generally in the membranous portion and the urethra may be completely or partially torn across. This injury is dangerous, as it may be followed by extravasation of urine, and it is therefore of the very highest importance to ascertain its presence and to adopt appropriate treatment immediately. The bladder is the structure next most frequently injured: this is especially likely to happen if it be distended at the time of the accident. The rectum, the vagina, the femoral or the iliac vessels may also be lacerated.

**TREATMENT.**—When the pelvic girdle is fractured, the first points requiring attention are the collapse, which is always present and is generally

very marked, and the condition of the structures which are liable to damage. The collapse may be treated on the lines laid down in Part I., p. 141; in connection with this point it is worth remembering that stimulants should be withheld until steps have been taken to ascertain whether or not the large vessels are damaged. Directly he is seen, the patient should be warned not to pass water; extravasation of urine from rupture of the urethra, which is an avoidable occurrence, can thus be prevented. A patient whose urethra or bladder is damaged feels a marked desire to pass water and will do so unless he be warned to the contrary. The condition of the urethra and the bladder should be ascertained as soon as possible, and if damaged they should be treated appropriately; this will be described among injuries of the bladder and urethra.

The patient should be put upon a firm mattress over fracture boards, and the knees should be flexed over pillows. If it can be managed, it is as well to use a mattress so arranged that it is not necessary to disturb the patient for the purpose of defæcation; with this object either a perforated mattress or one provided with a removable segment is very useful. A broad bandage of unbleached calico should be applied firmly around the pelvis in order to prevent the falling apart of the sides of the pelvic girdle; if there be displacement it should if possible be remedied whilst the bandage is being put on. There may be considerable deformity, the rectification of which in a female is a matter of some importance; permanent pelvic narrowing which would interfere with child-birth might otherwise result. The most severe deformity results from depression of the symphysis pubis; this is readily enough reduced in the female by means of the finger in the vagina. To enable the proper manipulations for reduction of the deformity to be carried out effectually an anæsthetic is desirable.

During the first fortnight it is necessary to avoid distension of the abdomen, as this is calculated to pull upon the fragments through the agency of the abdominal muscles, and thus to give rise to considerable pain; suitable laxatives must therefore be administered. Three or four weeks must elapse before sufficient union has occurred to enable the patient to be moved without pain, and it will be about eight weeks altogether before he can be allowed to sit up; after another two or three weeks he may be allowed to get about, at first with crutches, and later on with two sticks.

#### FRACTURES OF THE INDIVIDUAL BONES OF THE PELVIS.

**THE ILIUM.**—The alæ of the ilium are not uncommonly fractured by severe and localised direct violence; the fracture is generally limited to the false pelvis.

**Treatment.**—The patient should be placed in bed with the knees flexed and fastened over a pillow; it is not advisable here to apply a bandage as in the cases just described, because its pressure is apt to drive the



fragments inwards. A thick sandbag on either side of the pelvis with a sheet stretched over the abdomen will be sufficient to keep the parts properly at rest.

In about three weeks the patient may get up, using crutches at first, and afterwards getting about with the aid of a stick.

**THE ISCHIUM.**—The tuberosities of the ischium may be fractured, and the separated portion of bone is sometimes drawn downwards by the muscles attached to it. Often, however, there is little or no separation owing to the fact that the ligamentous structures in the neighbourhood are untoned.

**Treatment.**—If there be very little separation, an attempt may be made to obtain union by relaxing the muscles attached to the ischium; for this purpose the patient should lie on the opposite side with the thigh fully extended upon the pelvis and the knee flexed. As a rule, since union will be by fibrous tissue in these cases, it is better to cut down and expose the fracture and then to fix it with pegs or screws; this is certainly necessary in all those in which there is much separation.

**THE ACETABULUM.**—Either the lip of the acetabulum may be broken off, or the fracture may run through the centre of the cavity; it may sometimes be so extensive that the head of the femur passes in between the broken fragments and projects into the pelvis. The accident may result from a fall on the knee, and this form of violence generally leads to detachment of a portion of the upper and back part of the rim of the acetabulum; the result is that the head of the bone has a constant tendency to escape from the acetabulum and to slide upwards and backwards on to the dorsum of the ilium. Sometimes, however, it is due to a severe fall or blow upon the trochanter, which drives the head of the bone forcibly inwards against the bottom of the acetabulum, and then fracture takes place in that situation.

**Treatment.**—*When the rim of the acetabulum is chipped off*, extension (see p. 23) should be employed after the head of the bone has been manipulated into position; in adults a weight of six or eight pounds will generally suffice. It should be kept up for at least six weeks, while passive motion should be begun after about a fortnight and repeated daily. In these fractures extension by means of a long splint is seldom sufficient to prevent the head of the bone slipping out of position again.

*Fractures of the acetabular cavity* are very rare, and, being usually the result of very severe violence, are often complicated by fracture of the neck or the head of the femur, injury to the pelvis elsewhere, or damage to the pelvic organs. The exact condition of affairs is difficult to make out and a skiagram will often materially aid the diagnosis.

With the patient under an anæsthetic, an attempt should be made to disengage the head of the bone from the acetabulum; the upper end of the femur is pulled outwards by a band passed horizontally around the upper part of the thigh, and extension is also made in the long axis of the

limb. Then, by means of the finger in the rectum, the fragments may be manipulated into proper position. The limb must be put up with extension applied in two directions; this should be partly in the long axis of the limb and partly at right angles to the upper part of the thigh, so as to keep the head of the bone as far away from the bottom of the acetabulum as possible (see Fig. 38). Passive movement should be begun after the

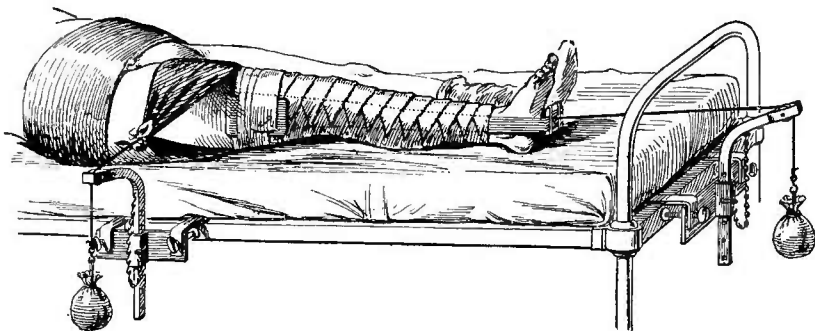


FIG. 38.—EXTENSION APPLIED FOR FRACTURE OF THE ACETABULUM. In addition to the ordinary weight extension from the foot, there is a second extension at right angles to the long axis of the limb through the agency of a sling passed transversely around the upper part of the thigh. Counter-extension is made by a broad towel around the pelvis fastened to the side of the bed opposite to that on which the pulley is. The foot of the bed is raised on blocks.

end of the first week, with the view of minimising the resulting stiffness of the hip joint; it is, however, very rare that an entirely useful joint is obtained after an injury of this kind.

#### FRACTURES OF THE SACRUM.

**CAUSES.**—On account of its great strength and its comparatively sheltered position the sacrum generally escapes injury, but fracture may occur from direct violence, such as kicks or blows, or a run-over accident when the patient is lying upon the face; as a rule the fracture takes place just above the sacro-coccygeal joint.

**COMPLICATIONS.**—This fracture is generally compound, communicating either with the skin or the rectum. In the latter case the injury is very grave, as septic infection is almost certain, and may lead to pelvic cellulitis of a very severe type. Damage to the sacral nerves may also occur, and may lead to paralysis of the sphincter ani and incontinence of fæces.

**DISPLACEMENT.**—The lower fragment, with the coccyx attached to it, is generally displaced forwards, and, even when there is no displacement immediately after the accident, the lower end tends to be tilted forward subsequently by the pull of the muscles attached to it. The fracture may unite in this bad position, and will then cause serious pressure upon the lower end of the rectum, interfering with the passage of its contents, and

often causing great pain and discomfort to the patient on sitting or walking—a condition generally spoken of as *coccydynia*.

**TREATMENT.**—The chief point in the treatment is to reduce the fragments, so that there shall be no tilting forwards of the lower end, and also to arrange that the bowels shall be kept quite quiet for some days. In the first place, therefore, it is well to wash out the rectum thoroughly with an enema. The finger is then introduced into the rectum, the lower fragment is grasped between it and the thumb externally, and by this means it may be manipulated properly into position. An enema of 20 minims of laudanum in half an ounce of starch is next administered, so as to prevent any further action of the bowels for four or five days. The patient should be instructed to assume the lateral or the prone position and not on any account to lie upon the back. Union usually occurs very satisfactorily if the fracture be simple, and at the end of about three weeks the patient may be allowed to get up; he should not be allowed to sit down until nearly six weeks have elapsed.

When the fracture is complicated by a wound of the skin and there is difficulty in preventing the tilting of the lower fragment, the ordinary treatment for compound fracture should be carried out, and it may be well to wire the two portions in position. These cases, however, often suppurate owing to the proximity of the wound to the anus, and it may be necessary to remove the wire after a time. The treatment of cases in which the rectum is wounded will be dealt with when we come to speak of injuries of that organ.

#### FRACTURES OF THE COCCYX.

**CAUSES.**—Fracture of the coccyx may occur from direct violence, such as falls in the sitting position, kicks or blows, etc. It sometimes occurs during parturition and closely resembles fracture of the sacrum. The bone may be broken at any part; usually the fracture is in the vicinity of the sacro-coccygeal joint. The fragment is always displaced forwards, and presses more or less upon the rectum, giving rise to a good deal of pain on sitting or standing—the condition known as *coccydynia*. This fracture is very often overlooked and the displacement is therefore not reduced, so that the fractured ends unite in faulty position and much pain and trouble result.

**TREATMENT.**—The treatment is much the same as that for fracture of the sacrum. The rectum should be emptied, an attempt made to bring the fragment into position by means of the finger in the rectum, and an enema of starch and laudanum given. Here, however, the tendency of the fragment to become displaced forwards is almost uncontrollable, and should it be found after replacing the bone several times that the fragment will not remain in position, it is best to cut down and either fix the coccyx by a wire, or, when only a small portion is

broken off, to excise it altogether, taking care to peel off the periosteum with the structures attached to it.

It is well, however, not to have recourse to operative measures until the effusion about the fracture has become absorbed and until the damage done to the structures at the time of the accident has had time to become more or less repaired. It is very likely that septic infection will occur in the wound as the result of its proximity to the anus, and in the damaged condition of the soft parts this might readily become very grave. Therefore for the first fortnight or three weeks persevering attempts should be made to replace the bone in position as often as it becomes displaced; if after that time it is obvious that they have failed, operative measures—through a median incision directly over the fragment—may be resorted to.

The steps of the operation are quite simple; the incision goes down to the bone at once, the periosteum and fibrous structures are peeled back with a rugine as completely as possible, the fragment is seized in forceps and removed with a few touches of the point of the knife. The wound is sutured, and it is well to fasten the dressing in position by means of collodion. Should septic infection occur, the stitches should be removed, a drainage tube inserted, and wet boracic dressings (see Part I., p. 48) applied.

## CHAPTER VI.

### FRACTURES OF THE FEMUR.

FRACTURES of this bone may be divided into those affecting the upper end, the lower end, and the shaft.

#### FRACTURES OF THE UPPER END OF THE FEMUR.

**Varieties.**—These are divided into those of the neck and those of the great trochanter. Fractures of the neck of the femur are again usually subdivided into the intra-capsular and the extra-capsular forms. In the intra-capsular fractures the line of fracture lies within the capsule of the joint, whilst in the extra-capsular forms it lies outside it. As a rule, however, the distinction between the two forms is not perfectly accurate, because the line of fracture is generally partly intra- and partly extra-capsular in its course; the fracture is therefore called intra- or extra-capsular according as the greater part of the line of fracture is within or without the capsule.

**INTRA-CAPSULAR FRACTURE.**—True intra-capsular fracture is comparatively rare, and most commonly occurs in old people in whom senile bone changes are very marked; the line of fracture is usually close to the head of the bone. In old subjects a process occurs termed osteoporosis in which the bone becomes more porous, fatty, and brittle than normal, and, in addition, changes also occur in the direction of the neck of the bone, which becomes more horizontal; for both these reasons fracture readily occurs.

The fracture is generally caused by a comparatively slight injury, such as a fall upon the knee or upon the trochanter. When it results from indirect violence, such as a fall upon the knee, there is no tendency to impaction; but when it follows falls or blows upon the trochanter, a certain amount of impaction is not uncommon, the neck of the bone being driven into the head. The impaction is, however, not usually permanent, and is insufficient to insure proper bony union.

**Displacement.**—The shaft of the femur with the outer part of the neck is generally drawn upwards, partly as a result of the force and partly by muscular contraction, and consequently there is always more or less shortening of the limb. In true intra-capsular fracture this shortening is usually slight, and rarely exceeds three-quarters of an inch at first. Later on, unless means be taken to prevent it, the shortening may become much more pronounced, owing to the contraction of the muscles and the gradual stretching of the capsule of the hip joint, which at first is the principal agent in preventing the bone from being drawn upwards to any extent. The shaft of the femur with the lower extremity is rotated markedly outwards, so that the foot is everted and lies with its outer border almost horizontal; in unimpacted fractures this is mainly due to the weight of the limb, but it is also probably due in part to the fact that more extensive crushing of the bone takes place on the posterior aspect of the neck than on the anterior, because the same eversion occurs in impacted fractures and in them of course the weight of the limb cannot produce much effect as long as the impaction holds.

**Treatment.**—Two important points must be borne in mind. The first is that the fracture, if it occurs in old people as it usually does, often fails to unite by bone, although this is not always the case if prolonged treatment be carried out. The second is that in old people a long period of recumbency after any injury may prove serious and indeed often fatal from the occurrence of hypostatic pneumonia.

If the patient be comparatively young and strong, it may be worth while making an attempt to obtain either bony or at least firm fibrous union between the fragments; if, on the other hand, the patient be advanced in years, the chances of being able safely to keep him recumbent long enough are comparatively slight, and it is not worth while running the risk of the onset of pneumonia by persevering in attempts to obtain bony union. This question of union will also be further affected by whether or not the fracture be impacted; if it is, the surgeon will be much more inclined to persevere in attempts to obtain bony union than if it is not.

(a) **In young adults.**—**In unimpacted fractures.**—When there is a fracture without impaction in a comparatively young and vigorous subject the best treatment is as follows. The patient must be placed flat upon the back in bed with fracture boards beneath the mattress, and the latter should be so arranged that there is the least possible disturbance involved in the action of the bowels, etc.; the divided mattress (see p. 104) may be usefully employed for this purpose. When, after prolonged confinement to bed, the skin shows a tendency to become the seat of bed-sore, a suitable ring-pad or water-pillow should be placed beneath the pelvis, but this is best avoided in the earlier stages of the treatment, as the body is kept steadier without it. All the ordinary precautions against bed-sore must be rigorously observed (see Part I., p. 66).

**Extension.**—Traction should be made upon the fractured limb until

measurements show that it is the same length as the sound one; this extension should be kept up by means of a weight and pulley applied in the usual manner, the strapping being carried quite half-way up the thigh so as to prevent undue traction upon the ligaments of the knee joint. The foot of the bed is raised upon blocks so as to provide counter-extension, and a weight of from four to eight pounds is employed. The exact weight is determined by measurements of the limb and by the patient's sensation; some patients cannot bear a heavy weight, and in addition to this, the skin may be so tender that ulceration easily occurs from the traction upon the strapping. The point of importance is that only such a weight should be employed as is necessary to make the two limbs of equal length. The measurements should be taken from the anterior superior spine of the ilium to either the tubercle of the tibia or the internal malleolus, and it is well to mark these spots upon the skin with an aniline pencil or nitrate of silver at the commencement of the treatment so as to be sure of always taking the measurements from the same points. Care must be taken to place a small pillow beneath the leg just above the heel to prevent the possibility of a pressure sore where the heel would otherwise rest upon the mattress.

*Liston's long splint.*—Two points still remain to be attended to in the treatment. The first is to overcome the eversion of the foot and prevent

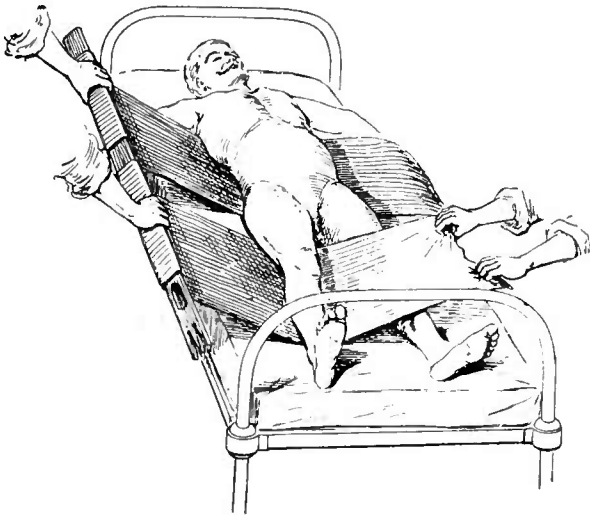


FIG. 30.—LISTON'S LONG SPLINT. *Method of application.* The splint is first rolled up for a few turns in one end of each of the broad bandages or sheets. The latter are then arranged as in the figure, the upper one beneath the trunk and pelvis, which keeps it steady, and the lower beneath the affected limb, where it is held firm by an assistant. The splint is then further rolled up in the bandages until it lies against the side of the body, when pads are inserted and it is secured as shown in the following figure. For the cases referred to in the text a stirrup should be applied to the affected limb before the procedures depicted above are carried out.

its recurrence, and the second is to keep the patient in the strictly horizontal position. A common method of effecting both these objects by

one apparatus is to employ a long Liston's splint which in these cases is used without any perineal band. The splint is most comfortably applied in the following manner. A sheet is taken and folded so that its width is equal to the distance from the perineum to the heel. A second sheet or piece of stout flannel of a width equal to the distance from the axilla to the iliac crest is also taken. The long splint is laid upon one end of each of these folded sheets, which are arranged so that they will be in proper position when the splint is applied, and the latter is rolled up in them for three or four turns so as to fix them firmly (see Fig. 39); the free end of the upper sheet is then passed beneath the trunk and that of the lower one around the lower extremity. The limb is brought into the corrected position by traction and slight abduction, and the splint,—which should reach from the axilla to well below the sole of the foot,—is then applied, pads being inserted between the splint and the limb where necessary. The upper sheet is now brought around the chest and fastened to the

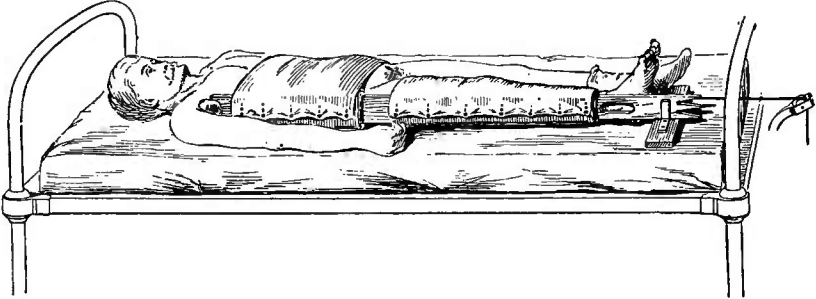


FIG. 40.—LISTON'S LONG SPLINT. *The splint applied.* After the splint has been put in position the free end of the upper sheet is brought around the thorax and pinned to the portion rolled up around the splint as shown above. The lower sheet is brought around the extremity and similarly fastened. The slot for preventing rotation is shown at the lower end of the splint, and the extension apparatus is also indicated. The lower extremity is slightly abducted.

splint by means of long blanket pins, while the lower one is wound around the lower extremity and the splint so as to fasten the two firmly together, and is similarly pinned to the splint. In addition to this it is necessary to adopt some means to prevent recurrence of the eversion; the best plan is to take a flat piece of wood which rests upon the mattress and upon which are fixed two rectangular iron brackets, one on either side, forming a slot into which the lower end of the splint is received, and in which it is free to slide horizontally, but is unable to rotate (see Fig. 40).

*After-treatment.*—When an attempt is to be made to obtain bony union, this apparatus should be kept on for ten or twelve weeks; the period of six weeks for which a fracture is usually kept up is much too short for intra-capsular cases. During this prolonged treatment it is necessary to see that bed-sores do not occur, that the patient is kept absolutely quiet, and that there is no irritation or ulceration of the skin from the extension apparatus.



*Thomas's hip splint.*—At the end of ten or twelve weeks the hip joint should be fixed by means of a Thomas's hip splint (see Fig. 41), and the patient may then be allowed to get about upon crutches which should be used for at least two or three months before he puts the foot to the ground. If prolonged treatment of this kind be adopted, the union, even though it be fibrous, will gradually become so firm that the patient is able to support a considerable part of the weight upon the injured limb.

**In impacted fractures.**—Here the long splint alone is often sufficient, but, as the impaction in these intra-capsular cases is often extremely slight, amounting sometimes to a mere entanglement of irregular fragments, it is

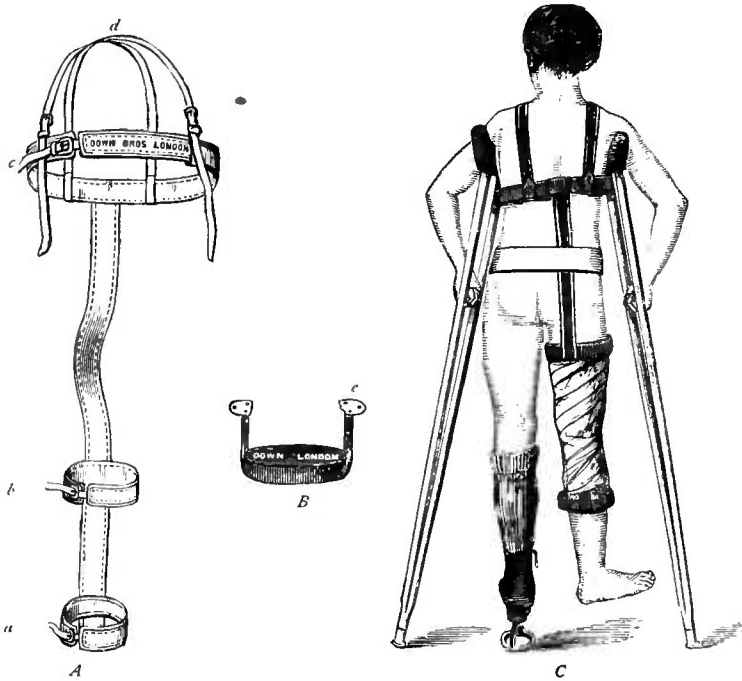


FIG. 41.—THOMAS'S HIP SPLINT. *A* shows the splint previous to use; the wings *a* surround the leg just below the knee, while those at *b* enclose the thigh just above it. The stout metal band *c* encircles the chest, and the splint is kept in place partly by bandages and partly by the braces *d*. *B* is the patten fastened to the boot on the sound side by the screw-plates *e*. The apparatus is shown applied in *C*, with the patient walking on crutches.

as well to employ extension, at any rate after the end of the first ten days. It will not be necessary to use nearly as much weight as when the fracture is unimpacted; otherwise the impaction might easily be broken up. Two or three pounds usually suffice.

**(b) In elderly and feeble subjects.**—**Palliative.**—In these patients it is not advisable to attempt to obtain bony, or even in many cases firm fibrous union. The patient should at first be kept in the recumbent position for a short time; sometimes he can be kept lying on his back for ten

days or a fortnight, sometimes as long as three weeks, and the same arrangement as that already described, namely, extension and the use of the long splint (see p. 111), should be employed.

*Thomas's hip splint.*—In the meanwhile the greatest care must be taken to ascertain the condition of the circulatory and respiratory organs, and, as soon as it is seen that the patient is beginning to suffer from the effects of the prolonged recumbency, the apparatus must be given up and the patient allowed to resume the erect position and if possible to get about. Two forms of apparatus may be used with this object. In women especially a Thomas's splint will answer the purpose satisfactorily. An ordinary Thomas's hip splint with the vertical bar along the back of the limb will prevent friction and its accompanying pain and will enable the patient to get about on crutches or at any rate to stand or to assume the reclining or semi-recumbent position.

*Plaster spica.*—In men the plaster of Paris spica bandage is useful; it is put on as follows. The patient stands on the sound limb upon a block high enough to raise the affected limb well off the floor. After the perineum and the groins have been thoroughly powdered, a spica of boracic lint or ordinary flannel is applied to the affected limb, reaching from the upper third of the leg to well above the crest of the ilium. Over this the plaster of Paris bandages are applied; for the methods of preparing these see p. 22. The bandages should be 4 inches wide and are immersed in cold water; when thoroughly soaked they are applied loosely and evenly from below upwards. The bandage may be strengthened from time to time by smearing a quantity of the plaster over it with the hand.

The weak point in this bandage is always opposite the fold of the groin; this should be strengthened by incorporating in the dressing strips of block tin or thin malleable iron placed across the fold of the groin at right angles to Poupart's ligament and in a corresponding situation behind. If these be not at hand, strands of tow teased out and steeped in plaster may be used in a similar manner. The apparatus should be sufficiently firm not to crack when weight is borne upon it and as light as is consistent with this. It must be allowed to dry thoroughly before any weight is borne upon it; with this object the patient may lie in the horizontal position before a fire for some hours. It is much more satisfactory to apply the apparatus when the patient is erect, as the weight of the limb then acts as an extending force; if however it has to be put on while the patient lies in bed, extension by weight and pulley or by an assistant must be maintained. When the plaster has set, a boot with a high heel or a patten (see Fig. 41, *B*) is worn upon the sound limb and the patient is allowed to get about on crutches, the toes of the affected limb being slung by a long strip of bandage passing round the neck and beneath the instep.

The plaster spica is an especially useful splint because it allows the patient to bend the lumbar spine and so he can be propped up well in bed; the risk of lung complications is thus minimised. The casing

may require renewal from time to time and should be worn for three or four months; it may then be abandoned and a Thomas's splint substituted for another two or three months. Fairly firm union may be obtained by this method.

**Operative.**—The question of operative interference in these cases has been a good deal discussed. The patient is usually too old and feeble to undergo what must necessarily be a fairly severe operation, and, in addition to this, the bone is generally so much atrophied that the chances of getting a good result are somewhat small. When, however, the fracture occurs in a patient who is comparatively young (45-55) and still vigorous, operation may be justifiable. In one case of this kind where the fracture was, as far as could be judged, essentially intra-capsular, we have operated with very considerable success; the description of this operation may be taken as a model for those under similar conditions. Extension by weight and pulley was made upon the limb under an anæsthetic until the two limbs were of the same length. The femur was then rotated firmly inwards and the parts manipulated until the fragments seemed in position. A vertical incision was then made over the outer surface of the great trochanter right down to the bone and a drill driven through the trochanter and along the neck of the bone until it penetrated well into the head of the femur. The distance the drill was made to penetrate was guided by measurements on the sound side. The drill was then withdrawn and a square ivory peg fitting the hole exactly was driven in, cut short, and the wound closed. A long Liston's splint was then put on and weight extension applied.

*After-treatment.*—The wound healed by first intention, the splint was left off in six weeks and for the next month the patient was encouraged to move the hip as she lay in bed without being allowed to bear weight upon it. The result was a perfectly useful limb, the only fault to be found with it being a shortening of about half an inch. Probably the peg had allowed the trochanter to be drawn up, and if we had to do a similar operation again we should be inclined to put in two pegs at a little distance from each other.

**EXTRA-CAPSULAR FRACTURE.**—By the term extra-capsular fracture of the neck of the femur is understood one in which the line of fracture is, partly at any rate, outside the capsule. As a rule, the so-called extra-capsular fracture is intra-capsular in front and extra-capsular behind, owing to the fact that the capsule in front is attached to the lowest limit of the neck.

**Causes.**—This injury is caused by more severe violence than that producing the intra-capsular fracture and is generally due to a heavy fall on the great trochanter; impaction very frequently occurs, the neck of the femur being driven outwards into the trochanter, which it often splits up considerably. The injury may also occur from indirect violence, such as falls from a height upon the feet or knees, but in these cases the shaft of

the femur is more likely to give way. The fracture occurs in younger people than does the former variety and it generally unites by bone; on account of the age of the patient there is less liability to lung complications than there is in the intra-capsular fractures.

**Displacement.**—There is generally shortening, even when the fracture is impacted; as much as from two and a half to three inches may be met with. The limb is strongly everted whether impaction be present or not. In impacted cases there is very marked broadening of the trochanter—a point of considerable importance in the diagnosis.

**Treatment.**—With one or two points of difference the treatment closely resembles that for intra-capsular fracture. In the first place, the aim in all these cases is to obtain bony union, and therefore a much more

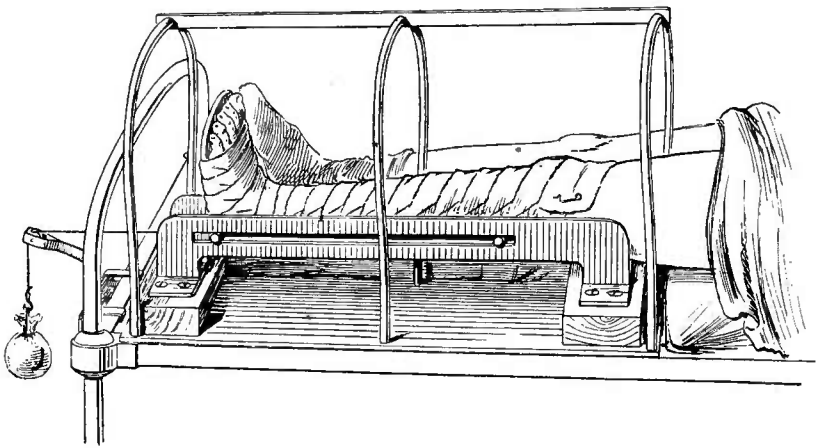


FIG. 42.—EXTENSION APPARATUS FOR FRACTURE OF THE NECK OF THE FEMUR. The leg is fixed to a back splint which slides in the iron frame shown above. This serves to prevent rotation while securing extension with very slight friction.

prolonged treatment is advisable; this is usually well borne, since the patients are younger and more vigorous and do not run the same risk of either bed-sore or pneumonia as do the victims of intra-capsular fracture. In the second place, greater extension is required to bring the fractured ends into position, because there is nothing to oppose the upward pull of the muscles. The treatment will vary according as the fracture is or is not impacted.

**Of unimpacted fracture.**—The limb should be shaved and extension strapping applied from the middle of the thigh to about the middle of the leg (see p. 24); the bandage securing it should not extend as low as the malleoli, because heavy weights have to be employed which may cause the strapping to slip and produce a sore about the ankle. After the strapping has been applied, the patient should be anæsthetised and, while an assistant makes counter-extension, the limb is dragged down into position by traction upon the foot and ankle; it is kept in position by

attaching a suitable weight to the cord passing over the pulley; this will vary according to the muscularity of the patient. In an adult it is best to begin with six or seven pounds, and to increase it later if necessary.

The outward rotation of the limb will also have to be corrected, and this is much more difficult to do than in the intra-capsular fracture, because any efficient arrangement is likely to cause so much friction that extension is interfered with. A good though somewhat complicated apparatus is shown in Fig. 42; the foot and lower part of the leg are put up on a posterior splint with a foot-piece at right angles, and this is so arranged that it runs in a groove in an iron frame standing upon the bed; rotation of the limb is thus prevented without undue friction. This apparatus is however not easily obtainable, and the following more simple method

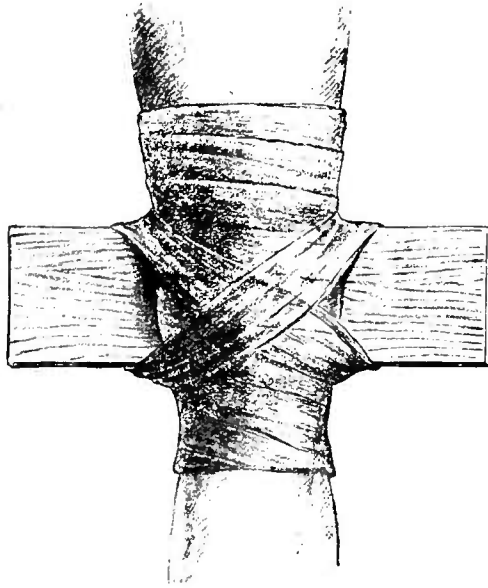


FIG. 43.—METHOD OF PREVENTING ROTATION DURING WEIGHT EXTENSION FOR FRACTURE OF THE FEMUR. A plaster of Paris bandage is applied to the knee and made to include a piece of board placed behind the limb as shown in the figure.

may be tried. A piece of wood three inches wide and nine inches long is placed behind the knee so that it projects beyond it on each side, and is then fastened firmly to the limb by a plaster of Paris bandage after the rotation has been corrected (see Fig. 43). This is a better apparatus than the long Liston with the transverse bar, which is often used for the same purpose, as it does not interfere so much with the extension.

Another point of great importance is to fix the body so that the patient cannot move the hip joint, as otherwise movement will of course occur at the seat of fracture, and union may be interfered with. This is best done by applying a long Liston to the sound side; in addition, a sheet kept in position by sandbags on either side may be placed across the trunk.

The splint is put on the sound side so that it shall not interfere with extension of the fractured limb; undue pressure over the damaged trochanter is also thereby avoided. When the patient is not restless, the same result may be obtained by simply using a broad sheet over the thorax kept in position by heavy sandbags rolled up into the edge of the sheet at either side.

*After-treatment.*—The patient should be kept absolutely at rest in the horizontal position for at least six weeks. The fracture should then be examined, and if a fair amount of union has occurred the best plan is to apply a Thomas's hip splint, which may be fastened on with plaster of Paris bandages; the patient may then be allowed to get up and go about on crutches. The Thomas's splint should be worn for another six weeks, when the fracture will in all probability be quite firm. After these fractures have united there is often considerable difficulty in obtaining free movement of the hip joint. This is due either to adhesions in the capsule or to masses of bone or callus thrown out around the fracture as a result of the damage to the trochanter. The adhesions in the joint may be overcome by massage and active and passive movements, but if the movement be interfered with by bony outgrowths, it may be necessary to cut down over the trochanter and chisel away any portions of bone that interfere with the free mobility of the joint.

**Pegging.**—In some cases of extra-capsular fracture it may be advisable to peg the fragments together in the manner described in dealing with intra-capsular fracture. We have not ourselves carried out this method of treatment, but when there is difficulty in keeping the patient quiet, when the fragments cannot be properly kept in position, or when the skin is so tender that it will not bear efficient weight-extension, the operation would undoubtedly be called for, and a couple of pegs driven in through the trochanter would in all probability fix the fragments in excellent position and ensure good union. Certainly the method is one which it is well to bear in mind; the steps of the operation would be those already described for intra-capsular fracture (see p. 115).

**Of impacted fracture.**—When the fracture is impacted it is not advisable to break up the impaction unless there be great deformity. All that is necessary is to keep the limb at rest until bony union occurs; this generally takes place rapidly. Breaking up the impaction is a matter of difficulty, and it does not necessarily follow that there would be less deformity than if the case had been left alone, while it might result in mere fibrous union. In impacted fractures it is unnecessary to employ extension; the impaction is generally very firm, the neck of the femur being wedged into the great trochanter, and the parts can be efficiently immobilised by a long Liston's splint applied in the manner already described, without a perineal band. The patient should be kept at rest for six or eight weeks, and for three or four weeks afterwards should not be allowed to bear weight upon the limb. It is in these cases of

impacted fracture, where the impaction has not been reduced, that bony prominences interfering with subsequent movement are chiefly met with, and in these cases therefore the surgeon may find it necessary to cut down and chisel away the obstructing portions of bone.

**FRACTURES OF THE GREAT TROCHANTER.**—The great trochanter is sometimes broken off without any solution of continuity occurring between the shaft of the femur and the neck; this accident however, is of great rarity.

**Displacement.**—The detached portion is carried upwards and backwards by the muscles attached to it, and if the fibrous structures be entirely torn through, the separation may be marked; it may then be very difficult to bring the fragment into position by any means short of an operation.

**Treatment.**—The most satisfactory method is to make a curved incision of suitable size with its convexity forwards over the great trochanter, and thus to raise a flap which is thrown backwards and exposes the fractured process; this is pulled into position, the limb fully abducted so as to relax the glutei, and the fragment secured in position by one or two screws or pegs (see p. 51). The wound is closed and the limb put up in a position of abduction; it can be retained in position by sandbags, whilst a long splint is applied to the sound side so as to prevent movement of the trunk.

The sandbags may be discarded when the wound has healed, and the limb is then put up in a firm plaster of Paris spica in the abducted position. The patient should be kept horizontal for about six weeks and may then be allowed to bear weight upon the limb. There is usually no difficulty in obtaining a perfectly useful limb.

#### FRACTURES OF THE SHAFT OF THE FEMUR.

**Causes.**—The shaft of the bone may be fractured in any situation, the most common being just above the centre; fracture may be due either to direct or indirect violence. When due to direct injury the line of fracture is generally more or less transverse, whilst that resulting from indirect violence, such as a fall upon the knee or the foot, is generally oblique or somewhat spiral.

**Displacement.**—The displacement varies according to the situation and obliquity of the fracture.

**In fractures just below the lesser trochanter.**—In fractures situated high up in the shaft, just below the lesser trochanter, the upper fragment is generally tilted forward, and at the same time rotated outwards and somewhat abducted by the pull of the psoas and iliacus. The lower fragment is drawn upwards behind the upper fragment and usually also slightly inwards by the adductors: it is markedly rotated outwards owing to the weight of the limb.

**In fractures near the centre of the shaft.**—When the fracture is lower down in the shaft there is still some tendency to pulling forward of the upper fragment, although it is not nearly so marked as in the form just described. The lower fragment is drawn upwards and backwards, its upper end being behind and rather to the outer side of the lower; this gives a well marked bowing forwards and outwards of the thigh. There is generally considerable shortening.

**Treatment.**—**Of fracture just below the trochanters.**—In this fracture it is somewhat difficult to obtain a good result because the

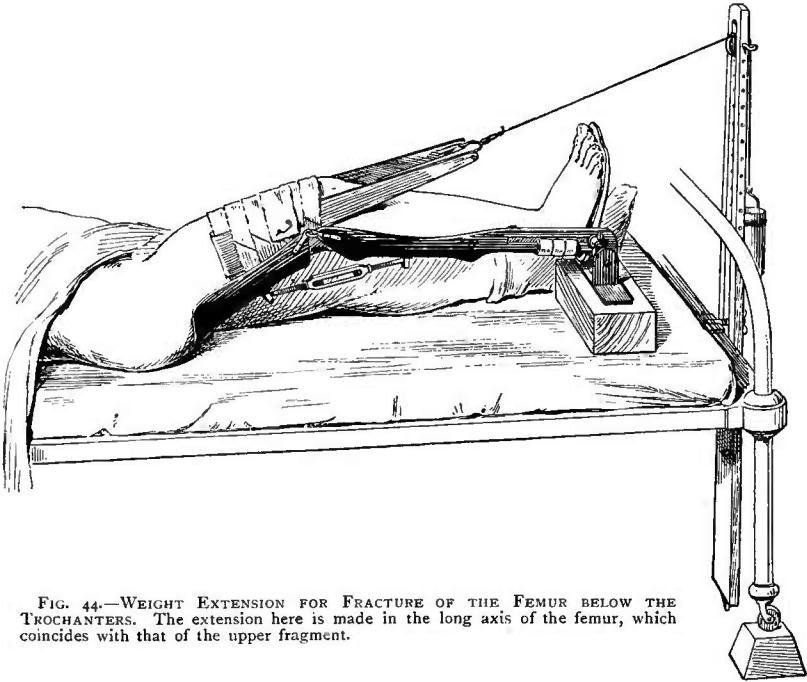


FIG. 44.—WEIGHT EXTENSION FOR FRACTURE OF THE FEMUR BELOW THE TROCHANTERS. The extension here is made in the long axis of the femur, which coincides with that of the upper fragment.

displacement of the short upper fragment cannot be overcome by traction; the lower fragment must therefore be brought into a line with the upper. To do this, the thigh is flexed until the axis of the lower fragment coincides with that of the upper; on account of the abducted position and the external rotation of the latter, the lower fragment should be also abducted and rotated slightly outwards. This position may be maintained by placing the limb upon a Macintyre's splint directed somewhat away from the middle line, bent at the knee, and raised sufficiently to bring the fragments into proper line. The leg is made to lie with the foot somewhat everted on the splint. Strapping is then applied to the thigh from immediately below the fracture to just above the knee, and from this a cord is carried over a pulley attached to the bed at a suitable height, and a weight of five or six pounds is fastened to it (see Fig. 44).



*Hodgen's splint.*—Another and more satisfactory method is the use of Hodgen's splint (see Fig. 45). This is applied as follows:—A stirrup is applied to the limb (see p. 24), and the wire frame, of a size suitable for the particular case, is converted into a form of sling for the reception of the injured limb; this is done by fastening strips of stout flannel of suitable length and about three or four inches in width to one side of the frame; the latter is then placed in position over the limb and converted into a sling by bringing each strip of flannel in succession round beneath the limb and fastening the free end to the opposite side of the frame, in which

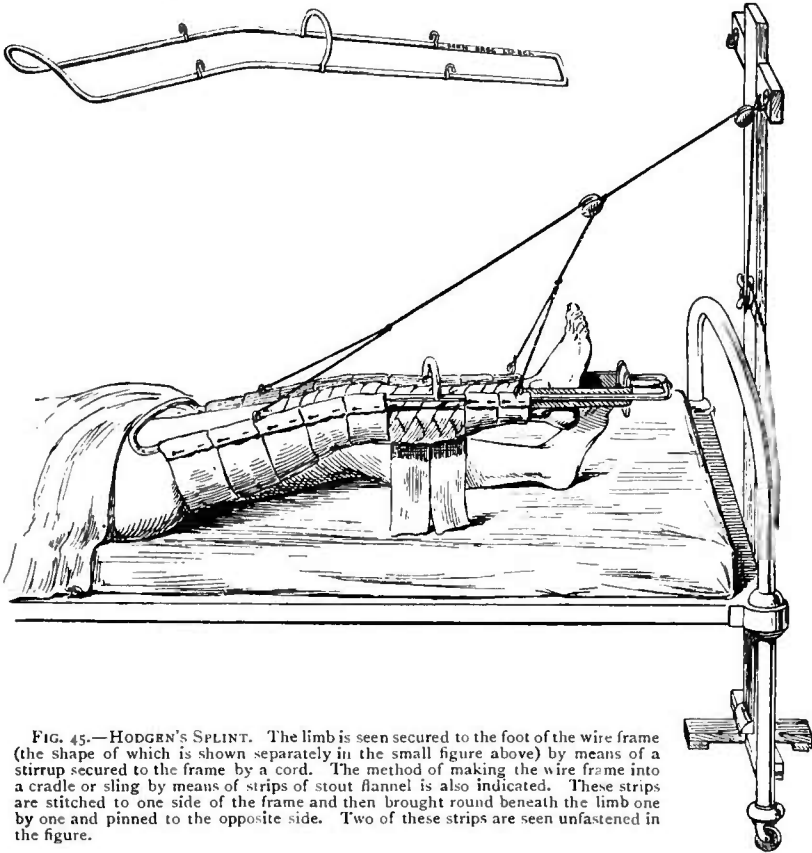


FIG. 45.—HODGEN'S SPLINT. The limb is seen secured to the foot of the wire frame (the shape of which is shown separately in the small figure above) by means of a stirrup secured to the frame by a cord. The method of making the wire frame into a cradle or sling by means of strips of stout flannel is also indicated. These strips are stitched to one side of the frame and then brought round beneath the limb one by one and pinned to the opposite side. Two of these strips are seen unfastened in the figure.

the limb thus lies comfortably. The upper and outer extremity of the wire frame should lie over the anterior superior iliac spine, while the upper and inner end is well up in the fold of the groin. The limb is fastened to the foot of the frame by a cord passing from the stirrup; the fracture is then carefully reduced and extension maintained by raising the whole splint with the limb in it, and suspending it by means of properly arranged cords to an upright at the foot of the bed, which is so arranged that the limb is somewhat abducted and rotated outwards.

Hodgen's splint acts by producing extension upon the thigh in the semi-flexed position, the extending force being the weight of the limb. It is only necessary to raise the limb sufficiently for it to be well clear of the bed. If increased extension be required, it is not made by pulling the limb up higher but by adding weight to the metal frame and so increasing the weight of the limb.

This splint gives very good results, and is much more comfortable than any other; the patient can to a certain extent move about in bed, as the splint follows any movement of the body, and he is able to raise himself into the semi-recumbent position without unduly disturbing the fracture. It is the splint most particularly adapted for fractures immediately below the lesser trochanter. It should be kept on for about six or eight weeks, when the patient should have a plaster of Paris spica applied and may be allowed to get about on crutches (see p. 114); at the end of three or four weeks longer he will probably be able to manage with two sticks.

**Of fracture near the centre of the shaft.—In adults.**—In an adult with strong muscles as much as twelve or fourteen pounds is sometimes necessary to maintain extension after reduction; the following is a good arrangement. The limb is placed in the horizontal position upon the bed and a stirrup is applied, the strapping extending from above the knee to a little distance above the ankle (see p. 24); from the stirrup a cord passes over a pulley. Counter-extension is then provided for by a well-padded perineal band fastened to the head of the bed, the foot of which is raised on blocks, and a weight of seven or eight pounds is attached to the cord. In the course of two or three days this may be increased if necessary up to twelve or fourteen pounds; sometimes even more than this is required. The limb should be kept parallel with the middle line and eversion of the foot must be corrected, because in these cases the upper fragment is not markedly abducted or rotated outwards. Eversion is best prevented by the means recommended on page 117. The question of abduction or rotation outwards of the upper fragment is easily determined by noting the direction of the outer surface of the great trochanter; the position of the lower fragment must be arranged accordingly.

Sometimes cases are met with in which there is marked tilting forwards of the upper fragment; this may be overcome by means of a shield of plaster of Paris applied over the front of the limb so as to press the fragment back into position. It is made on the principle of a Croft's splint, an anterior piece only, broad enough to cover the whole of the front of the limb, being used. This splint is plentifully smeared with plaster so as to increase its weight, and if necessary the pressure on the fragment may be increased by moulding sheet lead to the shape of the splint, over which it is applied (see Fig. 46). When combined with extension this is often very efficacious. If the patient be very restless, it may be necessary in addition to put on a long Liston's splint, so as to prevent undue move-

ment of the fragments; this should never be resorted to, however, unless it be absolutely necessary, as it materially interferes with the extension, and heavier weights must be employed if it be used.

It is well to take a skiagram a day or two after the injury, in order to see the position of the fragments, and the amount of shortening should be ascertained by careful measurement. Some little shortening is almost inevitable, but should it exceed half an inch, the weight extension must be increased. When heavy weights have to be employed, the strapping applied to the thigh often slips and may give rise to troublesome ulceration; the best plan to obviate this is to put up the leg and foot in lateral poroplastic or Croft's splints reaching above the knee, and then to attach the extension to this. A still simpler method is to fasten the extension to a boot; very powerful extension indeed can be then applied without fear of its slipping or causing ulceration. Of course, if the weight necessary to produce effectual extension be so great as to cause pain from undue stretching of the ligaments of the knee, this method is useless; an attempt may then be

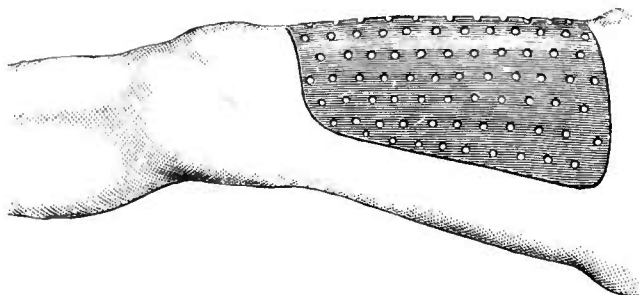


FIG. 46.—METAL SPLINT FOR FRACTURE OF THE SHAFT OF THE FEMUR. This splint may usefully be employed to press down the upper fragment in place of, or in addition to, the plaster of Paris shield, which it closely resembles in shape. Extra weight can easily be added by moulding a sheet of lead outside the splint. This splint is used in addition to the weight-extension.

made to keep the fragments in position by means of a Hodgen's splint, and if that fails it may be necessary to have recourse to operative interference.

*Operative methods.*—If after a few days there be marked shortening, and if a skiagram shows considerable displacement of the fragments, the best plan undoubtedly is to cut down and fix the fracture. This is rarely required, but it may be necessary when the patient is unable to bear extension, or when there is such extreme restlessness that it is impossible to keep the fragments in apposition in any other way.

The incision should generally be made rather to the outer side of the limb; this, however, is not an invariable rule, the essential point being not to cut down upon the line of fracture, but to expose the front of one of the fragments, usually the upper one. If the line of fracture only be exposed it will be necessary to detach the soft parts very widely in order to get round to the front of the fragment and to insert screws or

pegs. This is an unnecessary disturbance of parts, because in recent fractures there is usually nothing between the fragments requiring removal, and all that is necessary is to expose the surface of the bone sufficiently, get the fragments into position, and then to insert a couple of square ivory pegs or suitable screws; this operation has already been described (see p. 51). During and after this mechanical fixation the limb must of course be most carefully steadied; the immobilisation must be maintained while the wound is stitched up, the dressings applied, and the splints put on. The best splints to use for this purpose are four short Gooch's splints, which can be folded accurately round the limb; if preferred, a Croft's plaster case may be employed. At the same time a long outside splint should be put on, and it is well to employ a certain amount of extension for the first week or ten days so as to steady the muscles and hinder them from loosening the screws; four or five pounds is usually quite sufficient. These fractures require from eight to ten weeks for thorough union.

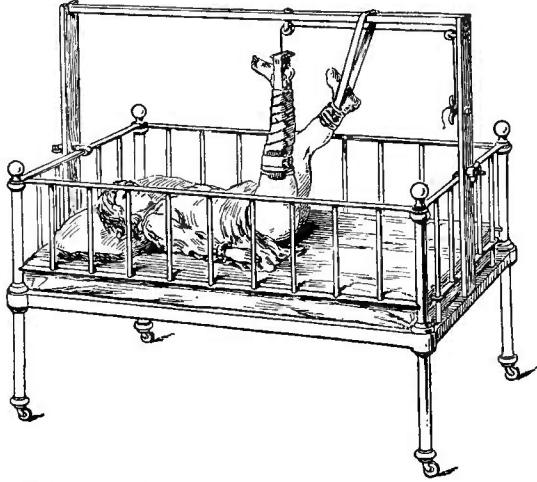


FIG. 47.—VERTICAL EXTENSION FOR FRACTURED FEMUR IN CHILDREN. The affected limb is vertical, while the sound one is merely looped up to the bar in order to keep it well off the bed. No splints are required.

**In children.**—In very young children it is extremely difficult to treat these fractures satisfactorily with the limb in the horizontal position. The chief objection is that any apparatus rapidly gets soiled and requires changing. The smallness of the limb also renders it very difficult to secure a splint properly, and therefore the fracture does not remain at rest. Even plaster of Paris and silicate casings are open to the same objection, for, although they fix the limb fairly well, they readily get soiled, and become soft and useless, while the skin is irritated and may ulcerate.

*Vertical extension.*—In all children under five years of age it is best

to suspend the fractured limb in the vertical position at right angles to the trunk, as proposed by Mr. Bryant; all discharges then pass backwards, there is no possibility of the apparatus becoming soiled, and it is quite easy to keep up efficient extension. A stirrup is applied to the affected limb extending as high as the lower part of the thigh, and to this a cord is fastened which is attached to a bar arranged above the cot or bed, directly over the pelvis, and running between two uprights, one at either end of the bed, of sufficient height to allow of the limb being extended (see Fig. 47). The affected limb should be drawn up so that the buttocks are just clear of the bed, and it is well also to suspend the sound limb to the bar, so that it is impossible for the child to put it on the bed; otherwise he might support the weight of the pelvis upon the sound limb and so nullify the extension. The sound limb should however only be raised sufficiently for this purpose, and no actual extension should be applied to it. Under no circumstances should both limbs be fastened to the same back splint, and vertical extension then be applied, as is sometimes recommended. In this method the weight of the pelvis acts as a constantly extending force; there is no necessity to apply any splint, as the child keeps still, and the result is all that could be wished for.

*Bryant's double splint.*—In children over the age of five the best splint is perhaps that known as Bryant's. It consists of two long parallel outside splints with bracketted interruptions opposite the trochanter, and connected above and below by adjustable metal bars, which allow for the

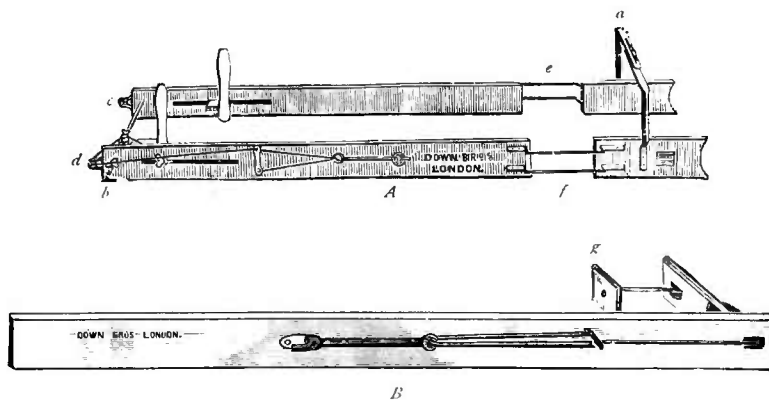


FIG. 48.—THE DOUBLE SPLINT FOR FRACTURE OF THE FEMUR. *A* shows the form originally suggested by Mr. Bryant. The lateral splints can be approximated or separated by the metal bars at *a* and *b*. The sound limb is fastened to the footpiece on the side *c*, while the fractured one is secured to *d*, upon which the extension acts; *e* and *f* are interruptions in the splint opposite the trochanter to allow the limbs to be kept parallel. In *B* is shown the detail of the lower part of one side splint in which extension is made by means of a stirrup which is attached to the piece of wood *g*. This gives more effectual extension, as it cannot jam, as does the footpiece running in a slot.

separation or approximation of the splints according to the size of the patient. The sound limb is fastened firmly to the splint by strapping or handages, while to the injured limb extension is applied, preferably by means of a

stirrup,<sup>1</sup> the cord passing round a pulley at the foot of the splint and being fastened to an elastic door-spring (see Fig. 48, *A*), by which the requisite amount of extension can be made. The trunk is secured by a broad bandage or folded sheet passed around the upper part of the splint. This splint has the advantage that it facilitates nursing arrangements, as the child is able to be turned over, carried about, or wheeled out in the air without disturbing the fracture.

**Mal-union.**—In fractures of the femur it is not uncommon to meet with both mal-union and non-union. In the former case there is generally angular deformity with the apex directed outwards and forwards, and considerable shortening. The bone may either be re-fractured or may be cut down upon and secured in position, the latter being the preferable method, the operation of course being done aseptically.

**Operation.**—After the limb has been shaved and disinfected, a vertical incision is made over the fracture, generally along the outer side of the limb; this incision should be very free,

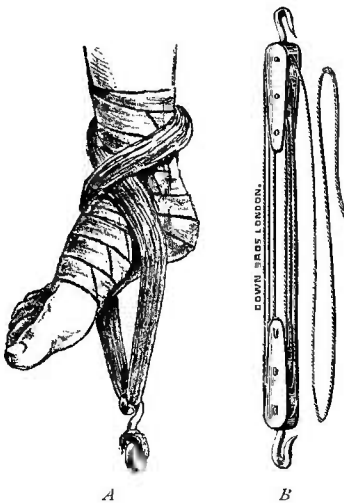


FIG. 49.—METHOD OF ATTACHING PULLEYS TO THE LOWER EXTREMITY. *A*. The skein of worsted is passed round the ankle as shown above; the ankle has been previously bandaged, to prevent abrasion. The whole is then wetted, and a wet bandage is applied outside the skein of worsted to prevent it slipping, when the powerful pulleys *B* are attached to the loop below the sole.

for if it be too small, the soft parts will be severely bruised in manipulating the bone ends, and this may interfere with the healing. After everything has been cleanly divided down to the fracture, the parts are well retracted and the faulty union is freely exposed. In nearly all these cases the fracture is oblique, and the line of union should be chiselled through until the fragments are completely separated. The periosteum should not be peeled off except in the immediate vicinity of the bone section. Powerful extension must next be applied in order to bring the fragments into position; it is generally necessary to employ pulleys, as the traction that can be exerted by even the strongest assistant is not sufficient. Before employing the pulleys a stout skein of worsted should be passed behind the ankle, crossed over the dorsum

of the foot (see Fig. 49), and bandaged on with a wet bandage to prevent the loop slipping; its end is then attached to the hook of the pulley. An assistant now makes traction upon the pulley, whilst counter-extension is

<sup>1</sup>In the double Bryant's splint as originally designed and still supplied by instrument makers, the affected limb is fixed to a foot-piece running in a slot in the lateral splint, and acted upon by the elastic door-spring. This is quite ineffectual in practice, as the foot-piece always jams in the slot and will not slide; a stirrup is much better (see Fig. 48, *B*).

provided for by a perineal band fastened to a hook in the wall or the head of the table. As the extension is made, the tissues in the region of the fracture become very tense and should be divided one by one as they are put on the stretch, so long of course as they are merely periosteal, fibrous or muscular; it is important to see that no large vessel or nerve is divided. After steady extension has been thus applied for some time, sufficient elongation of the limb can be obtained to bring the fractured ends into proper apposition. Then the cords of the pulley are fastened so as to maintain extension, whilst any projecting portions of bone are removed by a chisel, and a well-fitting fresh bony surface is prepared on each fragment; it is a very good plan to so shape the ends of the bones that when fastened together they will more or less interlock and so resist the tendency of the muscles to displace them (see Fig. 50). The bones are then firmly fixed together by means of two plated screws of suitable size (see p. 51). The wound is sewn up without a drainage tube, cyanide dressings applied and the thigh surrounded by four short Gooch's splints. Outside these a long Liston's splint may be fixed temporarily so as to immobilise the limb while the patient is being moved back to bed. The pulley is then removed, the patient put back to bed, and the limb steadied between sandbags, while an extension of three or four pounds is applied to counterbalance the traction of the muscles for the first ten days.

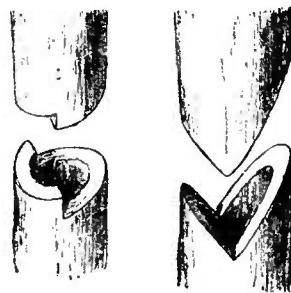


FIG. 50.—METHODS OF CUTTING THE FEMUR FOR UNUNIONED FRACTURE. Two methods are illustrated, but others may be employed. Either involves some slight shortening of the limb, but this is compensated for as there is much less tendency for the fragments to be separated afterwards by muscular action.

**Non-union.**—In cases of ununited fracture of the femur, the procedure is essentially the same. The incision should be made if possible over the outer side of the thigh so as to expose the line of fracture; care is taken not to peel off the periosteum to a greater extent than is absolutely necessary, and the line of fracture is refreshed by chiselling. Extension is then made by pulleys as before, tight bands are divided, and the fractured ends secured by screws.

*After-treatment.*—It must be remembered that union after operation in both these cases is slow, and that the normal period of six weeks is not by any means sufficient for the union of a fracture after operation. At least double that time will be required before consolidation can be expected to be complete, and in many cases it may be as much as six months or even longer before firm union occurs. Hence great care must be taken to keep the parts completely at rest for a sufficiently long period.

This immobilisation should be carried out in the first place, as we have already said, by means of an apparatus similar to that in use for simple fractures. The extension required however is only slight, three

or four pounds usually being sufficient, and it need not be maintained for more than ten days or a fortnight. After the wound has healed, a useful apparatus is a plaster of Paris casing, reaching from below the knee to the groin, in which is incorporated an outside straight splint of wood reaching as high as the axilla above, with a bracketted interruption opposite the trochanter. The upper part of the splint is bound around the thorax with a sheet or a broad bandage. A plaster of Paris splint alone, extending from the foot or calf to the groin, cannot be recommended; however firmly it may be applied at first, the limb becomes so shrunk in a few weeks that the patient can move it inside the splint. The grasp on the upper

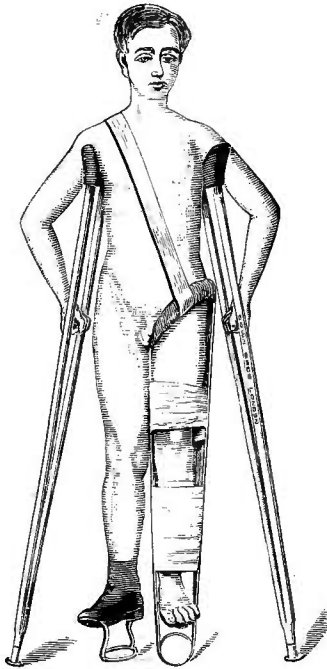


FIG. 51.—THOMAS'S KNEE SPLINT. This splint takes its purchase from the pelvis, and there is therefore no weight thrown upon the lower limb. A patten is fastened to the boot on the sound side.

fragment is so imperfect that movement certainly occurs at the seat of the fracture. If a plaster of Paris casing be employed alone it must certainly be carried around the pelvis, and even then its grip is not at all satisfactory. If the case goes on for more than two or three months without complete union occurring, and if it be desirable for the patient to get about, a Thomas's hip splint with a second bar along the inner side of the thigh and leg is the best arrangement. The limb can always be firmly fixed in a splint of this kind with plaster of Paris bandages if necessary, and the bandages can be readjusted if they get loose. As a substitute for the hip splint Thomas's knee splint (see Fig. 51) may be employed, but it is not so efficient.



**Compound fractures.**—In compound fractures of the shaft of the femur an attempt should always be made to save the limb; the treatment will be the same as that already given for compound fractures elsewhere (see p. 31). The wound should be thoroughly opened up, the skin and soft parts disinfected, special attention being paid to the cleansing of the ends of the bones, and at the same time the opportunity should be taken to fix the ends of the bones together by screws (see p. 51). In these cases also union is slower than in simple fractures, and consequently a longer period of immobilisation will be necessary.

#### FRACTURES OF THE LOWER END OF THE FEMUR.

Fractures in this situation closely resemble those occurring at the lower end of the humerus. The chief ones are supra-condyloid fracture, which occurs at a little distance above the condyles; fracture of either condyle separately; T-shaped fracture into the joint; and separation of the epiphysis. With the exception of the supra-condyloid form all these fractures necessarily involve the joint cavity.

**SUPRA-CONDYLOID FRACTURE.**—This fracture is due either to direct or indirect violence; in the former case the line of fracture is usually more or less transverse, but after indirect violence, such as falls upon the knee, its direction is generally oblique.

**Displacement.**—Fracture usually occurs from one and a half to two and a half inches above the epiphyseal line and the direction of the fracture is oblique from above downwards and forwards. The consequence is that the lower fragment is always behind the upper, and as the gastrocnemius and the popliteus muscles are attached to the lower fragment, the latter is tilted back so that its fractured surface looks more or less backwards into the popliteal space. In some cases this projection is so great that serious pressure on the contents of the popliteal space occurs; indeed the popliteal artery may be punctured by a sharp fragment, or may be entirely torn across. When the artery has been injured there may also be a diffuse aneurysm or so great an extravasation of blood into the ham as to lead to occlusion of the vessel from pressure. Apart, however, from rupture of the artery, the pressure upon it may be so severe as to lead to gangrene of the limb below, especially if, from want of proper reduction of the fracture, the pressure be at all long continued. The upper fragment lies in front of the lower and its lower end is usually directed towards the inner side of the knee, and it is not uncommon for its sharp lower end to perforate the synovial membrane of the knee joint, and to lead to effusion of blood into the articular cavity.

**Treatment.**—It is difficult to obtain a thoroughly satisfactory result after this injury; the backward rotation of the lower fragment renders it difficult to get the broken ends into proper position, while adhesions are

likely to form, and a stiff joint not infrequently follows the injury to the knee or to the soft structures in its neighbourhood.

*Hodgen's splint.*—It is quite clear that the lower fragment cannot be brought into a line with the upper by horizontal traction. Therefore the fracture must be put up with the knee and the thigh flexed, and extension will also be required to pull the lower fragment downwards. For this purpose a Hodgen's suspension splint with the wire frame bent almost to a right angle at the knee may be employed. Before applying it, the patient should be put under an æsthetic, extension applied, and the fragment manipulated into position.

*MacIntyre's splint.*—After three or four weeks the Hodgen's splint may be given up and a MacIntyre's, bent at a considerable angle, substituted for it; this should be continued until consolidation has taken place, which will be in from about six to eight weeks. Fractures in this region are essentially those in which careful massage and passive movement are desirable. They should be employed from the commencement on account of the great tendency to stiff knee. For a description of the method, see p. 30. If the knee joint has been punctured by the upper fragment, there will almost certainly be adhesions; if these be allowed to become firm, the treatment will be much more difficult, as they can only be overcome at a late stage by forcible movement followed by massage and passive motion.

*Operation.*—Even with the greatest care, however, these fractures are apt to give very unsatisfactory results, and in some cases the best treatment is undoubtedly operative. It may be taken as a good rule that at the end of the first week a skiagram should be taken, and, should this show that the bones are not in proper position, the fracture should be cut down upon. The incision should be made at the outer side of the limb, and care should be taken to avoid opening the knee joint if possible by keeping well to the side. When the fracture is exposed, the broken ends are manipulated into position, while an assistant makes extension; the ends are then pegged or screwed together if the fracture be oblique, or wired if it be transverse. The wound is sewn up without a drainage tube, cyanide dressings are applied, and the limb is placed on a MacIntyre's splint without any further extension, the knee being flexed rather beyond a right angle. The dressings should be changed in a week, the stitches taken out, and a collodion dressing applied; massage and passive movement may then be begun with a view of preventing adhesions, care being taken to fix the fragments with both hands while the movements are being carried out.

**Compound fracture.**—When these supra-condyloid fractures are compound great care must be taken to thoroughly disinfect the parts, and special investigation must be made in order to see whether the knee joint is wounded. The wound should be laid freely open, the usual methods for disinfection employed, and the fragments wired or screwed together. If the joint be wounded, the opening into it should be enlarged

sufficiently to enable it to be washed out, at first with 1-20 carbolic lotion, and afterwards with a weak sublimate solution—1-8000—so as to remove the stronger lotion and avoid subsequent irritation. A drainage tube should be inserted for the first two or three days. The limb is then put up in a MacIntyre's splint and the after-treatment already described carried out (see p. 130) if no septic infection occurs. Should sepsis occur, the question of amputation must be carefully weighed, and if the condition of affairs be serious, there should be no delay in resorting to it, because there will be here not only septic osteo-myelitis but acute suppurative arthritis also.

**FRACTURE OF EITHER CONDYLE.**—Either condyle may be detached by a fracture which passes obliquely downwards and inwards or outwards according to the condyle affected.

**Treatment.**—The greatest care must be taken to see that the fragments are got into proper position; in the great majority of cases this is best done by immediate operation. If this be not feasible, reduction should be attempted by manipulation under an anæsthetic and the limb should be fixed on a suitable splint. If there be any backward tilting of the detached condyle, a MacIntyre's splint is best, but if not, the limb may be placed in the extended position in a Croft's splint. A skiagram should be taken in two or three days' time so as to see whether the joint surfaces are in proper alignment; if they are not, it is absolutely necessary that the fracture should be cut down upon and the ends fixed. The incision should be made at the side of the joint, the synovial cavity if possible avoided, and after the fragment has been got into accurate position it is fixed by one or more pegs of sufficient length driven through the condyle; in this case screws may not be long enough. If there be much synovial effusion, it is well to make an incision into the joint, wash out the clots with a 1-8000 sublimate solution, and then to close the incision without a drainage tube. These operations should be performed within two or three days of the injury, as otherwise it will be found extremely difficult to get the fragments into proper position.

*After-treatment.*—The after-treatment is much the same as that which we have already described more than once. The limb should be put in a Croft's splint; massage and passive movement are begun after about ten days and the splint is kept on for at least four or five weeks.

**T-SHAPED FRACTURE OF THE LOWER END OF THE FEMUR.**—This form of fracture requires very little description, being essentially a severer form of the preceding injury and corresponding in every respect to a T-shaped fracture of the lower end of the humerus.

**Treatment.**—There is of course an increased risk of an imperfect result and it is scarcely possible to obtain satisfactory movement of the knee in these cases without operation. An incision should be made on each side of the joint, the condyles exposed, manipulated into position, and pegged to one another by means of ivory pegs of suitable length (see p. 52). Before drilling the condyles for this purpose, the finger should

be introduced through an opening into the joint so as to ascertain that the two condyles are accurately in position. At the same time all blood-clot is washed out of the cavity of the joint and any small loose fragments present taken away. After the condyles have been united to each other the articular end of the bone is secured to the shaft by means of pegs running obliquely upwards from the base of the condyle into the shaft, one on either side.

*After-treatment.*—In spite of early operation and the most accurate adaptation of the fractured surfaces, the prognosis as regards restoration of function in the knee joint is not very good; this is owing to the severe damage inflicted upon the structures in the neighbourhood of the joint and the adhesions that are likely to result from it. In the after-treatment of these cases (which is practically the same as that described for the other fractures in this region) special attention must therefore be paid to the efficient performance of massage and passive motion from an early stage in the case, while at the same time all movement about the fracture is avoided (see p. 130).

**SEPARATION OF THE LOWER EPIPHYSIS.**—This is a comparatively rare occurrence; the injury always necessarily involves a wound of the knee joint and is often associated with defective development of the bone afterwards. It generally occurs from forcible over-extension of the knee and consequently the epiphysis is carried forward in front of the lower end of the diaphysis, which is pressed backward, and may exert dangerous pressure upon the popliteal artery. The injury is often compound.

**Treatment.**—Recent researches, particularly those of Hutchinson and Barnard,<sup>1</sup> seem to show that this particular injury is best treated by full flexion of the knee without the use of any splint. Their description of the method is as follows:—"Under complete anæsthesia an assistant makes steady but strong traction upon the tibia in the line of the limb. This overcomes the upward pull of the quadriceps extensor and brings the epiphysis down to the line of separation. The operator then clasps his hands beneath the lower part of the thigh, and draws it steadily upwards, gradually flexing completely the knee and hip joint, whilst the assistant still keeps up the traction on the leg. It will be seen that this manœuvre causes the epiphysis to move back upon the fractured surface of the diaphysis until it has reached its normal position, and further movement is prevented by the periosteum coming into tight contact with the anterior surface of the femur.

"A bandage is then applied around the thigh and ankle, fixing the knee at about an angle of 60° Complete flexion—*i.e.* heel on buttock—we have found to be unnecessary, and the wider angle is more comfortable. The limb is laid upon its outer side on a pillow, and an ice-bag can conveniently rest upon the front of the knee to limit the effusion."

In about a fortnight's time the limb is moved, preferably under anæsthesia, and then put up in a Croft's splint at an angle of 30° Careful

<sup>1</sup> *Lancet*, May 13th, 1899.

passive movements and massage will be required from this time onwards to maintain the full range of mobility in the joint.

#### DETACHMENT OF ARTICULAR CARTILAGE.

This accident sometimes results from falls upon the knee or the foot. A portion of the articular cartilage with its underlying bone is detached from the surface of one of the condyles of the femur and thus becomes a loose body in the knee joint.

**Treatment.**—If the exact nature of the injury be made out at the time, as by feeling a loose body moving about in the joint, the best plan is to do an arthrotomy at once and remove it. If the surgeon delays operation, the loose body sets up considerable changes in the synovial membrane which may end in the formation of firm adhesions and sometimes in a villous condition of the synovial membrane as a whole, not unlike that seen in osteo-arthritis. The loose fragment rarely becomes united to the bone; if it does, it is in wrong position, and for this reason also the sooner it is removed the better. The exact details of the operation will be described fully when we deal with the treatment of loose bodies in the knee joint (see Part IV.).

## CHAPTER VII.

### FRACTURES OF THE PATELLA.

FRACTURE of the patella is an injury of common occurrence and of great importance. The line of fracture may be either transverse, longitudinal, or starred; the most frequent form is the *transverse fracture*, which usually results from violent muscular action, as when an attempt is made to recover the balance. The knee is bent and the quadriceps extensor is thrown into such violent contraction that the patella is snapped across the condyles of the femur. The fracture is generally transverse, but in some cases it may be oblique from below upwards and backwards, and it usually occurs nearer the lower than the upper end of the bone; sometimes only a small fragment of bone is left attached to the ligamentum patellæ.

Fractures produced by direct blows upon the patella are very often *starred*, the bone being broken up into several pieces. Sometime however they are *longitudinal*, the patella being divided into two more or less unequal lateral portions. In neither of these cases is the separation of the fragments so marked as in the transverse fracture.

**TRANSVERSE FRACTURE.**—There are three points of importance to be remembered in connection with this fracture. In the first place, there is some separation of the fragments, the exact amount depending upon the tearing of the periosteum and the capsule of the joint at the sides of the bone; the separation is generally sufficiently marked to allow the finger to be introduced between the fragments when the knee is flexed. Unless measures be taken to prevent it, the upper fragment becomes more and more drawn up as time goes on, until there may be a gap of several inches between the two fragments. The second and perhaps most important point of all is that the periosteum is not torn across on a level with the line of fracture; the periosteal rent is usually below the fracture, with the result that a piece of periosteum projects for half an inch or more beyond the lower edge of the upper fragment, and curls round and lies over the fractured surface (see Fig. 52). Hence, when the two fragments are approximated, this layer of periosteum is interposed between

them, and this is an essential reason why union by bone does not occur except after operation. The third point to remember is that the lower fragment is usually tilted forwards, and therefore when the upper fragment is brought down into contact, the cartilaginous surfaces do not lie in the same plane. Not uncommonly also the upper fragment is somewhat tilted so that the broken surface looks backwards; this, however, is not nearly so marked as in the lower fragment.

**Treatment in recent cases.**—It follows from the above that the object of the treatment must be threefold; the separation must be overcome, the layer of fibrous tissue and periosteum between the fractured surfaces must be removed, and the tilting of the fragments must be remedied.

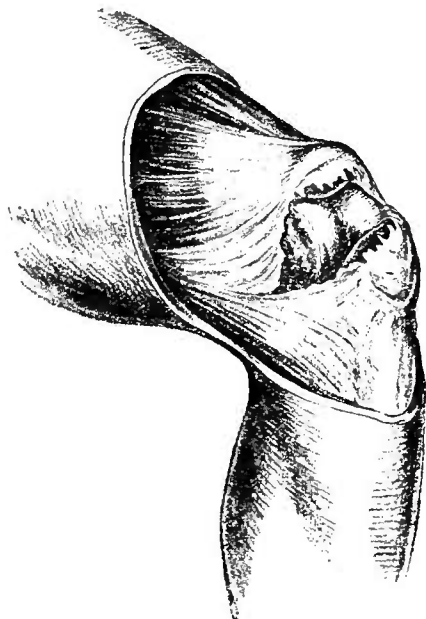

FIG. 52.—TRANSVERSE FRACTURE OF THE PATELLA. The specimen shows the curling-in of the fibrous aponeurosis over the front of the bone, so that the fractured surfaces are partly hidden. (After Helferich.)

**Operative.**—It is evident that by no means short of operation can these objects be effectually carried out. We therefore recommend an open operation as the best treatment for recent fractures of the patella.

*Time for operation.*—It is sometimes asked at what period the operation should be done. Some surgeons prefer to wait for four or five days for the inflammation and synovitis set up by the injury to subside, and at first we were also of that opinion. Lately, however, we have been in the habit of operating as soon as possible after the accident, and we have seen no reason whatever to regret doing so. There is this advantage in an immediate operation, that the sooner it is carried out the sooner can movement be begun and the less chance is there of adhesions forming.

We are therefore strongly of opinion that the operation should be performed as soon after the injury as possible.

*Incision.*—After the skin has been purified with especial care,—owing to the coarseness of its structure, which makes it a favourite seat of micro-



FIG. 53.—INCISION FOR WIRING THE PATELLA.

organisms,—a flap should be turned down over the front of the patella. The incision begins about one inch to one side of this bone, a little below the level of the fracture, and is then carried upwards and curved across the front of the knee about an inch above the upper margin of the patella, and is finally brought down on the opposite side to a point opposite its commencement (see Fig. 53). This flap of skin and superficial fascia is turned down until the lower fragment and the ligamentum patellæ are thoroughly exposed. The advantage of this incision over the usual vertical one is great. If a vertical incision be used, the wire employed to unite the fracture will lie immediately beneath the scar, which it is very apt to perforate, or at any rate to irritate considerably, when the patient kneels; and, should refracture occur, a vertical scar is apt to give way and result in compound fracture. On the other hand, if a flap be employed, the wire, lying underneath healthy skin, seldom causes any trouble, and, should refracture occur, there is no more reason why the fracture should be compound on the second occasion than on the first. Further, it is well to have the convexity of the flap upwards instead of downwards, because if made downwards the scar will lie over the tubercle of the tibia, which is the point exposed to pressure when the patient kneels.

*Clearing the fracture.*—During the operation it is well to have a constant stream of weak sublimate solution (1-6000) running over the wound. This is used partly to wash away blood-clot from the joint and partly to make sure that no septic organisms gain access to it. As the flap is turned down and the line of fracture is reached, the rent in the capsule on each side of the bone will be seen, and blood and clots will be pressed out from the joint. After the two fragments have been thoroughly exposed, the fractured surfaces are everted and inspected, and the periosteal layer which is curled over the surface of the fragments (see Fig. 52) is carefully peeled back; it need not be cut away, because it is well afterwards to stitch it over the line of fracture, but it must be carefully removed from contact with the fractured surfaces. Any adherent blood-clot should also be taken away, and if any small loose fragment of bone be present it is also removed.



*Drilling the bone.*—When the surfaces have thus been prepared, the upper fragment is bored for the passage of the wire. The best instrument for drilling the patella, and indeed most bones, is a square bradawl or “reamer” (see Fig. 16), such as is used in the manufacture of bird-cages; this is much less likely to split the bone. At the point where the bradawl is to be introduced, a small vertical incision should be made through the fibrous structures down to the bone, and each side of this incision should be seized by a pair of catch forceps, so that the edges of the aperture can be held aside, and thus the end of the wire does not get entangled and

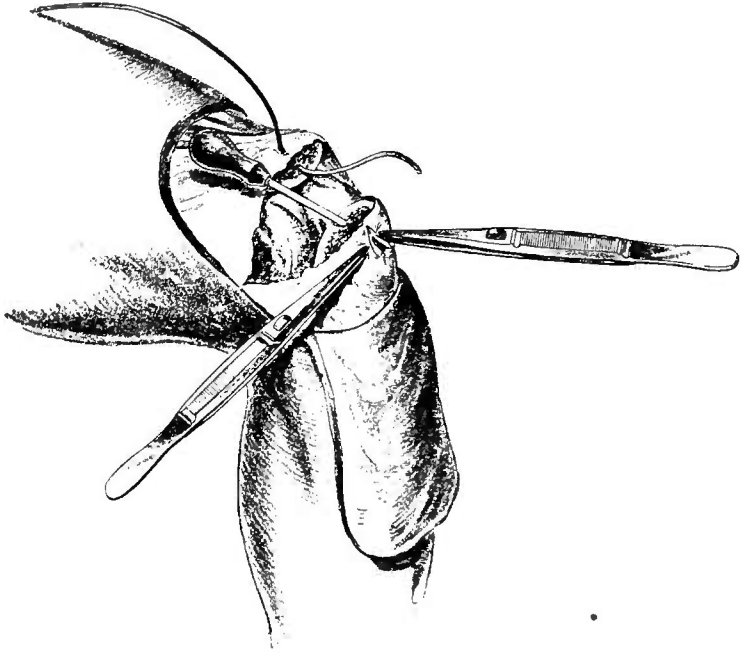


FIG 54.—WIRING THE PATELLA. *Drilling the lower fragment.* The catch-forceps are seen retracting the edges of the slit in the soft parts over the bone. The wire has been passed through the upper fragment. For the sake of clearness the fingers which push up and steady the lower fragment while it is being drilled are not shown.

the opening of the drill hole is not lost (see Fig. 54). The instrument should be entered at the centre of the anterior aspect of the bone, as far away from the fractured surface as possible, and driven obliquely through it, so that the point emerges just in front of the articular cartilage.

*Passing the wire.*—After the upper fragment has been bored in this manner, a piece of strong silver wire, about a tenth of an inch in thickness (known as No. 5 French gauge in the trade), and quite soft and flexible, is passed through the hole. The point on the fractured surface of the lower fragment corresponding to the point of emergence of the wire through the upper one is then carefully ascertained, and a drill is driven downwards and forwards through it until it emerges from the front

of the fragment just at the attachment of the ligamentum patellæ. At the point where the drill emerges, the parts are again divided vertically, and the edges of the incision are caught and held aside with catch forceps (see Fig. 54). The drill is then removed, and the lower end of the wire is pushed through the aperture in the fractured surface and made to emerge between the forceps; in order to facilitate the passage of the wire at this stage, the knee should be flexed to increase the gap between the fragments and a good long loop of the wire pulled out between them (see Fig. 55). This method of drilling the lower fragment from the fractured surface downwards, and forwards to the anterior surface is much

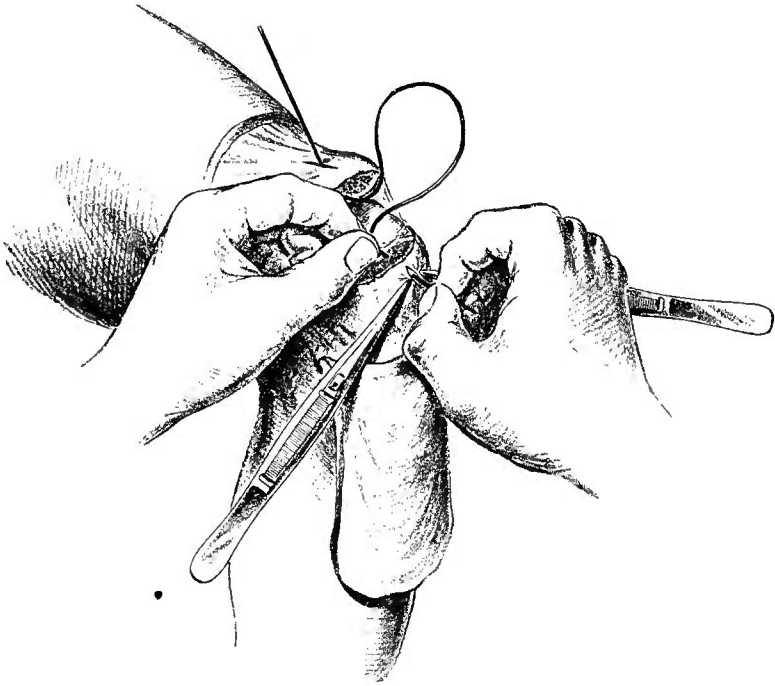


FIG. 55.—WIRING THE PATELLA. *Passing the wire.* The knee is well bent and a long loop of the wire is pulled out and the lower end passed through the lower fragment from the fractured surface.

preferable to that often adopted of drilling upwards and backwards from the anterior surface and making the point of the drill emerge on the fractured surface, as in drilling the upper fragment. By the method we describe it is much easier to ensure the correspondence of the two drill holes on the fractured surfaces; a point of vital importance in securing accurate apposition and a good functional result.

*Fastening the wire.*—The wire is then seized with strong forceps and a sufficient portion is pulled through and straightened by pulling firmly upon its two ends. Having seen that the surface of the fracture is clean, the wire is held quite taut, and the fragments are pushed together over it by an

assistant, while the limb is fully extended, great care being taken to see that the two cartilaginous surfaces are in accurate apposition. The wire is then bent up so as to completely approximate the bony surfaces, and a couple of twists are made in it so as to fix the fragments firmly in position (see Fig. 56). The ends of the wire are cut off by cutting pliers,

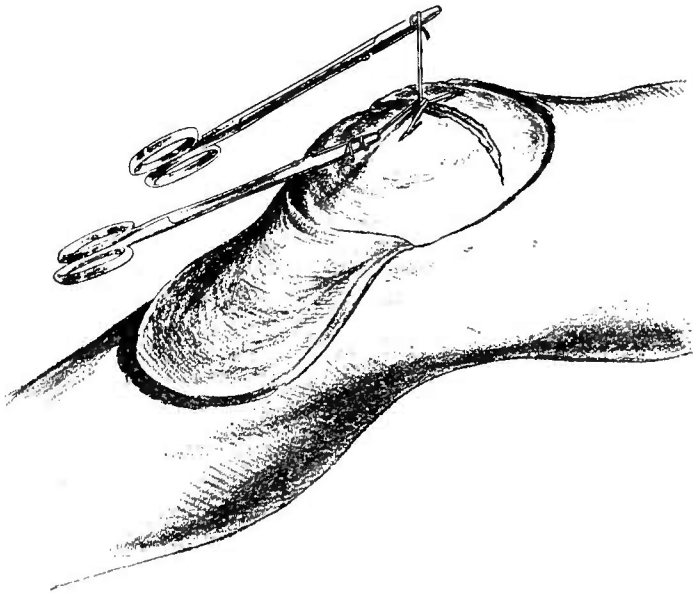


FIG. 56.—WIRING THE PATELLA. *Twisting the wire.* The limb is straightened, the wire pulled taut and twisted. The rent in the capsule is then stitched up, and the flap replaced and sutured.

leaving about a quarter of an inch beyond the twist, and with a small hammer the ends are hammered down so that there is no projection on the surface of the bone.

In some cases a vertical fracture of the lower fragment is met with in addition to the transverse one; under such circumstances the surgeon should begin by uniting the two halves of the lower fragment by means of medium sized silver wire, and then the fragment thus united is secured to the upper one by means of two vertical wires instead of one, one being employed for each half of the lower fragment (see Fig. 57).

The loose periosteum is next stitched with catgut over the seat of fracture, and one or two stitches on either side through the rent in the capsule complete the operation. The skin-flap is then put back in position and fastened by a con-



FIG. 57.—METHOD OF UNITING A COMMINUTED FRACTURE OF THE PATELLA. The two smaller fragments are united by a thin wire, and the single fragment thus produced is united to the other by two stout wires.

tinuous silk suture and the usual cyanide dressings are applied ; no drainage tube is necessary. A considerable mass of dressing should be used and firmly bandaged around the knee ; this will keep the joint sufficiently still without the help of any splint. The patient is then put back to bed and the limb slightly elevated upon a pillow.

*After-treatment.*—The great point in the after-treatment is to restore the movements of the joint as soon as possible, so as to avoid the occurrence of adhesions ; with that end in view we think it well that no splint at all should be employed. Formerly we used to employ splints for about six weeks, but we then found that there was great stiffness which required a considerable amount of patience to overcome ; subsequently they were used for only two or three weeks, and latterly we have not employed them at all, and are much better satisfied with the results obtained. The wound heals by first intention, and at the end of a week the dressings are removed, the stitches taken out, and a thin layer of gauze laid along the line of the incision and fixed on with collodion. The leg is then left perfectly free and the pillow removed, while the patient is encouraged to move the limb as he chooses. No restriction is placed on the amount of movement which he may carry out in bed. At the end of a fortnight he is permitted to get up and to stand with the aid of a couple of sticks and from time to time to bend the knee. At the end of three weeks he is allowed to get about with the aid of two sticks, and by the end of six weeks he is usually able to walk without support, and has perfect movement of the joint. There is no reason whatever why the patient should not be allowed to walk about early, relying on the silver wire alone ; if it be strong enough and has sufficient hold, it may be trusted to keep the parts properly in apposition until bony union has taken place. The wire gives no trouble afterwards if the flap operation be employed. Formerly, when a vertical incision was employed, the wire sometimes caused a good deal of irritation to the scar and had to be removed.

If it be necessary to remove the wire, a small incision should be made over it rather to one side, the wire divided by cutting pliers close to the bone, and then the long end pulled upon until it is extracted. When a very thick wire is used this is sometimes difficult to effect, and in these cases it is best to make a rather longer incision over the wire, cut it just to one side of the twist, and then seizing the ends with a necrosis forceps to straighten the ends as much as possible. Then after cutting off one end close to the bone and applying traction to the other, it can be drawn through without difficulty. The wire should not be extracted until some months after the operation, when it is quite certain that consolidation is complete.

*Other operations.*—Other operative measures have been introduced with the idea that they offer greater safety to the patient ; none of them are in our opinion nearly so satisfactory as the one just described. Malgaigne's

hooks are used by some, and a subcutaneous operation much upon the lines of that devised by Mr. Barker is employed by others. But the objection to them all is that the essential lesions which tend to prevent bony union are not remedied; that is to say, even if they succeed in securing perfect adaptation of the fragments, which is doubtful, the torn portions of periosteum and fibrous tissue are still left interposed between the fragments and offer a bar to proper union. If the surgeon be an adept at aseptic surgery there is no more danger in the open operation than in the others, whilst the result obtained is very much more satisfactory.

*Advantages of operative method.*—Sometimes the patient is disinclined to submit to an operation and the decision does not lie with the surgeon. Before however the patient is allowed to decide, he should have clearly explained to him the result of treatment in the two cases. With an operation the result is practically perfect restoration of the functions of the limb within a very short time; we have frequently had patients able to go about their business within five weeks after the injury without even using a stick and who have subsequently regained absolutely perfect use of the limb. The result of course entirely depends on the asepsis of the wound; if that can be assured, there is really no risk in the matter. On the other hand, progress is extremely slow in cases not treated by operation, and it is often a matter of six months or more before the patient can bear any weight at all upon the limb or can do without some form of apparatus for keeping the fragments together; it is still longer before he can dispense with the aid of crutches or a stick. During this time the muscles of the limb atrophy, so that there is a still further loss of power and it takes a considerable time, even when the fracture is fairly well consolidated, before the patient can get about at all satisfactorily. At first the movements are feeble, slow and uncertain, partly from the weakness of the limb, partly from want of confidence, and very often from actual stiffness in the joint.

A not uncommon result of fractures treated by the expectant method is a more or less stiff knee from adhesions which follow upon inflammation and the long rest necessary to obtain close fibrous union. These adhesions when extensive are all the more difficult to get rid of, because the force required to break them down may seriously imperil the ligamentous union. Besides this, the union that occurs between the fragments is never bony, and although at first the fibrous tissue may be short, broad and firm, and the fragments closely approximated, the uniting medium gradually stretches with movement and the strain put upon it, so that ultimately there may be a very considerable gap bridged across by an elongated thin fibrous band. It is true that cases are recorded and shown where the patient gets along very well after treatment by splints, but it must be remembered that such a result is not the rule, that it is only obtained after very prolonged treatment and is never absolutely perfect. The limb is never quite sound, the patient as a rule cannot go upstairs without dragging his leg behind him, he cannot kick, he cannot go down an incline without considerable diffi-

culty, and there is always a liability to stretching of the fibrous union after a time. The results are in no way equal to those in which the fragments of the patella are united by bone.

*Contra-indications.*—These are very few in number. Even when the patient is fairly advanced in years there is no reason whatever why the operation should not be done; an old patient suffers almost more than a young one from the loss of exercise which is likely to result from the treatment of these fractures by the expectant plan, while the operation is not accompanied by shock and there is no difficulty in obtaining firm union. Of course when patients are in ill-health with heart disease, advanced albuminuria, diabetes and so forth, the operation is naturally contra-indicated, but in an ordinary healthy person there is no real objection to the operation, even though he be 70 years of age or more.

*Palliative.*—In the palliative treatment, the first point is to place the limb on a splint with the knee fully extended and to flex the thigh as far as possible, so as to relax the quadriceps extensor muscle. This is best done by using a back splint with a foot-piece at right angles well raised on an inclined plane. The next point is to bring the fragments as close together as possible, and the chief obstacle to this is the effusion into the joint. Free bleeding occurs into the joint as a result of the injury, and later on synovitis with effusion takes place; until this has been to some extent subdued, the fragments cannot be satisfactorily approximated.

*Reduction of the effusion.*—In the first place, therefore, after placing the limb upon a splint and elevating it, evaporating lotions, lead and opium lotion, or, if the swelling be great, an ice-bag, should be applied until the effusion has become absorbed. It will often be a week or ten days before any serious attempt can be made to bring the fragments into apposition. If the effusion be considerable, matters may be hastened by *aspirating the joint*; this must of course be done with all antiseptic precautions, the skin being purified, and the fluid drawn off with a fairly large aseptic aspirating needle introduced into the joint cavity. The result of aspiration is however seldom satisfactory. It is difficult to completely empty the joint, as a great part of the effusion consists of blood-clot which not only cannot be withdrawn but which is very apt to choke the needle, so that the actual fluid portion is only imperfectly drawn off. At the same time, however, the removal of a small amount of fluid will increase the rapidity of absorption very considerably by relieving the tension. In introducing the needle, care should be taken not to push it too far back into the joint, as otherwise it will be thrust into blood-clot, and will get blocked; it should be pushed downwards beneath the front part of the capsule where the fluid has collected. The small puncture is dressed with a piece of gauze fixed on with collodion; as soon as this has healed, and the swelling is subsiding, steps may be taken to bring the fragments together.

*Approximation of the fragments.*—The first point is to fix the lower fragment so that it is not tilted or pushed aside. The knee is shaved,

and the lower fragment is pushed firmly upwards so as to put the ligamentum patellæ on the stretch; the bone is then fixed in this position by a piece of strapping which has its centre over the ligamentum patellæ and the lower fragment, while its ends pass obliquely upwards on either side to be fixed to the edges of the splint. Care must be taken to see that when the strapping is applied the fragment is in proper position, as the object is not only to fix it, but also to prevent the tilting forward which is so marked a feature, and which might result in the cartilaginous surface of the lower fragment being in contact with the bony surface of the upper one.

After the lower fragment has thus been fixed, the upper one must be brought down into contact with it; this is usually done by applying a

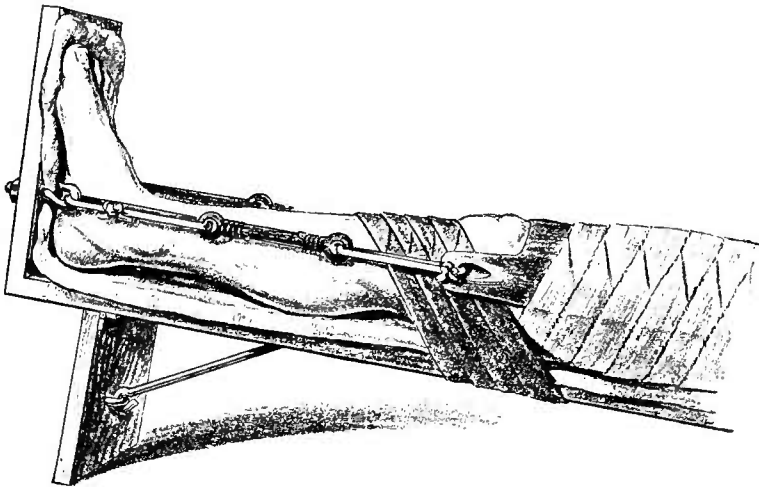


FIG. 58.—FRACTURE OF THE PATELLA TREATED BY SPLINTS. The lower fragment is fixed by oblique strips of strapping fastened to the splint, and the upper one is pulled down by the elastic apparatus shown above, and attached to the horse-shoe shaped plaster bandaged firmly to the thigh.

broad piece of strapping, or "elephant plaster," over the front of the lower part of the thigh, extending from six or eight inches above the upper edge of the patella downwards as far as the line of fracture; it should be cut away over the patella, so that the edge of the bone is surrounded by a horse-shoe shaped piece of plaster. The strapping is then bandaged to the limb, and tapes are fixed to the free lower ends of the plaster on each side; to these are attached pieces of elastic tubing which are fastened to hooks in the footpiece of the splint (see Fig. 58). It is well also, especially in muscular or irritable subjects, to immobilise the quadriceps extensor as much as possible by surrounding the thigh with strapping applied obliquely from above downwards. If sufficient extension be applied, the upper fragment of the patella is brought down into contact with the lower.

*After-treatment.*—It is necessary to keep on this apparatus for six or eight weeks; the plaster must be renewed as often as it slips, and care must be taken to avoid a pressure-sore around the margin of the patella; the best way to prevent this is to insert a pad of boracic lint between the margin of the bone and the edge of the plaster. At the end of about eight weeks, the strapping may be removed, when it is generally found that a certain amount of fibrous union has occurred which will not yield so long as the patient does not involuntarily contract the extensor muscles. The best plan now is to employ massage to the quadriceps in the downward direction so as not to separate the fragments. At the same time it is well to carry out careful movements of the patella designed to prevent adhesions, taking care meanwhile to keep the two fragments in apposition; moreover, a certain amount of passive motion of the knee joint may be effected if care be taken to fix the fragments with one hand.

A tightly-fitting knee-cap, to control the fragments and allow the patient to get about, should then be applied, the limb being massaged twice daily and the patient allowed to walk with crutches. After five or six weeks, weight may be borne upon the foot, but the patient should use crutches for a couple of months longer, and then take to two sticks; it will generally be nearly a year before these can be entirely dispensed with.

Owing to the great muscular atrophy which is apt to follow prolonged rest in the treatment by splints, and owing also to the great risk of stiffness from adhesions occurring within the articulation or between the upper fragment of the patella and the femur, some surgeons advocate the immediate employment of massage with an idea of promoting the nutrition of the muscle and the movement of the joint without regard to the question of firm union; it is held that in this way a considerable proportion of the cases will recover with a fairly satisfactory limb, although there may be considerable separation between the fragments. This, although to some extent true, seems to be a somewhat exaggerated view, and while, on the one hand, it is probably a mistake to keep up the limb for six months without paying attention to the condition of the muscles or the joint, it nevertheless seems very unsatisfactory to give up the chance of close union. Hence, of the two plans, we prefer the former, where operation is not possible or permitted.

**Treatment of long-standing cases.**—Cases of ununited fracture of the patella not infrequently come under observation at a late period, because the patient desires to have something done to enable him to again become a useful member of society. The complaint generally is that the separation between the fragments is so excessive that there is no proper control over the limb, that it is weak, and that, while walking upon the level is possible, there is little power when walking up or down hill or up and down stairs.

*Causes of disability.*—This condition may be due either to absence of union between the fragments, to a thin elongated fibrous union, to adhe-



sions of the patella to the femur, or to adhesions within the capsule of the joint and rigidity of the articular tissues generally; in these cases surgeons are agreed that operation is advisable. But here, although operation is advisable, the results are not nearly so satisfactory as when it is undertaken immediately after the injury; the time and trouble required to obtain even a fairly satisfactory result are very great.

**Secondary suture of the patella.**—An incision is made similar to that already described, except that the convexity of the flap should extend further up the thigh, so as to expose the lower part of the belly of the quadriceps muscle and not merely the junction of its tendon with the patella. After the flap has been turned down until the ligamentum patellæ is exposed, the fibrous tissue between the fragments is divided and removed, and the fractured surfaces are refreshed by means of a saw, a chisel, or bone forceps. Great care should be taken to see that the direction of the two raw surfaces corresponds; if one be oblique the other must be made oblique in the opposite direction. All the steps of the operation should be carried out under an irrigation with 1-6000 sublimate solution.

The next point is to get rid of the adhesions already existing. When the patella is bound down to the femur, the adhesions may be divided with a knife. Any other adhesions in the supra-patellar pouch which prevent the upper fragment from coming down, should also be divided by means of a probe-pointed knife passed into the pouch; the knee should then be forcibly bent, so as to break down any remaining adhesions.

Before bending the limb it is well to replace the flap to some extent and to cover the wound with two or three large flat sponges, as otherwise a quantity of unfiltered air would be worked into the joint cavity. It is important to remember that the adhesions should not be broken down until the fibrous tissue connecting the two fragments has been removed. We have seen cases in which violent flexion was employed before the fibrous tissue had been taken away; the result was that the upper fragment of the patella was broken up, owing to the soft atrophied bone being so firmly attached to the femur that it was unable to withstand the pull of the firm fibrous union upon it.

The limb is now fully extended, and the next step is to see whether the upper fragment can be pulled down into contact with the lower. It is necessary that the fragments should be closely approximated without any great tension, as otherwise the wire readily cuts its way through the bone, which in these old-standing cases is apt to be very soft. If the structures be too short to allow the upper fragment to come down properly, it is better to divide the muscle at its junction with the tendon than to make a series of lateral incisions through the capsule on each side above the patella, as this would very materially interfere with the vascular supply to the upper fragment. If the tendon itself be divided it is apt to unite badly, because it is a non-vascular structure: its division might also interfere with the blood-supply of the bone. If, however, the muscle

be divided, union will occur readily enough, and no interference with the blood-supply need be feared.

*Lengthening the quadriceps extensor.*—The quadriceps should therefore be freely exposed; if this has not been properly done by the original incision, a median vertical incision should be made from the top of the convex one up the front of the thigh and the two flaps turned aside. A series of V-shaped incisions are then made through the muscle in an exactly similar manner to that already described for lengthening the triceps in fractures of the olecranon (see p. 88); two V's, each limb of

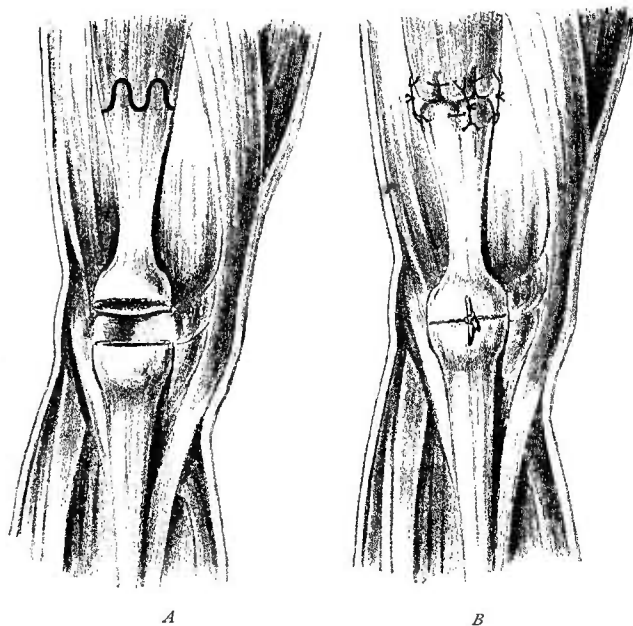


FIG. 59.—LENGTHENING THE QUADRICEPS IN SUTURE OF THE PATELLA. *A* shows the gap between the fragments and the serrated incision at the junction of the muscle with its tendon to allow the fragments to be approximated. The result is shown in *B*, where the adjacent edges of the serrations, above and below the line of incision, have been stitched together, and the apices of the two blunt cones thus formed have been sutured after the quadriceps tendon and the upper portion of the patella have been pulled down sufficiently to allow the fragments to come together.

which is about two inches in length, are sufficient (see Fig. 59). With an incision made in this manner there is no fear of non-union of the muscle, nor is there any transverse fibrous scar which may subsequently stretch; union occurs very satisfactorily and the patella is permitted to come down. If the patella still does not come down sufficiently, it will generally be on account of some adhesions remaining in the supra-patellar pouch, which may be divided by introducing the knife on the flat into the pouch and cutting them. When the fragments have been brought into contact, they should be wired together in the manner described for recent fractures (see p. 137); but the wire should if possible be entered further from

the fractured edge than in a recent case. The approximation of the fragments will be facilitated by elevating the leg and thus relaxing the quadriceps; in very bad cases it is only by so doing that one can bring the fragments together even after division of the muscle.

*After-treatment.*—When the bleeding has been arrested and the wound stitched up, the limb must be placed in a well-padded Croft or Gooch's splint, and laid upon a high inclined plane for a few days; after two or three days the height of the latter is diminished, and in about ten days or a fortnight the limb can be allowed to lie flat on the bed. The dressing is taken off in a week, the stitches removed, a collodion dressing applied and the splint left off. It is impossible in these cases to begin passive movement as early as is done in recent fractures on account of the division of the muscle, which requires at least three weeks for proper union. In the meantime, however, the patient should, by gently moving the knee in bed, keep up a certain amount of movement; at the end of three weeks massage and passive motion may be begun. A fairly satisfactory result will generally be thus obtained; the patient cannot as a rule get movement beyond a right angle, even if he gets as much as that; but still, with a firm limb and such a considerable range of movement, he is in a very much better condition than he was before.

*Apparatus.*—In cases of old-standing fracture of the patella where no operation is permitted, all that can be done is to fix on a suitable knee-cap, which keeps down the upper fragment, holds the knee stiff, and so gives the patient fairly firm support.

**COMMUNUTED FRACTURE.**—When fracture has resulted from direct violence, such as a blow upon the knee, the line of fracture is usually starred or comminuted, and there is not the same tendency to separation as in the ordinary transverse fracture due to muscular action. It is not uncommon to find the periosteum more or less intact, and the fragments are thus held together by it.

**Treatment.**—If the limb be put at rest for some three or four weeks on a splint, and massage and careful passive motion employed for another three or four, bony union and good movement are the general result. If, however, the fragments be separated, or if they do not lie at the same level, it is well to cut down on them and bring them accurately together by silver wire, after removing any fibrous tissue which may have got in between the fragments. In such a case thin wire may be used; in fact it is absolutely necessary when the fragments are small, and its use is also especially called for when the fracture is a vertical one, as it then bears comparatively slight strain when approximating the fragments.

Except when it has been possible to pass a stout wire from the upper fragment to the lower, a splint should be applied and kept on for about a fortnight: the patient should be kept in bed for another two or three weeks, the limb being massaged in bed and gentle passive motion being practised.

**COMPOUND FRACTURE.**—This is comparatively rare in the patella; it may however be the result of direct injury and is then generally starred.

**Treatment.**—This must of course be the treatment of an injury to the joint, and will consist in careful disinfection of the wound, removal of any loose fragments of bone, and sponging the fractured surfaces with pure carbolic acid, which must not be allowed to run into the joint. The latter is then washed out with a 1-40 carbolic acid solution, and subsequently with a 1-8000 sublimate. The fragments of the patella may be then wired if necessary, and one drainage tube inserted into the joint and another between the bone and the skin.

*After-treatment.*—The case must be carefully watched lest sepsis should occur; if it does, it will be necessary to make very free incisions into the joint and irrigate it with saline solution or boracic lotion until the violence of the inflammation has subsided. In some cases it may be necessary to excise the joint or amputate the limb. Further details on these points will be given under Wounds of Joints (see Part IV., Chap. XI.).

**VERTICAL FRACTURE.**—This form of fracture is rare, and generally results from direct blows upon the bone. The separation of the fragments is only slight as they bear no strain, and the fibrous structures over them are generally but little damaged.

**Treatment.**—What has already been said above with regard to Comminuted Fracture of the Patella applies equally well to this form, and need not be repeated here.

## CHAPTER VIII.

### FRACTURES OF THE LEG AND FOOT.

#### FRACTURES OF THE BONES OF THE LEG.

IN the large majority of cases both the tibia and the fibula are broken; sometimes, however, either bone may be broken separately.

#### FRACTURES OF THE TIBIA ALONE.

Like most long bones, the tibia may be broken in various situations; the fractures are generally grouped into those of the upper end, the shaft, and the lower end.

**FRACTURES OF THE UPPER END OF THE TIBIA.**—These injuries are seldom met with and do not require much description. The fracture sometimes involves the articular end of the bone, as in falls from a height on to the feet, when the tibia is driven forcibly up against the condyles of the femur and the tuberosities of the former are split into several fragments; this is sometimes spoken of as a “compression fracture” of the upper end of the tibia. In other cases the spine of the tibia may be broken off, or in children there may be a separation of the epiphysis; the latter is an extremely rare injury.

Fracture of the tibia just below the tubercle may also occur, and is generally due to severe direct injury, such as the passage of a heavy cart-wheel over the limb. The fracture may be either transverse or oblique; if transverse, there is usually little or no displacement owing to the breadth of the fractured surfaces. If the fracture be oblique, the obliquity is generally from above downwards and forwards, and the upper fragment projects somewhat anteriorly.

**Treatment.**—When the case is one of **compression fracture**, an anæsthetic should always be administered, firm extension employed and the fragments manipulated into position. When this has been done, it will be advisable to employ some *extension* so as to prevent the tibia from being pressed up against the femur. The ordinary weight extension (see Fig. 14)

will generally suffice, and about three to four pounds will be sufficient. Should there be any tendency to outward rotation of the leg, a back splint may be put as high as the knee to steady the leg, and extension made from that. Evaporating lotions (see Part I., p. 8) will be required for the first ten days to subdue the effusion in and around the joint.

After the lapse of a fortnight, *massage and passive movement* should be begun, and in about three weeks a *Croft's splint* may be applied, while the massage and passive movement are continued once or twice daily. The fracture is of course followed by marked effusion into the joint; this at first consists of blood and afterwards of synovial fluid, and hence massage and passive movement are absolutely necessary if a movable joint is to be obtained.

When **the spine of the tibia** is broken off, the diagnosis is extremely difficult, and is usually only made after the joint has been opened on account of symptoms resembling a loose body in the joint, or of a so-called internal derangement. The detached spine of the tibia should either be pegged into place or, if the fractured portion be only small, it should be removed entirely. Skiagraphy should always be employed when there is any suspicion that the case is one of this nature.

In **transverse fracture** just below the tubercle, or **separation of the epiphysis**, all that is necessary, after having manipulated the fractured ends into position under an anæsthetic, is to apply a *Croft's splint* (see p. 14), which, after being opened on the following day, can be afterwards transformed into an immovable casing. The position of the knee does not much matter; the splint extends from about half way up the thigh down to the ankle.

When the fracture is oblique there is a tendency for the upper fragment to be pulled forwards; this is readily overcome by placing the limb in the fully extended position and then applying a Croft's splint from the foot to the middle of the thigh.

**FRACTURES OF THE SHAFT OF THE TIBIA.**—These are much more common than fractures of the upper end of the bone, and usually occur in the lower third. The cause is generally direct violence, such as a run-over injury, but it may also result from indirect violence. When due to direct violence, the fracture is often comminuted and not infrequently compound, but is generally transverse in direction; when it is due to indirect violence there is often considerable obliquity of the line of fracture from below upwards and backwards. In a fracture from direct violence there is only slight displacement, unless the fracture be comminuted; the upper fragment is tilted somewhat forwards while the lower is carried backwards by the weight of the foot. There is usually a good deal of bruising of the skin, which is very apt to slough if the pressure of the apparatus be at all severe; this point must be carefully attended to in putting up the fracture.

\* **Simple fracture.**—When the lower fragment is brought into line with

the upper, means must be taken to relax the calf muscles—especially if the fracture be at all oblique—as their contraction is apt to produce a tilting forward of the upper fragment, the result being that union occurs with the fragments in bad position and the sharp lower end of the upper fragment may perforate the skin. There is not so much danger of this accident happening as there is when both bones of the leg are broken; in the cases under consideration the unbroken fibula acts as a splint and prevents excessive deformity.

**Treatment.**—The best splint at first is MacIntyre's, arranged so that the heel is well supported (see p. 153); a pad is placed over the tibia, two or three inches above the fracture, and firmly bound down so as to keep the upper fragment in position. This pad must not be applied too near to the fracture, as otherwise the skin will very readily slough from the pressure. If there be any difficulty in bringing or retaining the fragments in proper position, the best plan is to cut down on the fracture and to screw the fragments together (see p. 51); the wound heals by first intention, and in the course of a week the leg may be put up in a Croft's splint, when perfect union should be obtained.

If the effusion be so great as to threaten the vitality of the skin, the limb may be fixed either in well-padded lateral poroplastic splints, not

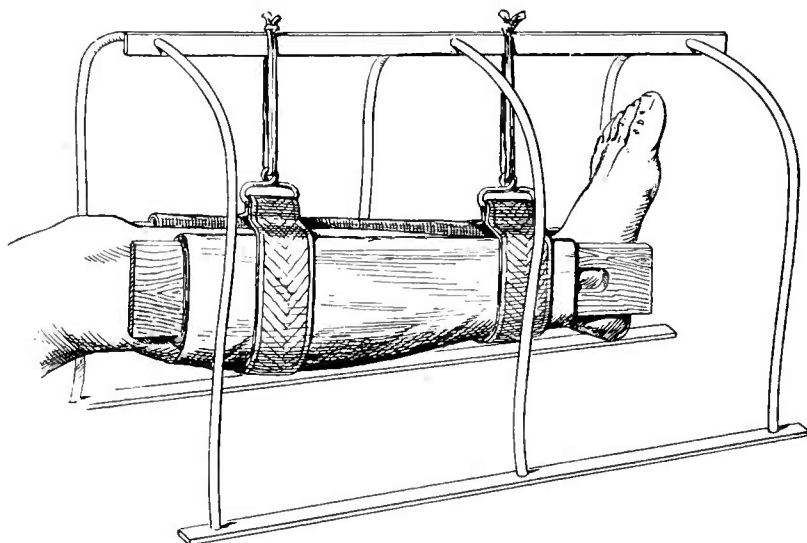


FIG. 60.—"FRACTURE BOX" OR "BOX SPLINT" FOR FRACTURES OF THE LEG. The two lateral splints are rolled up in a folded sheet as described in the text, fastened to the limb by straps and buckles, and the whole apparatus slung to the cradle. A bandage is usually also put on over all.

bandaged on too firmly, or, still better, in what is termed a "box splint." This *box splint*, or "fracture box," is also a very convenient form of apparatus for fractures of both bones, and indeed for any fracture of the leg where a temporary arrangement is required before the limb is put up

in plaster of Paris ; it is constructed as follows. Two pieces of wood are taken, as broad as the antero-posterior diameter of the leg, and long enough to extend from the tuberosity of the tibia to two or three inches beyond the sole ; these splints are rolled up in opposite ends of a sheet as broad as the splints are long, until the two almost meet in the middle. The leg is then placed upon the sheet in the interval thus left, and the splints are turned up on each side, all hollows between the limb and the lateral splints being carefully filled up with wool and suitable pads. The sheet between the two splints supports the back of the leg and the heel, and an extra pad should be placed just above the latter. The splints are then fastened on with slip-knots, and a bandage is applied outside them ; the whole apparatus is then slung in a cradle, the knee being bent nearly to a right angle (see Fig. 60). No pressure is exerted upon the damaged skin by this splint, and by fastening it with slip-knots, the seat of fracture can be readily exposed without any disturbance.

Blisters containing a blood-stained fluid are often present in these cases, and, should they occur beneath a plaster of Paris casing, serious harm may result. If blisters form, the skin should be disinfected in the ordinary manner (see Part I., p. 161), the blisters punctured, and full strength boracic ointment applied over them ; unless gangrene be going to occur, the blisters will heal in a few days and the swelling will subside, when the limb may be fixed up more securely in a Croft's splint. This, however, should be opened up on the same day as it is applied, in case there be fresh swelling, or in case the shrinking of the plaster as it dries should cause pressure upon the still tender skin. In many cases, no doubt, the treatment with the box splint may be carried on throughout, but the Croft is certainly more convenient as soon as there is no longer any risk of pressure. The splint should be kept on for about six weeks ; in simple transverse fracture there is usually no fear of non-union ; in the oblique forms, however, it is more likely to occur, and special care must be taken to ensure good immobilisation.

**Comminuted Fracture.**—As the result of direct injury there may be a comminuted fracture, which is often accompanied by injury to and subsequent sloughing of the skin.

**Treatment.**—The parts should be manipulated into position under an æsthetic, a box splint applied, and the same line of treatment employed as before. Should it be evident that the skin will slough, the neighbourhood of the fracture must be rigidly asepticated ; cyanide gauze dressings should be applied and should be changed every day, so as to see the condition of the parts. Should the skin recover, a Croft's splint may be applied after a week or ten days ; should the skin slough, however, the treatment will be that appropriate for gangrene due to crushing (see Part I., p. 65). Union will usually occur in about six weeks ; in a comminuted fracture special care should be taken to see that the union is firm before the patient is allowed to get about.



As these fractures are at some distance from the joints, there is no risk of stiffness either at the ankle or the knee; but it is well to keep the foot at right angles to the leg, so that, should ankylosis occur, the patient can put the sole of the foot flat on the ground; this is also the best position from which to commence passive movement afterwards.

**Compound Fracture.**—The occurrence of a wound is very common in the fractures due to direct injury; this wound may not communicate with the fracture, but it often does so.

**Treatment.**—This is sometimes very difficult. The treatment of compound fractures in general has already been described (see p. 31), and we would refer the reader to the methods of disinfection of the skin, and the treatment of the wound described there; the point of greatest difficulty in the management of the case is how to provide on the one hand for the due immobilisation of the fracture, and on the other for the proper care of the wound. If the fracture be comminuted it should be carefully examined with the fingers, and any fragments absolutely detached should be removed; only those that retain any connection with the tissues around should be left, after being manipulated carefully into position. Any incision made by the surgeon for the examination of the wound should be stitched up, while the original wound is left open. It is useless to attempt to bring the contused edges together, because they will not unite by first intention, and besides this it is necessary to provide for drainage should sepsis occur.

The best splint is that known as MacIntyre's, and consists of two metal troughs, moulded to receive the thigh and leg, hinged together opposite the knee joint, and capable of being flexed to any degree by means of a screw at the back. The limb should be put up with the knee bent nearly to a right angle. The splint is provided with a foot-piece which can be inclined at an angle. The heel must be properly supported; this may be done by passing a broad bandage across opposite the heel through the slots in which the foot-piece moves and tying it behind the splint. By tightening this sufficiently the heel can be raised or lowered to the requisite degree. The splint is padded with a folded sheet, over which is placed a piece of jaconet or mackintosh sponged over with 1-20 carbolic acid solution, so as to prevent the sheet being soaked by discharges from the wound. Upon the splint thus prepared is placed, first, a thick layer of salicylic wool, and then pieces of cyanide gauze reaching from the ankle to the knee; these should be arranged like a many-tailed bandage, so that when the leg is in position upon the gauze the ends can be folded over in front. When this has been done, salicylic wool is applied over the dressing in front, and the leg firmly bandaged to the splint. In arranging the padding the leg must be kept carefully in position and there must be no pressure on any bony point. The usual rule for ascertaining whether the limb is in proper position is to see that the inner condyle of the femur, the ball of the great toe and the internal malleolus are all in the same

plane. The best plan is, however, to expose the other leg and to compare the two sides.

*After-treatment.*—At first the dressing must be changed every day; this may be done with the least possible disturbance by having a second MacIntyre's splint at hand arranged in an exactly similar manner. The original dressing is then turned aside without disturbing the leg, the wounds are washed, and an assistant supports the thigh, while the surgeon gently lifts the leg, grasping it firmly at the ankle and above the fracture. The splint and dressing are then taken away, an assistant washes the back of the leg with 1-2000 sublimate solution, the fresh splint is placed in position, the leg laid down on it, and the dressing arranged as before. It is of course only during the first week or ten days that frequent dressings are necessary; later on it will not be necessary to lift the leg out of the splint at all; it will suffice to turn aside the dressing, pack in a little gauze along the side of the leg, and then apply a fresh piece of dressing in front, so that for several days the back of the leg need not be disturbed. As soon as healing has occurred, the leg may be placed in a Croft's splint and kept at absolute rest.

As only the tibia is fractured and the fibula remains intact there is not much danger of unduly disturbing the fracture when the limb is transferred from one splint to another, as we have recommended above. Should it be found, however, that it is impossible to carry this out without risk, the interrupted plaster splint (see Fig. 15) should be employed instead.

**Ununited fracture.**—Ununited fracture occurs frequently from imperfect fixation of the foot. If prolonged rest in a plaster of Paris casing fails to secure union, operation may become necessary. When the fracture is transverse it may suffice to remove the fibrous tissue between the ends of the bone and to refresh the latter; union will occur even though there be some little interval between the fragments, provided that no soft parts are interposed. In one case of non-union in which the interval between the fragments, after removal of the intervening fibrous tissue, was not more than a quarter of an inch, we chiselled off a thin shaving of the tibia above the seat of fracture and hammered it firmly in between the two fragments so as to wedge them together; perfect union resulted. If, however, the interval be considerable, the fibula must also be exposed and enough of it removed to allow the two ends of the tibia to come together. The former method is always preferable if it can be adopted; if the fibula be resected there may be greater delay in the union on account of the greater mobility of the limb. It is very rarely, however, in this form of fracture that the gap between the fragments will be of any size, owing to the fact that the fibula is intact throughout and therefore resection of it will hardly ever be called for.

**FRACTURES OF THE LOWER END OF THE TIBIA.**—Fracture in this region is extremely rare and need not be referred to at length.

Sometimes the internal malleolus is broken off by direct violence, such as a kick, without any fracture of the shaft.

**Treatment.**—In the latter case there will be no displacement of the foot and but little of the malleolus; it suffices to put the leg up in a Croft's splint and to keep it in this for about a fortnight. It must be taken down daily from the first for passive movement and massage. Union usually takes place readily.

#### FRACTURES OF THE FIBULA ALONE.

**FRACTURE OF THE SHAFT.**—Apart from Pott's and Dupuytren's fractures, the shaft of the fibula is very rarely fractured alone on account of its deep situation; should fracture occur, the displacement is usually slight, as the tibia forms an excellent splint.

**Treatment.**—All that is necessary is to apply a Croft's splint and keep the limb in it for two or three weeks, opening it daily from the first for the employment of massage and passive movement of the ankle. After three weeks the splint may be left off entirely, the massage and passive movement being continued; the patient may be allowed to walk in four or five weeks' time. It is essential to see that there is no mal-position of the foot.

**POTT'S FRACTURE.**—**Definition.**—This is a fracture of the lower end of the fibula accompanied by an outward displacement of the foot. The fracture of the fibula is frequently associated with fracture of the internal malleolus; sometimes, however, the internal lateral ligament of the ankle gives way and the malleolus either remains intact or a mere shell of bone is torn from it. The essential features of the injury are the fracture of the fibula and the dislocation of the foot.

**Displacement.**—The fibula is fractured from an inch to an inch and a half above the base of the malleolus. The typical Pott's fracture is always due to indirect violence; fracture may occur in this situation from direct injuries such as kicks, but it is then unaccompanied by the displacement of the foot and cannot therefore be looked upon as a Pott's fracture. In most cases of Pott's fracture there is a tendency to displacement backwards as well as outwards; in cases which result from catching the heel, the backward displacement is very marked and has to be specially counteracted. As the fibula breaks, the internal malleolus usually gives way and there is more or less tearing of the anterior and posterior tibio-fibular ligaments. The fracture is usually transverse and there is some angular displacement. This injury is of very great importance, because marked disability will result if the displacement of the foot be not properly remedied; when the fracture has been allowed to go untreated, the patient is hardly able to walk at all.

**Complications.**—A variety of complications may be met with in Pott's fracture, of which the following are the principal: (1) The fracture always communicates with the joint, and therefore there may be great difficulty

in preserving free movement of the ankle; defective movement may be due to imperfect reduction of the fracture, to union of the fractured surfaces in bad position, or to adhesions in the joint. Imperfect reduction may result either from inability to restore the internal malleolus to its proper position, or, much more rarely, from the interposition of tendon, fascia or ligament between the articular surfaces of the tibia and the astragalus. The tendon that is most likely to give trouble is that of the flexor longus hallucis. (2) These fractures are very prone to become compound; indeed they are not uncommonly compound from the first, the lower end of the tibia piercing the skin over it at the base of the malleolus and protruding on the inner side. Even when the fracture is not compound at first, it is very apt to become so secondarily, either from laceration of the skin before reduction, or from gangrene or ulceration afterwards.

**Treatment.** (a) **Of simple fractures.**—The first point is *accurate reduction* of the deformity, and the second, careful fixation of the part so that dislocation shall not recur. As a rule it is best to administer an anæsthetic; no doubt reduction can be effected without it, but the pain and the contraction of the muscles render it difficult, and the difficulty is still further increased when there is also backward displacement of the foot, as the calf muscles tend to prevent the heel coming properly forward. Before the patient is put under an anæsthetic all the necessary arrangements for fixing the limb must of course be made. When the muscles are fully relaxed, the knee is flexed, and the upper part of the leg is fixed by an assistant, while the surgeon grasps the foot with one hand and the leg with the other and manipulates the foot into position.

After reduction has been effected, the foot should be well inverted, so that the internal malleolus falls into its proper position and the deformity in the fibula is obliterated. It is important to be sure that there is no obstruction to the movements of the ankle, that the internal malleolus is not caught between the astragalus and the lower end of the tibia, and that there is no tendon or fascia interposed between the articular surfaces; this is readily ascertained when reduction has been effected. When the surgeon is satisfied that the joint is in good position, and that nothing interferes with its movements, the limb should be fixed with the foot firmly inverted.

*Splints.*—Various splints are employed; if there be no marked swelling or difficulty in reduction, the simplest plan is to put on a *Croft's splint* (see p. 14), extending from above the knee to the ball of the toes; if there be much spasm of the muscles, it is well to make the splint extend up only to the tubercle of the tibia and then to flex the knee fully upon an inclined plane. The foot is held in position until the splint dries, and the greatest care is taken to keep it at right angles and fully inverted. In this particular fracture it is essential to adopt treatment to obviate the possibility of stiffness of the ankle, and this must be begun from the first. Indeed the method already described in detail (see p. 30) of treating

fractures largely by the employment of careful massage finds its most useful application in cases of Pott's fracture, and should always be employed. Owing to the readiness with which displacement recurs, the greatest care has to be taken to fix the fracture while the joint is moved; even after some time displacement may still occur from want of attention to this point, or from mere looseness of the splint due to shrinking of the limb or alteration of the padding.

*After-treatment.*—The splint can usually be left off entirely in three weeks, but the patient should not be allowed to bear weight on the foot for some seven or eight weeks; the weight of the body may easily produce a valgus condition while the union is still soft. So long as massage and passive movement are thoroughly practised, there is no fear of stiffness in the joints, and there is therefore no need to bear weight on the foot too early when this treatment is adopted. The patient may get about on crutches, with the knee flexed and the leg suspended by a bandage round the neck or supported in a knee rest. When however there is severe œdema on allowing the limb to hang down, as is likely to occur when it has had a prolonged rest in splints, it is better to keep the patient recumbent with the leg elevated, because swelling is apt to occur inside the splint and to interfere with the nutrition of the limb.

When eversion is very marked and difficult to overcome and especially when there is much swelling, a Dupuytren's splint is the best in the first instance; when there is considerable backward displacement, Syme's splint either alone or in conjunction with Dupuytren's is of service. *Dupuytren's splint* is a Liston's long splint in miniature, and extends from the internal tuberosity of the tibia to three or four inches beyond the sole of the foot. It has two holes side by side at the upper end and ends below in three prongs; its breadth is equal to the antero-posterior diameter of the leg. This splint is designed to pull the foot forcibly inwards; the inversion thus effected is provided for by separating the ankle from the splint by a large pad just above the base of the internal malleolus; opposite the malleolus itself there should be no padding, an interval of about a couple of inches intervening between the lower end of the splint and the inner side of the foot. It is usual to employ a large wedge-shaped pad, the length of the splint, with its base opposite the malleolus. The upper end of the splint is first fastened so as to prevent it from slipping upwards; the best way to do this is to fold a handkerchief until it forms a band about three inches in breadth, to place the centre of this band over the inner tuberosity of the tibia, pass the two ends of the handkerchief around the outside of the leg, bring them forward again and pass them through the holes in the upper end of the splint and tie them tightly (see Fig. 61, *A*). By taking a grasp of the upper end of the tibia in this way the splint cannot slip up, but care must be taken that its upper end is carefully padded so as not to press unduly against the bone.

The splint should next be fastened to the leg by means of a bandage which does not extend as low as the seat of fracture. The inversion of the foot can then be readily effected by means of a handkerchief folded as just described, and carried horizontally round the ankle with its centre just above the inner malleolus. The ends of this bandage are crossed over the outer side of the instep and passed through the prongs of the splint; by pulling on them the foot can be inverted to any degree required (see Fig. 61, *B*). The pad above the base of the malleolus must be large enough to allow the foot to be inverted to the fullest extent without its inner border

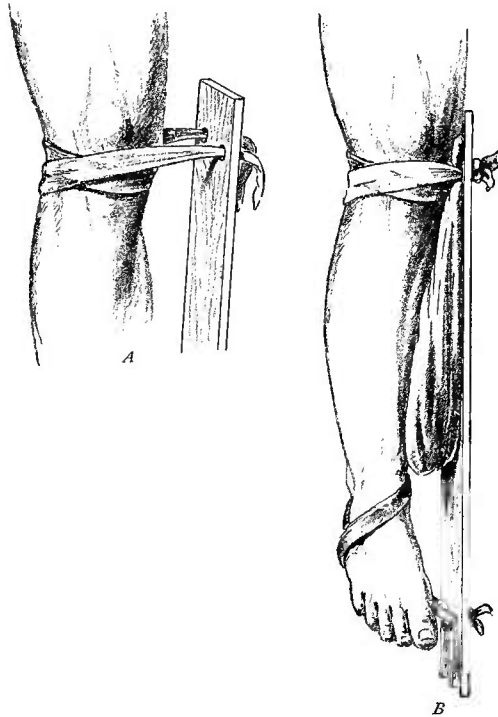


FIG. 61.—DUPUYTREN'S SPLINT. In *A* is shown the manner in which the upper end of the splint is fastened to the leg so that it cannot slip. A folded handkerchief is used, and is applied around the limb on a level with the tubercle of the tibia. In *B* the splint is seen applied, and the method of inverting the foot is shown. The splint is generally further secured to the leg by a bandage.

touching the splint, as otherwise pain and a pressure sore might result. The bandage thus applied around the heel does not press on the fracture in the fibula at all, and if there be any backward displacement of the foot, this can be overcome by passing the ends of the bandage around the anterior prong only; the foot is thus both inverted and dragged forward.

After the leg has been fixed in this way, the limb should be slung in a cradle with support to the heel. In three or four days it is easy to carry out passive movement and massage of the ankle, without removing the apparatus, by merely undoing the handkerchief which inverts the foot;

afterwards the apparatus is reapplied, and any bandages that require it may be tightened up. The case demands careful watching to see that the bandages do not stretch and allow the eversion to recur. After about ten days—when the swelling will have gone down and there will no longer be the same tendency to eversion of the foot—the limb should be put up in a Croft's splint, with the foot at right angles as already described; the later treatment, passive movements, etc., will be same as before.

In some cases there is very marked displacement of the heel backwards; this occurs chiefly when the fracture has been caused by a fall in which the violence is applied to the ankle in the outward and backward direction. This backward displacement is much more difficult to overcome than the eversion so commonly met with in the ordinary Pott's fracture; in order to rectify it the splint known as *Syme's horseshoe splint* was introduced.

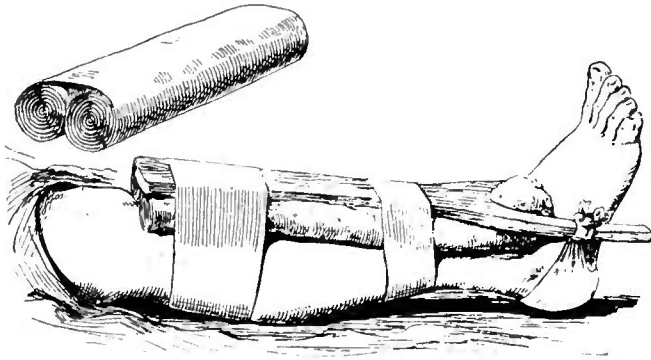


FIG. 62.—SYME'S HORSE-SHOE SPLINT. The sling embracing the heel may be made of elastic webbing. The smaller figure shows the method of rolling up lint to make the padding. The splint is very commonly supplied with two holes bored in its upper end. It is then secured to the upper part of the leg in a manner very similar to that shown in Fig. 61, A.

This is a wooden splint about the breadth of the leg, extending from the tubercle of the tibia to the instep, where it is hollowed out so that it ends in two prongs which pass down, one on either side of the foot, and project beyond the sole. This splint is applied to the front of the leg and is used to bring the heel forward; the important point to remember in using it is that pressure on the crest of the tibia must be carefully avoided, for, unless the padding be carefully arranged, a pressure sore may occur along its whole length. This is best avoided by arranging the padding in the following manner (see Fig. 62). A sheet of boracic lint of sufficient length and of width corresponding to the length of the splint is taken, and its two ends are rolled up from each side so as to meet in the middle, in the same way as a double roller bandage. The lint is then applied so that one roll lies on either side of the crest of the tibia, that over the inner side of the tibia being somewhat thicker than that on the outer; the pad thus made should be sufficiently thick to prevent the splint touching the

crest of the tibia anywhere. The splint is laid upon the padding and fastened above by a folded handkerchief, the centre of which is placed just below the tubercle of the tibia, while its ends are passed round behind the limb, brought forward, threaded through the holes in the top of the splint and tied. After the upper end is fixed, the splint is bandaged to the limb and a handkerchief is passed behind the point of the heel and the latter dragged well forward, the ends of the handkerchief being passed around the prongs of the splint, then back again beneath the heel and fastened there. When there is much backward displacement of the foot it is well to arrange an extra mass of wool between the lower end of the splint and the front of the leg, so as to serve as a fulcrum to enable the heel to be pulled well forward.

When there is both displacement outwards and backwards, a Dupuytren's splint may be applied first, and then a Syme's splint. The heel bandage should be made to drag forward the heel before the bandage to invert the foot is tightened; by this combination of Dupuytren's and Syme's splints the displacement is satisfactorily overcome. The splint must be watched with great care for pressure sores both over the crest of the tibia and the front of the instep; should any signs of these be present, the splint should be abandoned at once. After about ten days a Croft's splint can be applied and the limb slung in a cradle.

(b) **Of compound fractures.**—A compound Pott's fracture is a very serious condition, and the greatest care must be taken in the disinfection, as the case is one of compound fracture communicating with a joint. Fortunately the wound generally results from the end of the tibia being driven through the skin, so that there is no primary infection of the joint; any dirt or foreign matter present is generally in contact with the end of the bone and does not often find its way into the joint, so long as the surgeon takes care not to replace the protruding bone until thorough disinfection has been carried out. Cases of compound fracture of this kind seen before the materials for proper disinfection are at hand should be put on a splint and steadied there without any attempt to reduce the fracture until the necessary arrangements can be made; the very greatest care should be taken to prevent premature reduction.

The further treatment is that already described for compound fracture (see p. 31); the end of the bone is most carefully disinfected with pure carbolic acid, the whole of the malleolus being thoroughly protruded and the skin wound enlarged if necessary; the skin is also disinfected and the joint is washed out, first with 1-20 carbolic lotion and then with 1-8000 sublimate solution. If a considerable portion of the internal malleolus be detached, advantage may be taken of the free exposure of the parts to fasten it in position by plated tin tacks or ivory pegs. A drainage tube is next inserted at the back of the joint, the fracture reduced and cyanide dressings applied, and the leg and foot put up in lateral wire splints (see Fig. 2), which should be sterilised, moulded accurately to the limb and incor-



porated with the dressing; they should be so cut that the foot is at right angles to the leg. The advantage of these wire splints is that, although quite light, they are nevertheless very strong, and they can be removed one at a time when the limb is dressed, without disturbing the fracture which is held steady in the splint on the opposite side; when the dressing on that side is applied, the splint is replaced, the one on the other side removed and the dressing applied to it. Owing to their structure also, these splints allow the discharges to soak into the dressings applied outside them, and thus they may be applied quite close to the skin with only sufficient dressing between them and it to form a padding; they can therefore be moulded most accurately to the limb and made to obtain an excellent hold upon it.

When the fracture is put up, care should be taken to see that the foot is fully inverted; when the wound has healed, the ordinary treatment—by a Croft's splint, massage, passive movement and so forth—may be reverted to.

(c) **Of mal-union.**—Cases are sometimes met with in which reduction has been imperfect or has not been attempted. The result is more or less permanent disablement, so that the patient limps considerably, and often has agonising pain on attempting to walk; it may be necessary to have recourse to surgical intervention to render walking possible. Two procedures suggest themselves for this purpose, one being to divide both bones of the leg and then to forcibly invert the foot, whilst the other consists in reproducing the original injury and then bringing the parts into proper position. Cases have been recorded where the former method of treatment has been employed and the foot brought into position, but the results are not as a rule satisfactory. The astragalus is not in its normal position with regard to the articular surfaces of the tibia and fibula, the ankle remains as stiff as ever and the pain on walking continues.

We ourselves have operated by the second method in two cases in which the fracture had not been reduced, and in both the results were fairly good. A vertical incision, extending from well above the seat of fracture to below the external malleolus, was made over the front of the fibula, and the seat of fracture was divided somewhat obliquely downwards and inwards. A longitudinal incision was next made over the inner border of the tibia, extending nearly into the sole of the foot, and deepened until the lower end of the tibia, the inner side of the joint and the tissues in the neighbourhood were completely exposed. When the joint was opened it was found in both the cases that the internal malleolus had been broken off and had become adherent to the articular surface of the tibia, so that there was no possibility of bringing the astragalus inwards to its proper position on account of this mass of bone and callus. The remains of the internal malleolus were therefore removed completely, and the proper curve of the articular surface was reproduced with a chisel and gouge. The articular cartilage still remained intact over the lower end of the tibia

external to this spot, and it was also unimpaired over the greater part of the astragalus.

A carefully disinfected skein of worsted was next passed around the heel and across the instep and attached to pulleys, by which firm extension was made (see Fig. 49); at the same time the lower end of the tibia was pushed outwards, so that the foot was extended and inverted simultaneously; an assistant also pressed the external malleolus forcibly inwards. Before the latter could be displaced inwards sufficiently, it was necessary to remove some soft tissues between the tibia and fibula, but after a little trouble the parts were completely loosened, the astragalus could then be pushed into proper relation with the lower end of the tibia, and the deformity entirely disappeared.

The wounds were stitched up, and dressings were applied in which were incorporated wire splints that kept the foot inverted and prevented the heel from being pulled backwards. Passive movement was begun early with a view to preventing bony union between the articular surfaces. The results were satisfactory; a considerable amount of movement was obtained, while the trouble of which the patients had previously complained, namely, the impossibility of walking, owing to the great pain on the outer side of the foot, entirely disappeared.

**FRACTURE OF THE LOWER END WITHOUT DISLOCATION.**—The displacement typical of Pott's fracture does not always occur in connection with fractures of the fibula above the malleolus. Thus the injury may force the foot inwards instead of outwards, the result being that the strain is thrown on the external lateral ligament which is usually strong enough to stand the strain, while the fibula gives way at its weakest part, namely, just above the malleolus. There is little or no displacement of the foot in this form, and therefore the condition is not the ordinary Pott's fracture.

**Treatment.**—The simplest and most efficacious method is to apply a Croft's splint when the case is first seen. The later treatment will be on the lines already laid down for Pott's fracture (see p. 157).

**DUPUYTREN'S FRACTURE.**—Another but much rarer fracture is that known as Dupuytren's. This generally occurs when the patient falls from a height and alights flat upon the sole; the astragalus is driven upwards between the tibia and the fibula, the inferior tibio-fibular ligaments are torn, and the fibula is fractured near the lower end of the shaft, usually a little higher up than in Pott's fracture. This rare fracture is generally produced by very severe violence, and it may be accompanied by fracture of the astragalus or os calcis. The diagnosis is much facilitated by the marked broadening of the ankle that is always present, while at the same time there is not as much eversion as in ordinary Pott's fracture. A skiagram of course will clear up any doubts that may exist.

**Treatment.**—This is often a matter of great difficulty. The astragalus is driven up between the bones of the leg and extension is required to

bring it down. The patient should be put under an anæsthetic and the leg fixed by an assistant with the knee bent almost at right angles, while the surgeon makes firm extension on the foot and at the same time presses together the malleoli and inverts the foot. The whole point in the treatment is that the fracture should be satisfactorily reduced as soon as its nature is recognised. As a rule displacement does not recur if the foot be kept firmly inverted so that the upward pressure tells not against the tibio-fibular articulation but against the articular surface of the lower end of the tibia.

After the fracture has been reduced, the leg should be fixed at first in a Dupuytren's and later in a Croft's splint. It will, however, rarely be found necessary to employ continued extension to prevent the recurrence of displacement so long as care is taken to see that the foot is well inverted. The subsequent treatment by massage, passive movement, etc., is the same as after a Pott's fracture (see p. 157).

#### FRACTURE OF BOTH BONES OF THE LEG.

**Causes.**—These are among the commonest fractures in the body and, apart from the difficulties which not infrequently arise in their treatment, they are very important because a considerable number are compound: according to some authors, as many as one in three or four are compound fractures. They may occur from direct violence such as run-over injuries, kicks, and so forth, in which case the tibia is not infrequently comminuted, the line of fracture more or less transverse, and the fracture compound; more often however they result from indirect violence, when the fracture takes place at the weakest part of the tibia—a short distance above the malleolus—whilst the fracture in the fibula generally occurs higher up, often quite near its upper end. The line of fracture is then generally oblique from below upwards and backwards in both bones. When these fractures are compound it is generally due to perforation of the skin by the sharp upper fragment of the tibia. A variety of other fractures of the tibia, such as spiral fractures, T-shaped fractures, longitudinal fractures and so forth, are described, but the oblique and the transverse comminuted fractures are the two common forms.

**Displacement.**—In a fracture from direct violence there is not necessarily any displacement at first; when the leg is lifted, however, the weight of the foot of course carries the lower fragment backwards. In an oblique fracture from indirect violence the lower fragment is pulled upwards and somewhat backwards, so that the upper fragment of the tibia projects beneath the skin and is apt to perforate it either at the time of the accident or subsequently if the limb be not fixed in proper position. There is some tendency also for the lower fragment to rotate outwards from the weight of the foot; this is especially the case when the fracture is fairly high up the bone.

**Treatment.**—**Simple fracture.**—In treating a simple fracture of the

tibia and fibula in this region the surgeon has to bear in mind the liability that there is for the fracture to become compound; the tendency to shortening and the outward rotation of the foot must be borne in mind.

In a *simple fracture due to direct violence* the bones should be brought into accurate position; the two fragments should be in the same straight line, and there should be no rotation of the foot and the lower fragment. In these cases it is well to take a skiagram in the course of a few days before the parts become consolidated and see if the fractured ends are in good position. If there be much bruising of the skin it is well to disinfect it and to apply a cyanide gauze dressing, lest ulceration or gangrene take place. When this is done, the limb may be put up in a Croft's splint, which should extend from the lower third of the thigh to the root of the toes; care must be taken to see that the foot is at right angles to the leg.

*After-treatment.*—The Croft's splint should be kept on for at least six weeks, but after three or four weeks' confinement to bed the patient may be allowed to get about on crutches, still wearing the plaster of Paris casing, the limb being supported by means of a long sling passing around the neck and beneath the sole. The splint may be left off any time between six and eight weeks, but great care must be taken before this is done to be sure that union has occurred. If the fracture be at all low down, this is sometimes a somewhat difficult matter to be sure of, as, when attempts are made to move the fragments in the antero-posterior direction, the movement of the ankle joint may simulate movement of the fracture. The best direction in which to test the movement is the lateral one; this should never be omitted, because, if the union be only imperfect, the result when the patient comes to bear weight upon the limb will be to markedly increase the mobility.

In the *oblique fractures* of the leg the immediate application of a Croft's splint before the swelling occurs is the best procedure; even if marked swelling has taken place, the proper fixation of the part in this way will often both prevent further swelling and aid the absorption of any that has already taken place. In these cases, of course, the tocs must be very closely watched, and the sensations of the patient as regards pain ascertained lest any undue pressure upon the seat of fracture should ensue; if there be any sign of that, the splint should be undone at once.

*Screwing.*—In oblique fractures of the leg there is often great difficulty in keeping the fragments in position and in preventing a certain amount of over-riding. If this be the case, and if it be ascertained by means of a skiagram or otherwise that there is recurrence of the over-riding after it has been once corrected, it is best to cut down upon the fragments and screw them together. The fracture in the tibia is superficial, no important structures are divided in exposing it, and the result is superior to that obtained by splints, whilst the after-treatment gives no trouble. The best incision is a curved one over the inner surface of the bone with its con-

vexity backwards, extending well beyond the inner border of the tibia. This flap should be turned forwards until the whole breadth of the inner surface of the tibia is displayed. When the seat of fracture has thus been exposed, it should be carefully examined, and all blood-clot, small fragments of bone, or portions of periosteum or muscle that may have got in between the fractured ends, should be removed. The broken ends are then united by means of two plated screws introduced, one vertically above the other (see p. 51). To facilitate the introduction of these screws, a special form of forceps which holds the fractured ends in accurate apposition whilst the bone is being bored and the screws introduced has been devised (see Fig. 17). The fracture of the fibula does not require any attention. The wound is then stitched up and dressings applied with wire splints incorporated in them, the foot being fixed at right angles and the knee being also enclosed in the splint.

The further treatment is the same as that after any operation for fracture. When the wound has healed, the dressing is removed and a Croft's splint applied, which must not be left off until union has occurred. As in most cases of operation after fracture, it will be necessary to allow a somewhat long period to elapse before the patient is permitted to bear weight on the foot, as union is somewhat slower than in fractures not operated upon. Massage should be employed after the first three weeks so as to prevent as far as possible the œdema which is otherwise likely to occur when the patient is allowed to walk.

Apart from the question of the displacement of the fragments, it may be necessary in some of these cases to cut down upon the fracture when the surgeon cannot satisfy himself that the bony surfaces are properly in contact. It is not uncommon for the ends of the bones, especially the upper end of the lower fragment, to perforate the muscle and become entangled in it and thus a certain amount of muscular tissue is interposed between the ends of the bones, and proper union is prevented. In other cases the fracture may be somewhat comminuted, and a detached portion of bone may become so displaced between the fragments that they are prevented from coming into proper apposition. If when reducing the fracture therefore, no proper crepitus be found (which would show that there is something interposed between the ends of the bone), or if it be impossible to reduce the fracture properly, there is sufficient reason for cutting down upon the fragments and removing the obstacle; of course if this be done, it is well to take advantage of the opportunity to fix the fragments firmly together by pegs, screws or wires, as the occasion may seem to demand.

When the injury has resulted from direct violence it is not usually necessary to operate, for the displacement is not so marked; operation will only be called for when the bone is comminuted and some detached portion prevents the fracture being properly set. In all these cases a skiagram will be of great assistance.

**Compound fracture.**—Compound fractures of both bones of the leg

are very common; they must be treated on the lines already laid down for compound fractures in general, the wound if necessary being enlarged and the part thoroughly disinfected in the manner already described (see p. 31). If loose fragments be present between the ends of the bones they should be removed, and if the line of fracture be oblique the fragments should be screwed together; a drainage tube should be inserted and the ordinary gauze dressings applied. It is best to use strong sterilised wire splints incorporated with the dressing as they get a more complete grasp of the limb than any other form of splint; their advantages have already been referred to (see p. 161). Like all compound fractures treated aseptically these cases are much slower in uniting than simple fractures, and very often a prolonged course of rest is necessary in order to obtain firm union.

When the wound is at the back of the leg—which is however rarely the case—the limb is best immobilised by an anterior splint of malleable

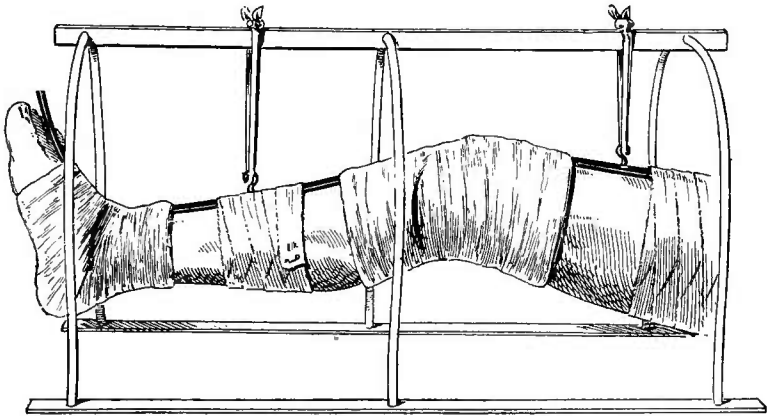


FIG. 63.—ANTERIOR SUSPENSION BAR FOR COMPOUND FRACTURE OF THE LEG. The limb is fixed firmly to the bar by plaster of Paris bandages about the knee and ankle. Between these points is seen the bandage securing the dressing.

iron or two parallel splints, one running down on each side of the crest of the tibia reaching from the lower third of the thigh to the dorsum of the foot, and fastened by plaster of Paris bandages round the upper part of the leg and thigh on the one hand and to the foot and lower part of the leg on the other. A sufficient interval is thus left for dressing the wound, and the splint may be slung in a cradle and the wound got at without disturbing the parts (see Fig. 63). As however there is likely to be some displacement of the ends of the bones, it may be necessary to screw or wire the fracture first and then to sling the limb as above.

**Ununited fracture.**—Ununited fracture of the tibia is fairly often met with; in the fibula the condition is rare. It is more common in fractures due to indirect violence than in those due to direct violence, and it is also common in compound fractures. The causes may be excessive move-

ment, inclusion of portions of muscles, or, not uncommonly, a loose piece of bone, between the fractured ends, or apparently some constitutional defect.

In every case, the ununited fracture will have to be treated by operation, and the best plan is to cut down on the fracture. The other methods of treating ununited fracture which have been mentioned (see p. 49) are very unsatisfactory compared with free exposure; there is no call to employ the other methods in this situation, because the bone is quite superficial, and no important structures need be divided. The operation is in all respects similar to that described for ununited fracture of the tibia alone (see p. 154); a portion of the fibula should be removed if the ends of the tibia will not otherwise come together. For this purpose an incision must be made over the outer side of the leg on the same level as the defect in the tibia, the fibula exposed and sufficient removed to ensure that, when the ends of the tibia are brought together, the ends of the fibula will just meet also. Any obliquity of the fractured surfaces should be maintained and if necessary increased, because it is much easier to fix the ends when the surface is oblique than when it is transverse. If the fracture be oblique, pegs or screws should be used to fix the parts together and the fibula need not be divided, for, as the two ends lie together, they will unite without any trouble. In transverse fractures, screwing or pegging cannot be employed; the best plan is to pass a wire right through the whole substance of the bone below the fracture, and bring it out again through the whole thickness of the bone above the fracture (see Fig. 64).

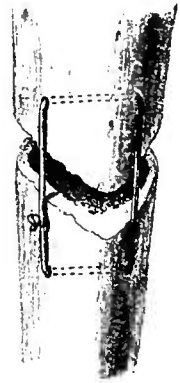


FIG. 64.—METHOD OF WIRING A TRANSVERSE FRACTURE OF THE TIBIA. For the sake of clearness the fragments have not been approximated. In the figure the line of fracture is somewhat oblique; it should be transverse.

#### FRACTURES OF THE BONES OF THE FOOT.

These injuries are not common and may be dismissed in a very few words.

**FRACTURE OF THE ASTRAGALUS.**—Fracture of this bone alone is an injury of extreme rarity; we ourselves have never come across a case. The fracture results from falls from a height upon the foot; the bone may then fracture instead of becoming dislocated. Usually the anterior part is displaced forwards, the fracture being frequently through the neck of the bone.

**Treatment.**—The treatment must be a difficult matter and will depend essentially on the condition of the astragalus; in any case it would probably be advisable to cut down and find out the condition of the bone, and in the majority of instances it would seem desirable to completely excise

the astragalus. The results as regards movement of the foot after extracting the astragalus are remarkably good, whereas if the piece of broken bone were left in the ankle it can hardly be imagined that a satisfactory result could be obtained. Some information as to the exact condition of the bone might be obtained by a skiagram.

**FRACTURE OF THE OS CALCIS.**—The most common fracture of the bones of the foot is fracture of the os calcis, which may occur from falls from a height upon the heel or from the foot being run over by a heavy waggon. The result is often complete comminution of the upper part of the os calcis, or the posterior portion to which the tendo Achillis is attached may be broken off.

**Treatment.**—We shall refer to the treatment of two conditions, namely, that in which there is an extensive comminuted fracture, and that in which the posterior portion is detached. When there is an extensive *comminuted fracture* of the os calcis the heel feels like a bag of bones and it is a difficult matter to bring the parts into good position. The best plan under these circumstances is to hold the heel in position while the patient is under an anæsthetic and to put on a plaster of Paris casing so moulded as to bring the heel and the os calcis to a proper shape; this is held whilst it sets, and the foot can then be slung with the knee bent so as to relax the calf muscles. In these cases any resulting disability will be in connection with the transverse tarsal joint, not with the ankle joint, and the apparatus should therefore be taken down from time to time for the performance of passive movement, especially in the direction of adduction and abduction of the transverse tarsal joint. Special care should be taken to prevent the occurrence of a valgus condition.

In *compound fracture* of the os calcis the treatment must of course be on the ordinary lines for the treatment of compound fracture, but if the bone be hopelessly broken up or if the chance of getting the part aseptic be very slight, it is perhaps as well simply to excise all the loose fragments; the parts that are intact with periosteum covering them may be left and will help to form a new os calcis. The results of excision of the os calcis under these conditions are so very satisfactory that it is hardly worth while running any serious risk in order to preserve a quantity of loose pieces of bone which are very apt to become septic.

When there is *fracture of the posterior part* of the os calcis, and when the fragment is tilted or drawn upwards by the tendo Achillis, the best procedure is to turn down a flap with its convexity upwards and peg or tack the fragment of bone into position; the flap should reach high enough up the back of the ankle to escape friction from the hard part of the boot. Unless this be done, a projecting piece of bone will be left which will cause much pain when a boot is worn and will have to be chipped off later.

**Fractures of the other tarsal bones** are comparatively rare except as a result of a general smash of the foot; as they are usually compound



and associated with extensive injury, they do not call for individual description.

**Fractures of the metatarsal bones** may also occur as the result of run-over injuries or kicks, or heavy weights falling upon the foot. As a rule there is little or no displacement in these fractures, the other bones forming splints for the fractured one; all that is necessary is to see that the broken ends are brought into position by suitable manipulation and then to fix the foot in plaster of Paris.

## SECTION II.—DISEASES OF BONES.

### CHAPTER IX.

#### ACUTE AND CHRONIC INFLAMMATION OF BONES.

##### GROWING PAINS.

DURING the growing period, more especially between thirteen and sixteen years of age, young adults often complain of pains in bones and joints. These are due to a congestive condition of the medulla, chiefly in the neighbourhood of the epiphyses, and are popularly termed "growing pains." In some cases the pain may be severe, and accompanied by elevation of temperature, and the condition is frequently difficult to diagnose; it is very likely to be confounded with commencing joint trouble, or, on the other hand, commencing joint trouble may be mistaken for "growing pains." The diagnosis is soon cleared up, however, because this condition passes off in the course of a few weeks if the patient be kept in bed; whereas commencing joint disease will not.

**Treatment.**—As there is always a certain amount of difficulty in diagnosing this condition from commencing joint disease, or from tumours in the interior of bones, etc., it is better at first, if there be any doubt, not to express a definite opinion, but to treat the case as if it were one of these graver affections. The patient should be kept in bed, with the limb fixed on a splint. Fresh air, good food, and warmth are also desirable; quinine and alcohol in small quantities are sometimes good. If the case be one of simple congestion in connection with growth, the pain very soon passes off, and no swelling will appear.

##### ACUTE INFLAMMATION OF BONE.

In studying the inflammatory affections of bones it is necessary to consider not only the bone proper but also the periosteum and the medulla; thus we may speak of inflammation of the periosteum or periostitis, of

inflammation of the bone itself or osteitis, and inflammation of the medulla of the bone or osteo-myelitis. When the periosteum is inflamed the bone beneath is affected also, and when the medulla is inflamed the bone and the periosteum are also attacked; so that it must be remembered that all three forms are included under each head, the individual name given to the particular affection varying according to which of the three tissues is the principal seat of the disease.

Inflammation of bone may be *acute* or *chronic*; acute osteitis may be suppurative or non-suppurative, while the chronic inflammations of bone may be divided into the simple, the tuberculous, and the syphilitic.

**ACUTE NON-SUPPURATIVE OSTEITIS.**—It is doubtful whether inflammation of bone, unaccompanied by suppuration and deserving the name “acute,” does really occur, and in any case it is a very rare condition; indeed, it is a matter of much doubt whether even a truly acute periostitis can occur without a pyogenic infection. A form of acute periostitis has been described by Ollier under the name of “albuminous periostitis,” in which exudation of a serous or albuminous nature occurs beneath the periosteum, but this is probably only a mild form of the suppurative variety; it has been said also to be due to pyogenic cocci.

Inflammation of the periosteum sometimes occurs during typhoid fever, but in most instances this ends in suppuration, and is either due to the typhoid bacillus itself or else to an infection by the pyogenic organisms.

**Treatment.**—The affection does not call for extended notice. If it were to occur, the treatment would clearly be to cut down upon and freely divide the periosteum at once. As this is the best treatment in the early stages of the suppurative form, the remarks that follow will apply to this affection.

**ACUTE SUPPURATIVE OSTEITIS.**—This disease is usually spoken of as *acute osteo-myelitis*, because the inflammation almost always begins in the medulla of the bone, although in a few cases, no doubt, the deeper layer of the periosteum is the primary seat of the inflammation.

**Causes.**—Acute suppurative osteo-myelitis is an acute inflammation of the medulla, ending in suppuration, which occurs especially in young subjects, and which may be followed by a general pyæmic infection. The disease may begin spontaneously or may follow an injury, such as a compound fracture; it is due to the pyogenic organisms, generally the staphylococcus pyogenes aureus, sometimes the albus, very rarely the streptococcus pyogenes. In the spontaneous form these organisms are deposited from the blood, whence they are derived from some preceding inflammatory condition, such as a boil. The disease is not uncommonly preceded by digestive disturbance and diarrhœa, and in these cases the organisms probably gain entrance from the intestinal tract. Very often some local injury, such as a slight blow, a sprain, pressure, or exposure to cold, determines the localisation of the disease in a particular part. *The spontaneous form* appears during the period of growth, most commonly

between fourteen and eighteen years of age; very rarely after twenty. It is more frequent in boys than in girls. The disease generally begins in the medulla of the parts of the bones which are growing most rapidly, especially in the neighbourhood of the epiphyseal line; its commonest seats are the lower end of the femur, the upper end of the tibia and the humerus and the lower end of the radius. Of the short bones the os calcis is perhaps the one most frequently affected. *The traumatic form* may occur at any age, and its situation will of course be determined by that of the injury.

**Pathological Changes.**—It is rare for the disease to begin beneath the periosteum, most of the cases of suppurative periostitis being secondary to osteo-myelitis. The affected area of the medulla becomes greatly congested, the effusion fills up the Haversian canals and the medullary spaces, and accumulates beneath the periosteum; the disease is therefore practically always a combination of acute periostitis and acute osteo-myelitis. Suppuration takes place rapidly, the medulla becomes infiltrated, the periosteum thickened and swollen, and pus forms in both situations, sometimes after a communication has been established between the two, but often before any hole has been formed in the dense bone.

In young children the disease may remain localised to the neighbourhood of the epiphyseal cartilage, and is then termed *acute epiphysitis*; this condition may very quickly end in destruction of the epiphyseal cartilage, or at any rate in solution of continuity between it and the shaft. More commonly, however, some portion of the latter becomes involved.

If no surgical treatment be adopted and the patient survives, necrosis of a portion of the bone almost always results; hence the term *acute necrosis* is often applied to this disease. The bone that dies is principally the dense shaft; the necrosis may involve the whole length of the diaphysis, or it may be limited to a small area in the vicinity of the epiphysis. It may also involve the entire circumference of the shaft, or only a part of the central or peripheral portion. The sequestrum generally consists mainly of the outer portion; at some part the whole thickness of the shaft may be involved, but seldom the whole circumference. The abscess bursts externally, and numerous openings through the skin may form later on, leaving sinuses leading down to the sequestrum which persist as long as the dead bone remains.

When the abscess bursts, the severity of the inflammation usually subsides rapidly, and separation of the dead bone commences. The length of time required for the separation of a sequestrum depends very much on the bone affected. When a large dense bone like the femur is attacked, the necrosed fragment may not be quite loose for several months—six or more—whereas if a smaller long bone, such as a phalanx, be the seat of the disease, separation may take place within six weeks.

While the dead bone is being separated, the periosteum becomes thickened, and new bone is formed from its deeper surface, so that by the time

the dead fragment is loose, a layer of new bone will be formed all around it, enclosing it in a cavity, and only leaving a few apertures (termed "cloacæ") in the surrounding new bone, through which the pus escapes. When the sequestrum is removed, it is often very difficult to believe that the dead portion originally formed part of the outer surface of the bone, so deeply is it often embedded in dense new bone.

**Symptoms.**—These will depend on the virulence of the causal agents, and the extent and situation of the disease. In any case there is usually violent fever and great pain; the fever soon becomes of the typhoid type, being accompanied by a small rapid pulse, headache, thirst, dry tongue, stupor or delirium, and the disease is often mistaken for typhoid fever. The pain is generally intense, and if the bone be superficial there is soon swelling over it; the skin becomes red or livid, and fluctuation occurs. On incision pus escapes and the bone is felt to be bare in parts, while in others the periosteum peels off readily. When the bone is deeply seated, or when the main symptoms are confined to the medulla, the swelling and redness may not appear so early, but in any case the pain is extreme. In bad cases there may be complete separation of the epiphysis from the shaft, and in others very grave symptoms and rapid death. When the disease is in the neighbourhood of the epiphysis, the joint in the vicinity often becomes inflamed and swollen, though not necessarily infected and suppurating. If suppuration occurs in the joint, the prognosis is very bad indeed.

**Results.**—The course which the disease will take depends very much on the particular form of the affection, and the treatment adopted. The patient may die before an abscess has time to form,—sometimes as early as the second or third day,—from septic intoxication or acute septicæmia; in other cases death occurs from pyæmia, septicæmia, ulcerative endocarditis, fatty embolism, etc., or at a later period from exhaustion and waxy degeneration of internal organs resulting from the continued suppuration consequent upon the necrosis. Early treatment may save even very bad cases; under any circumstances, however, the prognosis is always grave, both as regards the immediate and the final result. The probability is that the patient will have a long illness, that there will be serious derangement of the neighbouring joints, and that, when the epiphysis is affected, deficiency in growth and deformity will result, the exact amount depending upon the extent of the disease, and the age of the patient at the time of the attack.

The above remarks apply to acute suppurative inflammation of bone as it arises spontaneously; but the disease may occur in septic wounds where bones are divided, *e.g.* amputations, compound fractures, etc. Under these circumstances the infection spreads up through the medullary cavity, and also frequently beneath the periosteum at the same time. The result is that, if the patient lives, there is usually necrosis of the whole of the lower end of the bone, which extends upwards for a considerable distance along

the shaft; not infrequently other small independent sequestra are found at a higher level, especially in the central part of the bone.

**Treatment.**—In speaking of the treatment of acute suppurative inflammation of bone, we shall find it most convenient to consider it under the following heads, viz., the treatment of (1) acute suppurative periostitis, (2) acute suppurative osteo-myelitis, (3) acute epiphysitis, (4) those forms accompanied with suppuration in the neighbouring joints, (5) acute periostitis and osteo-myelitis following injury to bone, and (6) acute suppurative osteitis of the flat bones; further, in all these forms, we have to consider the question of the removal of the dead portions or sequestra at a later period in the disease.

(1) **Of Acute Suppurative Periostitis.**—It has been already said that it is rare for the periosteum to be primarily affected with suppurative inflammation and that it is usually secondary to an acute osteo-myelitis. But cases of acute suppurative periostitis without any implication of the medulla undoubtedly do occur. The general symptoms are then usually somewhat less severe than in acute osteo-myelitis, and the swelling of the part and the redness of the skin appear sooner.

**Incision.**—As soon as the diagnosis is made, the affected part of the bone should be cut down upon, the periosteum divided, and the pus evacuated. When there is a considerable collection of pus beneath the periosteum three or four days after the commencement of symptoms, the case is probably one of primary periosteal inflammation, and the medulla need not be opened up at once. Were the healthy medulla opened, it might readily become infected and produce a still more serious condition; the whole of the bone from which the periosteum is separated should however be examined for a soft spot leading to the medulla and indicating a point of perforation from within. The incision should always be free enough to expose the whole of the affected area; a small incision is quite useless. The incision must, of course, be planned in accordance with the anatomy of the part.

*After-treatment.*—After the operation the wound may be lightly stuffed with gauze to keep the skin edges apart, but it must not be packed so tightly as to interfere with the escape of discharge; one or two large drainage tubes should be pushed down to the bottom of the wound among the packing unless the affected bone be quite superficial. If the operation be done with all antiseptic precautions it is remarkable how little bone may die—sometimes none at all. It is not improbable that if, in the first instance, only a thin scale of bone is deprived of its vitality, this will be gradually absorbed without separating as a sequestrum, whereas this would not be the case if fresh infection were allowed to enter from without.

If, however, after twenty-four hours, the constitutional symptoms still continue as severe as they were before the operation, the presumption is that there is osteo-myelitis present as well, and therefore the stuffing should be removed, the edges of the wound held apart, and the medulla opened and treated in the manner to be immediately described (see p. 175); if, on the

contrary, the symptoms subside in two or three days, the stuffing may be removed and the wound stitched up again except at the lower end where a drainage tube should be retained and kept in position until it is gradually pushed out by the granulations. If there be no sequestrum present, the wound will heal readily enough; if one is going to form it will be evidenced partly by the presence of a sinus and partly by the presence of bare bone which can be felt with a probe. But it must not necessarily be assumed that a sequestrum will of necessity separate in cases of acute periostitis because bare bone is felt for two or three weeks after the abscess is opened. If the bone continues bare for six weeks or a couple of months, then no doubt the great probability is that a sequestrum will have to be removed later on.

(2) **Of Acute Osteo-myelitis.**—Here the danger mainly arises from the confinement of the pus under pressure within the medulla, and the patient's safety depends to a very great extent on the pus finding an exit either naturally or artificially at an early period.

**Osteotomy.**—Directly the diagnosis of acute osteo-myelitis is made, no time should be lost in trying palliative measures; a free incision should be at once made down to the bone. By a free incision is meant not merely one through which the finger can be introduced, but an incision extending over the whole of the affected part of the bone. The periosteum should be incised, and the hard shell of the bone should be cut away so as to expose the medulla. This may be done by means of two or three large trephine holes afterwards joined together by a chisel and hammer, or the whole part may be laid open by a chisel or gouge and hammer. The medulla will be found very vascular, and generally infiltrated with pus; usually a drop or two of pus exudes as soon as it is opened. All this soft inflamed and infiltrated tissue should be thoroughly scraped away and the cavity sponged out with undiluted carbolic acid. Although a very free opening should be made into the medulla, it is not necessary to lay it open from top to bottom when a large extent of bone is involved; it suffices to make two or three large openings into the bone and through them to scrape out and disinfect the whole of the medullary cavity.

Although in the patient's depressed condition it is inadvisable to perform a more severe operation than is absolutely necessary, still there must be no hesitation in getting very free access to the medulla. In all probability the bone exposed by the first incision will in any case die; and it is possible by cutting it away freely to actually remove the whole portion which would have died, and so to ensure a proportionately rapid recovery.

*Drainage.*—After the medulla has been thus opened up and disinfected, drainage tubes should be introduced into it, and pieces of iodoform gauze may be put in between the tubes to keep the skin edges apart. This gauze packing should not extend into the depth of the wound; if the latter be stuffed tightly, as is sometimes done, the pus may be confined

and its free escape from the medulla of the bone prevented. The only object of putting in stuffing is to hinder the edges of the skin and the separated muscles from coming together; which would prevent healing from the bottom. The wound must be kept completely open for a few days and afterwards drained thoroughly. If a long trough has been made in the bone, it is a very good plan to stitch up the greater part of the wound as soon as the acute stage of the disease has passed off or to deal with it in the way to be presently mentioned in speaking of the removal of the sequestra.

*After-treatment.*—The limb must be put on a splint, the joints above and below the affected bone fixed in the position in which they will be most useful afterwards, and the case treated antiseptically, the general health being well attended to. This fixation should not be continued too long; provided the joints be healthy, daily passive movements ought to be begun as soon as the acute stage has passed off. The joints not uncommonly become stiff from the inflammatory swelling of the tissues around, quite apart from any actual infection. Moreover, they may not move properly afterwards because the muscles in the vicinity of the affected bone may become adherent to it, or their individual muscular bundles may be matted together. For these various reasons movement of the joints is desirable as soon as the acute inflammation has subsided; at the same time the healing of the wound might be very materially interfered with if the patient were allowed to move the joint himself, especially if he were to walk about, and therefore only passive movement should be carried out at first. As healing progresses, however, the patient may be allowed to perform some movements himself, but in any case the part should be kept elevated; in the case of the lower extremity the recumbent position should be maintained until the wound has healed. Should any portion of the bone die, healing will, of course, not occur until the sequestrum has been removed; this subject will be treated of presently.

*Complications.*—Among the chief risks of acute osteo-myelitis are septicæmia and pyæmia, and, in spite of free and early operation, the patient may still succumb to these diseases. If symptoms of *pyæmia*, such as rigors, etc., occur, the state of the main veins of the limb should be examined to see whether any of them are thrombosed, and if so, whether the affected portion can be cut off from the general circulation (see Part I., p. 214). In many cases, however, and especially in the deep-seated bones, this cannot be clearly ascertained, because the veins leading from the bone are deeply seated, and the thrombosis may not have extended to the larger vessels. Under such circumstances, amputation through the joint or bone above should be at once performed, as it offers almost the only chance of recovery. If a thrombosed vein be found in the amputation stump it should be dissected out well beyond the thrombosed region and removed. Amputation is no doubt very



dangerous when the patient is in this serious condition, but it is practically the only way of thoroughly and satisfactorily removing the septic clots. ●

When the process is apparently more in the nature of a *septicæmia*, amputation is not to be recommended because the infection is probably then no longer local, and the amputation would so weaken the patient as to prevent the body maintaining a successful struggle against the organisms. All that can be done is to see that the local conditions are made as favourable as possible, and to conduct the rest of the treatment on the lines already laid down in speaking of *Septicæmia* (see Part I., p. 210).

**Amputation.**—Apart from *pyæmia*, amputation may be the best treatment in other cases, such for example as acute osteo-myelitis in old people. We have known this condition to arise in old people after a simple fracture when an acute abscess was present in the limb, or even elsewhere in the body; should it occur we are bound to conclude that immediate amputation is the best practice when we consider the age of the patient, the diminution in his resisting power, the length of time that will elapse before the separation of the sequestrum, the consequently prolonged suppuration, the serious operation that may be required for the removal of the sequestrum, and the length of time required for healing, which indeed may never occur. Amputation is also often necessary in cases of long-standing necrosis in old people, but this is a point that will be specially referred to in the following chapter.

**Resection of the entire diaphysis.**—The periosteum of the entire diaphysis may be completely separated from the bone, when the whole shaft, detached at both epiphyseal lines, dies. This condition does not however necessarily require amputation, for very good results have been obtained by removing the dead diaphysis; for example, in the tibia, this can easily be done through a skin incision extending from one end of the bone to the other, and little more is required than to lift out the dead fragment. If at any part the periosteum be still adherent to the bone, it should not be peeled off, but a thin layer of the surface of the bone should be removed by a chisel and hammer, and left adhering to the periosteum; this gives a better chance of securing the formation of new bone, although even when the periosteum is separated by the inflammation, the deeper osteogenetic layer is often separated along with it. Wherever the diaphysis is still adherent to the epiphysis, a piece of the adherent diaphysis should be left, in the hope that a portion of the epiphyseal cartilage may remain undestroyed.

After the dead shaft has thus been removed, the greater part of the wound should be stitched up and drainage tubes inserted at various points. Sometimes there may be almost complete reproduction of the shaft, especially if the precaution just mentioned, as to chipping away a layer of the surface of the bone, be attended to. In some cases, however, this does not happen, either because the osteogenetic layer has been destroyed by the inflammation or has not been peeled off along with the periosteum, and then it becomes

a question whether anything short of amputation is likely to be of use. Of course, as the epiphyseal cartilage is destroyed in these cases, no further growth will take place, and therefore if the patient be a young child it is an open question whether anything but amputation is likely to give a good result; the answer must depend upon the circumstances of the case and upon the particular bone affected.

**Bone-grafting.**—Of the various plans designed to obtain a firm limb under these circumstances bone-grafting has yielded the best results. Before this can be done, the part must be aseptic and, therefore, it is quite useless to introduce pieces of bone into a wound in which sinuses are still present; before anything of this kind can be attempted the wound must have soundly healed. The operation consists in opening up the soft tissues along the line of the deficient bone down to the periosteum and splitting this in two if it can be recognised, and then introducing pieces of bone from some other patient or from one of the lower animals. Perhaps the most convenient animal to use is a young dog. The following are the steps of the operation.

After the skin has been thoroughly purified, a free incision is made over the deficient bone. The thickened remains of the periosteum are incised, and a bed is made for the new bone. The wound is then stuffed with sponges to arrest the bleeding, and covered with gauze dipped in a 1-2000 sublimate solution. It is better not to use a tourniquet, because it gives rise to prolonged after-bleeding, which is apt to separate the bone-grafts from the tissues; the oozing should be allowed to stop before the grafts are inserted. The animal selected is then killed by an assistant and rapidly skinned, the carcass doused with 1-2000 sublimate solution and placed on an aseptic board or tray covered with a carbolised towel. With a fresh sterilised knife and forceps the muscles are rapidly peeled off the bone—the best one for the purpose is the humerus—the periosteum being left undisturbed, and a portion is removed by cutting pliers. The length of the individual grafts is not a matter of much importance; they can be as long as the wound, but they must not be too thick or too broad, and it is well therefore to split the bone longitudinally into fragments with a stout knife. A series of these fragments are laid in the wound after removal of the sponges, until a sufficient amount has been introduced. The skin wound is then closed without a drainage tube, an antiseptic dressing applied, and the part put on a splint, on which it is kept at rest sufficiently long for consolidation to occur. If the operation be done aseptically, no infection of the part will take place, and the pieces of bone do not separate; they gradually become welded together and united with the surrounding tissues, and to some extent they lead to the formation of new bone. Unfortunately, in a good many cases absorption goes on to such an extent that the limb becomes weak again, but in some instances very satisfactory results have been obtained. It is better to use bone from one of the lower animals than from another

patient (for example, from an amputated limb), because of the possibility of transmitting disease thereby.

**(3) Of Acute Epiphysitis.**—As has already been said, acute osteomyelitis occurs especially near the epiphyseal ends of bones, and in young children it is often entirely limited to the region of the epiphyseal line, —when it goes by the name of acute epiphysitis. Under these circumstances the epiphyseal cartilage is very apt to be completely destroyed, and after recovery takes place, no further growth of that end of the bone occurs. Hence very material shortening of the limb may result when the epiphysis affected is the one from which the main growth of the bone is derived.

In the treatment of the acute stage of acute epiphysitis, we have nothing to add to what has already been said with regard to acute osteomyelitis in general. Free incisions must be made down to the part as soon as possible, the periosteum divided, and the bone gouged away on the diaphyseal side of the epiphysis so as to open it up thoroughly. The further treatment, and the treatment of complications, is the same as that already described.

**Treatment of the resulting arrest of development.**—The only point to which we need refer in connection with acute epiphysitis is the deficient growth of the bone afterwards; this condition is not only very serious from the general shortening of the limb it gives rise to, but is particularly troublesome when one of two parallel bones is affected. For example, if the tibia or the radius be the seat of acute epiphysitis, and the epiphyseal cartilage be completely destroyed, the unaffected bone (*i.e.* the fibula or the ulna) continues to grow, and may cause great deformity of the foot or hand. We may take as an example a case in which the epiphysis of the lower end of the radius is destroyed; further increase in the length of the radius only occurs to a very slight extent, and the ulna continuing to grow, gradually pushes the hand over towards the radial side. When the disease occurs in early infancy complete uselessness of the hand may eventually result.

*Destruction of the healthy epiphyseal cartilage.*—With the view of preventing this, some surgeons have proposed to destroy the epiphyseal cartilage of the healthy bone. The great objection to this in the early stage of the disease is, however, that it is impossible at first to be quite sure that the cartilage of the bone affected is really destroyed; it sometimes happens that growth occurs in cases in which it has been supposed that complete destruction of the cartilage had taken place. Hence this suggestion is not really applicable during the early stage; but when two or three years have elapsed, and it is evident that no growth is taking place, it is well worth considering. When, for example, the lower epiphysis of the tibia has been destroyed, it would be well to destroy the epiphysis of the lower end of the fibula two or three years after the epiphysitis, if deformity is occurring. In the fore-arm, however, the lower epiphysis of the ulna has very little to do with the growth of the bone and this method can hardly be employed.

*Resection of portions of the unaffected bone.*—An alternative procedure is to allow the bone to grow and the deformity to take its course, and then to excise portions of the growing bone, so as to bring the foot or hand straight again. In the example just mentioned, enough bone might be taken from the ulna after growth was complete to enable the hand to come into proper position. The choice between these procedures will be decided essentially by the age of the patient when first attacked by the disease, that is, it depends upon the amount of growth which has yet to take place and therefore upon the degree of deformity likely to ensue. If, for example, several years must elapse between the occurrence of the disease and the completion of growth, the chances of getting a useful limb by taking out portions of the unaffected bone are comparative slight if operation be delayed until growth is complete, because by that time the joint surfaces will have so altered and accommodated themselves to their new positions that they cannot be readily righted, and further, the tendons, muscles, and other structures will all have become altered in accordance with the deformity. Hence, if this second method be preferred, it should be employed long before the bone has attained its full growth, and should be repeated if necessary.

This plan is most likely to be of use in the lower end of the fore-arm; the lower epiphysis of the ulna has but little share in the growth of the bone, and it is therefore no advantage to destroy it. The surgeon must therefore content himself with excising a portion of the ulna comparatively early (within two or three years after the occurrence of the disease), so as to allow the hand to come straight; should vicious growth again occur, the operation may be repeated. The bone section should be oblique and the cut surfaces should be wired together; otherwise the hand is apt to resume its vicious position and an interval will be left between the bones which will lead to non-union.

*Amputation.*—When the disease occurs in very young children, the question of amputation may have to be considered; it must depend upon the prospects of obtaining a useful limb, which, in its turn, will depend upon the amount of destruction of the epiphyseal cartilage, and the share that the latter plays in the growth of the particular bone.

**(4) Of acute suppurative osteitis accompanied by joint suppuration.**—This is a very grave condition which often ends fatally; it is a combination of two very serious affections—osteomyelitis and acute suppurative arthritis.

**Amputation.**—In the majority of these cases the first thing to be considered is the advisability of amputation, and if the patient be seen before he has passed into the septicæmic stage and the case has thus become hopeless, amputation immediately above the affected joint is the best treatment. Unless the osteomyelitis has spread into the bone above, there is no need to amputate at any great distance beyond the joint affected.

Amputation is very often the best treatment, because, even if the limb

were saved, it would be stiff, undeveloped, and useless afterwards. The acute arthritis usually occurs in conjunction with acute osteo-myelitis in the neighbourhood of the epiphysis, that is to say, acute epiphysitis, and therefore if the patient recovers, the surgeon will be confronted not only with a disorganized joint but also with a limb in which there is arrest of growth; the two conditions combined will ultimately render the limb useless, especially if the patient be young at the period of onset of the disease.

**Osteotomy and Arthrotomy.**—In some cases however the symptoms are not so severe and it may suffice to make free incisions into the joint in addition to opening up the medulla as described above. This arthrotomy should thoroughly expose and evacuate every recess, and drainage tubes and, if necessary, continuous irrigation should be employed; it will be best to place the limb in a bath (see Part I., p. 30). Unless however the symptoms rapidly improve under this treatment, it should be given up and amputation performed; if a too prolonged attempt be made to save the limb the patient's life may be endangered.

**(5) Of acute suppurative osteo-myelitis and periostitis after an open wound.**—The foregoing descriptions refer only to these diseases as they occur spontaneously, that is to say, without an external wound; sometimes they follow an external wound, for example, an amputation, an excision, or a compound fracture. Here the organisms spread into and along the medulla and under the periosteum with great rapidity and lead almost certainly to necrosis of the whole thickness of the lower end of the bone, and very often to the formation of sequestra reaching for some distance upwards. The condition is very likely to be accompanied by pyæmia.

**Amputation.**—The best procedure in cases of acute necrosis following amputation wounds seems to be re-amputation of the limb. In compound fractures also, unless the osteo-myelitis be very limited, amputation should be done. The re-amputation should be performed through the neighbouring joint or the bone above. It would be useless to attempt to amputate through the same bone, partly because there is generally not enough of it left to be of any value, and partly because it would be impossible to be sure of getting above the disease. Waiting for the separation of the sequestra in these cases is a procedure of very doubtful value.

**(6) Of acute suppurative osteitis of the flat bones.**—So far we have been speaking of the acute suppurative osteitis as it affects the long bones; in some cases it may attack either the short or the flat bones. It is not very uncommon in the skull, the scapula, or the bones of the foot; in most of these instances, however, it occurs after an open wound.

When there is an acute osteo-myelitis of the skull, the chances of recovery are extremely small. The treatment must be on the same lines as those already laid down. The diploë must be opened by a trephine

and the affected medulla removed; in most cases it is well to trephine through both tables of the skull, because the whole thickness of the bone is apt to die, and suppuration will then occur between the dura mater and the bone. This will be referred to more in detail when dealing with inflammation of the cranial bones.

When the scapula is affected, complete excision is the simplest and best practice if the whole bone be diseased. When only a portion is attacked it is not worth while opening up the bone; all the bone visibly affected should be cut away. In the small bones, such as the tarsal bones, excision of the affected bone may suffice if the inflammation be limited to a single bone, but there is generally suppuration both of bones and joints, *e.g.* after a compound fracture or injury to the joints, and in these cases amputation is the only remedy.

#### CHRONIC INFLAMMATION OF BONE.

Chronic inflammation of bone may occur, affecting chiefly the periosteum on the one hand and the medulla and adjacent bone on the other. This may follow the acute form, but usually it is chronic from the first.

**PATHOLOGICAL CHANGES.**—In *chronic periostitis* there is great thickening of the periosteum itself and marked formation of new bone beneath it, along with condensation of the pre-existing bone; so that in chronic periostitis there is always a certain amount of osteitis. In *chronic osteo-myelitis* the result as regards the bone is either softening, termed “rarefying osteitis,” or condensation, termed “condensing osteitis,” or a localised suppuration in the bone—what has been described as “Brodie’s abscess of bone.” In some rare cases a sequestrum is formed in connection with this chronic inflammatory condition. The inflammation is not limited to the medulla and the adjacent hard bone, but after a time it extends in all cases to the periosteum, so that the case is a combination of chronic osteo-myelitis and chronic periostitis. Hence, these two conditions cannot be separated from each other as regards treatment. Chronic inflammations usually commence without any acute symptoms, sometimes after an injury, possibly in connection with some constitutional condition, or under other circumstances that we do not exactly understand. We exclude here the chronic inflammation of bone dependent on tuberculosis, syphilis, and possibly rheumatism, though some of these chronic forms may be of so-called rheumatic origin.

In chronic osteo-myelitis going on to rarefying osteitis an abscess may occasionally form, and the rarefying osteitis may extend through the whole thickness of the dense bone, so that an external opening forms. If this be insufficient for the escape of the pus, the chronic inflammation of the bone still persists; and similarly chronic inflammation may go on after an operation for the removal of a sequestrum, where the latter has been

successfully removed, but where a sufficient exit for the escape of the discharge from the cavity has not been maintained.

**SYMPTOMS.**—The periostitis or osteo-myelitis gives rise to thickening of the bone, to tenderness over the inflamed part, and often to a great deal of pain. The characteristic in both cases is that the pain is worse when the limb becomes warm, especially at night when the patient is in bed. Tenderness is usually more marked in chronic periostitis than in chronic osteo-myelitis; while in the latter, on the other hand, pain is more marked than tenderness, and the former is of a neuralgic character. In both diseases the symptoms may for a time subside, but the affection is liable to exacerbations; this is more particularly the case in the chronic abscess of bone where the patient may be comparatively free from pain for months and may then suffer from another severe attack. •

**TREATMENT.**—The treatment of these conditions is either palliative or operative. As a patient will seldom submit to operation in the first instance, we shall mention the palliative treatment first.

**Palliative.**—This consists firstly in rest; secondly, in elevation of the limb so as to improve the circulation; thirdly, in the employment of counter-irritation, either in the form of blisters or the actual cautery, especially in the form of Corrigan's cautery (see Part I., p. 19), and fourthly, in the administration of drugs, of which the chief are iodide of potassium and salicin or salicylate of soda. Apart from the cases of possible syphilitic origin, large doses of iodide of potassium in some instances relieve the pain very markedly; doses commencing with ten grains three times a day, but rapidly going up to twenty or twenty-five grains should be given.

The result of this palliative treatment is almost always merely temporary. It is but seldom that a cure results, even though the treatment be carried out for many months. As a rule, the condition improves for a time and then relapses, for reasons that are not quite clear. Even in cases on which iodide of potassium exerts considerable influence, the large doses must be continued for a long time, as the disease is very apt to recur as soon as the drug is left off.

**Operative.—In young subjects.**—If, after a trial of these measures, it be found that the disease persists, it is advisable to have recourse to operative procedures. The operation consists in cutting down on the inflamed area, removing the periosteum, gouging away the thickened bone, and making an opening into its interior. It does not matter whether the disease be essentially periostitis or osteo-myelitis, the operative treatment is practically the same. The plan of simply making a free incision through the periosteum down to the bone, while it relieves the pain for a time, seldom cures the disease; usually after the wound has healed the pain recurs, and in most cases something much more radical is required.

*Removal of periosteum and gouging of bone.*—In a typical case it is best to cut down upon the periosteum over the whole area of thickening, and to divide it throughout its whole length, from normal periosteum above

to normal periosteum below. The soft parts should be turned aside from the thickened periosteum, and the whole of the latter dissected away. The new periosteal bone is next gouged away over the same region, and then, towards the centre of the inflamed portion, a groove is cut in the bone, until the medullary cavity is opened. In this way the bone is thoroughly opened up, and, should the case be one of osteo-myelitis with abscess, the latter can hardly fail to be opened.

How the gouging of the inflamed bone leads to such remarkable relief of pain and often to complete cure is a matter which is difficult to understand seeing that all the inflamed part is not removed, but we would emphasise the fact again, that if a cure is to be obtained, it can only be reckoned on after a very free removal of the thickened periosteum and the gouging away of the inflamed bone; small trephine holes will not produce such results. It has been proposed to bore holes with a bradawl, to make small holes with a trephine and so forth, but as compared with the free removal of bone with chisel and hammer and gouge these methods have nothing to recommend them and with them one is very apt to overlook an abscess cavity.

*Drainage of an abscess.*—When an abscess cavity is exposed, it should be opened thoroughly so that there is no recess left, and the superficial opening in the bone should be quite as large, if not larger, than the abscess cavity itself; the whole lining membrane of the abscess should be thoroughly scraped away, and in fact it is well also to remove some of the condensed bone which forms the wall. If a sequestrum be present it should be removed, the granulation tissue in which it lies scraped away, and some of the surrounding bone removed with a gouge. There is no necessity to stuff the wound or apply any antiseptic after having thoroughly opened up the inflamed bone in this manner, because even in the case of chronic abscess of bone it is questionable whether the organisms causing the abscess are alive.

When the bleeding has been arrested, the soft parts can be brought together and the skin stitched up completely; if however free oozing be still going on, it is as well to introduce a small drainage tube at the lower part of the incision, but this should be removed in a day or two. The whole cavity in the bone becomes filled with blood and healing occurs by organisation of clot. In order to obtain as vigorous a clot as possible, it is well not to pour lotions of any kind into the wound after the operation has been completed; it is well also not to make a vertical incision over the part, but to employ the flap method. In the tibia, for instance, a large flap with the convexity backwards may be turned forwards so as to expose the whole bone; the incision will then lie nowhere over the gouged cavity in the bone, which will be all the more likely to heal readily on that account.

*After-treatment.*—After the operation has been completed and an antiseptic dressing applied, the limb should be placed on a splint and movement should not be begun until three or four weeks have elapsed



from the time of the operation, as otherwise the delicate clot which fills up the cavity is apt to break down. For the same reason, when the lower extremity is affected, the patient should not be allowed to walk until at any rate a couple of months have elapsed. In superficial bones such as the tibia, which is the one most commonly affected, there is no tendency for the muscles to adhere to the bone, because the gouged part is generally the subcutaneous inner surface. These operations should of course be conducted strictly aseptically; were sepsis to occur, the results might be very grave; acute suppurative osteo-myelitis or periostitis might ensue and place the patient in the greatest danger.

**In old subjects.**—This treatment is the best in all cases in which the inflammation is limited to a portion of the bone and occurs in young people. When the inflammation affects the whole length of the bone, the results are not so satisfactory. A very extensive operation must be done, as a groove must be made throughout the whole bone, and much periosteum must be taken away; in old people it is a question whether this is allowable or will suffice. When the whole of a bone is involved the periosteum can only be removed from one side and there is no guarantee against a recurrence of the trouble after operation, because a large portion of the bone will not have been touched. Although the pain as a rule is relieved and there is no further recurrence, still there is no certainty of this and the patient must be exposed to a very serious operation.

Nevertheless cases occur in which the pain is so excessive and long continued, and leads to so much agony and loss of sleep, that the patient will submit to anything rather than allow it to go on. In old people it then becomes a question whether amputation will not give a better result when a very large area of bone is involved. Amputation will certainly cure the disease,—unless neuritis has been set up,—and there will be complete relief of pain, and absence of recurrence after an operation which in old and feeble patients is less dangerous and is followed by a much more rapid recovery than that which we have just described.

## CHAPTER X.

### NECROSIS : PHOSPHORUS NECROSIS.

NECROSIS of bone follows acute suppurative osteo-myelitis and periostitis, and may also result from tuberculous disease, syphilis, or the action of phosphorus; the sequestra in these various cases differ in character, as will be presently mentioned. We shall only consider here the necrosis which follows acute osteomyelitis and the form resulting from the action of phosphorus.

**Characters of a sequestrum.**—A sequestrum presents the characters of normal bone which has died before any alteration has taken place in it as the result of the inflammation. The part of the bone that dies is usually the compact tissue, and the sequestrum may consist of the whole thickness or only part of this. At first the outer surface is smooth, but if a piece of dead bone remains for a long time in the body, it becomes to a certain extent eroded by the granulation cells. It is possible that the greater part if not the whole of the dead bone might be thus absorbed in cases where septic organisms have never been present, or have died out; in ordinary septic cases, however, the absorption that occurs is quite trivial.

**Separation of the sequestrum.**—Under ordinary circumstances a piece of dead bone must become separated from the living portion, and the process of separation varies in rapidity according to the bone affected, the time required ranging, as has already been said, from six weeks to six months from the commencement of the disease. While separation is going on, condensation of the bone around takes place, and formation of new bone from the periosteum proceeds actively. In the long bones in young persons this new formation of bone may go on to such an extent that the dead portion is enclosed in a shell of bone of great thickness before complete separation has taken place, openings (called "cloacæ") leading down to the sequestrum being however left here and there in the new bone. In old people there is rather a stalactitic formation around the necrosed fragment than a true enclosure by bone. In the

flat bones, such as the skull, the production of new bone is not nearly so marked, and there is very seldom anything like complete enclosure of the dead fragment in a bony cavity.

The result of this is that the necrosed bone can rarely be got rid of without operation. Sometimes small fragments become broken off, and gradually work their way to the surface, being pushed out by the granulation tissue, but the main mass still remains, and nothing but an operation will suffice to get rid of it. As long as the sequestrum is present, suppuration persists, and the inflammatory condition of the bone around continues, so that there is steadily increasing condensation of the bone, and fistulæ are formed in the skin, along which a probe can be passed through the cloacæ and made to impinge on the sequestrum. It is often impossible to make out whether the latter is loose or not, because the cavity in which it lies is too small to permit of movement, or because the sequestrum is large, or because it is convex and represents a great part of the surface of the bone; but we know that in any case if six months have elapsed since the acute attack the dead fragment will be loose.

**TREATMENT.**—The treatment consists in removing the dead bone as soon as it is loose. Until then, the application of antiseptic ointments, such as the full strength boracic ointment, and boracic lint, over the sinuses is all that is necessary. There is no object in operating until the dead bone has become loose, and in many cases the time for operating must be determined by the time that has elapsed from the commencement of the trouble rather than by the mobility of the sequestrum. One is often urged to operate on patients with necrosis within a few weeks from the commencement of the disease and very soon after the acute symptoms have subsided, but the dead fragment cannot then be loose, and it would be quite impossible to be sure how much is dead and how much therefore ought to be removed.

**Sequestrotomy.**—In performing the operation it is best, where possible, to control the circulation by an Esmarch's bandage, partly because in a prolonged operation a good deal of blood is lost, and partly because it is difficult to disinfect the part thoroughly if oozing of blood is going on. In some cases high up in the limb it is not possible to apply the bandage satisfactorily and the increased after-bleeding may also be an objection to its use. Nevertheless it is best to employ it whenever possible; the after-bleeding may be checked by plugging the wound very firmly before the bandage is removed.

The incision must of course be planned so as to avoid injury to important structures, more especially nerves, while at the same time it must afford the most complete access to the part, and must be enlarged if necessary during the course of the operation. It need not necessarily be in the vicinity of the sinuses: in fact if better access can be obtained from the opposite side of the limb, the sinuses should be disregarded altogether. The skin and the tissues, including the

periosteum, are divided freely right down to the bone, and then the periosteum is peeled off with a rugine as freely as may be necessary. If the opening in the bone be exposed in the wound, the new bone is chipped away with a gouge and hammer, beginning at this opening, but no attempt should be made to remove the sequestrum until it has been exposed throughout its whole length. If an attempt be made to take it away through a small opening, it is sure to break, and then fragments are apt to be left behind; if this happens the pieces may be difficult to find afterwards, and if left behind they will prevent the wound from healing.

If, on account of the anatomical relations of the part, the area of bone exposed be not that in which the cloacæ are present, the exposed portion should nevertheless be chiselled away until the cavity in which the sequestrum is lying is reached, and then the opening should be enlarged to whatever extent may be necessary. The most difficult cases are those in which the necrosis has involved a considerable segment of the bone and the sequestra are curved in shape, so that a single opening in the bone will not suffice for their removal. It may then be necessary to make an incision on the opposite side of the limb and chip away bone there, and then possibly to break the sequestrum in two and remove part through the one incision and part through the other. In any case the important points are not to make too small an opening in the bone, to obtain free access to the cavity, and to remove the sequestrum in one piece if possible.

After the sequestrum and the chips of bone which have resulted from the chiselling have been removed, the granulation tissue in the interior of the cavity is thoroughly scraped away. In doing this, care must be taken to ascertain that no other sequestrum is present, and that the whole area has been completely cleared out. As these cases are septic, it is advisable afterwards to sponge out the whole cavity thoroughly with undiluted carbolic acid, and to excise any sinus in the soft parts. It is well afterwards to stuff the hole in the bone with cyanide gauze sprinkled with iodoform; this should be done before the elastic bandage is removed, and firmly enough to stop the oozing. The ordinary cyanide gauze dressings and salicylic wool are then applied outside, and the limb placed on a splint which fixes the neighbouring joints.

*After-treatment.*—The further treatment of the cavity left after removal of the sequestrum depends to a great extent on whether or not the surgeon has been able to thoroughly disinfect the cavity. In any case the stuffing should be left in for two or three days. As there will generally be considerable oozing, it is well to change the outer layers of the dressing on the day after the operation; but it is not necessary on this occasion to attempt to remove any of the stuffing unless there be signs of sepsis. It suffices to wash the wound and the surface of the packing with 1-2000 sublimate solution, and then to apply another antiseptic dressing of cyanide gauze and salicylic wool; the limb is of course replaced

on the splint. This dressing may be changed again on the following day or it may be left for two or three days, according to the amount of discharge and the general symptoms.

In three or four days it will be evident whether or not sepsis has been eradicated. In the latter case a little pus will begin to form, and the stuffing can then readily be removed, at any rate from the greater part of the cavity, because it will have become separated from the tissues by a layer of pus. If, on the other hand, the wound be aseptic, there will be no sign of suppuration, and it will be a matter of considerable difficulty to remove all the stuffing. About this time, viz., about the fourth or the fifth day, the treatment of the cavity must be decided upon. The process of healing from the bottom in deep-seated bones takes a very long time—often many months—and sometimes it does not occur at all. The dense bone surrounding the cavity has to form granulations, which have to grow up and fill the whole cavity before the healing process is complete; and in the meantime healing goes on rapidly in the soft tissues over the orifice. The result is that the external opening steadily diminishes in size and is very likely ultimately to become too small for the escape of the discharge from the deeper parts; besides this, the skin becomes drawn in on each side of the opening, so that there is a deep sulcus, at the bottom of which are sinuses leading into the cavity in the bone. In fact, in some cases sinuses remain for a very long time, and indeed may never close.

**Methods of obtaining obliteration of the cavity in the bone**—Hence the general opinion now is that it is inadvisable to let these wounds heal from the bottom by the growth of granulation tissue, except in the case of superficial bones, such as the tibia; steps should be taken to obtain a more rapid filling up of the cavity and to obviate this drawing-in of the skin. Exactly what should be done will depend very much on whether or not sepsis has been completely eradicated; should the case be aseptic, one of the following procedures should be adopted about the fourth or fifth day.

(a) **In an aseptic wound.**—(1) The skin may be loosened at the edges and stitched together over the cavity, which then fills with blood-clot, in which organisation takes place later. With this plan the difficulty is that if there be much clot—in other words, if the cavity be large—organisation is apt to be imperfect, and portions of the clot may break down before it has occurred. Hence, this method is not usually satisfactory.

(2) In order to entangle the blood, and to form a network in which it can lie, it has been proposed to fill up the cavity with threads of catgut: these threads give greater solidity to the blood-clot, and thus aid organisation.

(3) Instead of catgut it has been proposed to fill up the cavity with pieces of sponge, kept in a disinfectant solution before being introduced.

(4) A more useful material than either of these for the same purpose is decalcified bone. The bone is cut up into small pieces, decalcified in a

weak solution of hydrochloric acid, and placed in 1-20 carbolic acid till it is required for use. When it can be got, decalcified cancellous bone is better than the compact tissue; it is lighter and more porous, and thus forms a better supporting medium.

(5) Some surgeons have filled up the cavity with plaster of Paris, and report successful results from its use. The cavity must, of course, first be rendered aseptic, and the plaster of Paris should be baked at a high temperature, so as to destroy any organisms in it, and should be mixed with 1-20 or 1-40 carbolic acid solution instead of with water. The cavity is then filled up with the liquid plaster. We have only tried this plan in one case, but unfortunately we did not there succeed in getting rid of the sepsis, so that the plaster of Paris had to be removed. Although successful cases are reported, it must be remembered that new tissue cannot spread into the plaster, which must therefore remain as a hard foreign body for the rest of the patient's life. With the other methods of treatment already mentioned, organisation occurs in the material filling up the cavity and new tissue is formed in place of it. We cannot therefore recommend this plan in preference to the others.

*The decalcified bone method.*—Of the methods mentioned above probably the best is to fill up the cavity with decalcified bone; we shall therefore describe this method in detail, the description being of course applicable to the other methods, such as the use of catgut, sponge or blood-clot alone.

The first essential is that the wound should be aseptic, and we have already described the method employed with this object; the success or failure of this will be quite evident on the fourth or fifth day after the operation. An anæsthetic is hardly necessary unless it be for the purpose of putting in the stitches, but until this point is reached it is unnecessary to administer one, and cocaine will serve for the stitches. The dressing is removed, the skin again thoroughly purified in case any organisms should have found their way under the dressing, and the stuffing is taken out. As the stuffing adheres firmly to the tissues and the bone in aseptic cases, some oozing of blood occurs; this, on the whole, is very desirable, because it is required to fill up the interstices between the bone introduced and the walls of the cavity. Indeed, if there be no bleeding, it may be necessary to promote it by scarifying the soft parts.

The decalcified bone is then taken out of the 1-40 carbolic solution and placed in the cavity in small fragments pretty close together, until the entire cavity is filled up to the level of the periosteum. After sufficient blood has been poured out, the periosteum is brought together by catgut sutures, as close as it will come over the cavity; as a rule, there is little difficulty in this, as the periosteum is easily recognisable after so short a time as four or five days. It is well also to introduce two or three catgut stitches between the muscles if the wound be deep; the skin is closed with a continuous silk suture. If there be very free oozing of blood, it is well to insert a small drainage tube at the lower end of the wound for the

first twenty-four hours ; when the oozing is slight, a drainage tube is unnecessary.

The result of this in an aseptic wound is that healing occurs by first intention, and the blood-clot between the fragments of bone becomes gradually penetrated with cells which find their way also into the decalcified bone, so that ultimately the place of the blood-clot and the bone is taken by young tissue which gradually organizes into fibrous tissue. This method of treatment is much the most rapid and satisfactory, but it is rarely effectual unless the wound be quite aseptic. In some cases organisation may occur even though a little suppuration takes place, but this is comparatively rare ; as a rule, if sepsis occurs the whole thing breaks down, the fragments of decalcified bone and blood-clot must be removed and the wound treated as if it were a septic cavity.

*After-treatment.*—The further treatment consists in placing the limb on a splint which should be kept on for two or three weeks after the operation. At the end of that time however, the question of movement has to be taken into serious consideration, for not only are the movements of the neighbouring joints apt to be impeded by the occurrence of some synovitis, but the muscles are especially likely to become adherent to the edges of the cavity in the bone and to prove a permanent obstacle to the action of the joint below. The splint should therefore be left off at the end of about three weeks, and the patient allowed to move the limb a little in bed ; too much movement must not be permitted at first, as otherwise the organisation of the grafts will be interfered with. As much movement as the patient cares to do in bed will not usually do any harm, while it will prevent the muscles becoming firmly adherent. As time goes on, more movement can be carried out ; passive motion should also be made by the surgeon daily, until, at the end of about eight weeks, the patient may be allowed to get about. Even then, the limb should not be allowed to hang down for any lengthened period. After the lapse of about three months massage may be begun if it be necessary to increase the power of the muscles ; generally, however, massage will not be necessary and, if not absolutely required, it is better to avoid it, because the new material is still very tender and might break down from very slight violence. The treatment in cases where one is content with the blood-clot alone, or where sponge-grafts or pieces of catgut are placed in the cavity, is essentially the same.

(b) **In a septic wound.**—When however the wound is septic, there is no possibility of obtaining any organisation of blood-clot or of any of the other grafts which have been referred to, and the surgeon is therefore face to face with a difficult problem. After operations in which only a small opening has been made into the bone through which the sequestrum has been broken up and removed this becomes a very serious problem indeed, because the opening soon contracts and becomes so small that the discharge cannot escape properly. When this condition is once established, the cavity

will suppurate interminably, just as if a sequestrum were present in it. This is one reason why such great stress has been laid on the free opening up of the cavity in the bone; if that be done, there is not the same tendency for the aperture in the bone to become too small before the cavity fills with granulation tissue.

The objections to stuffing the wound until healing has taken place have already been referred to, and while they do not apply to the same extent in superficial bones such as the tibia, they are so weighty in the case of deep-seated bones like the femur that this plan should not be adopted. In superficial bones such as the tibia, some surgeons adopt the plan of undermining the skin for a considerable distance, pulling it over the wound and pressing it into the cavity in the bone, so as to get it to adhere to its sides; frequently however these flaps slough and frequently also adhesion fails to take place, so that this is not a method which we should recommend.

Probably the best plan is, when on the fourth or fifth day it is found that sepsis has occurred, to withdraw the plugs, introduce a large drainage tube at the lower angle of the wound, or still better, to make a separate hole for the drainage tube in the skin at a little distance from the wound and then to stitch up the whole line of incision. Healing can thus be got over the cavity, so that there is not that drawing-in of the skin and the formation of a gutter which is so great an obstacle to proper healing when stuffing is resorted to. At the same time, the drainage tube ensures free escape for the pus, and if the opening in the bone has been made large enough, and more especially if the periosteum has been removed, there is not the same risk of the opening in the superficial structures closing before the cavity in the bone has filled up.

*After-treatment.*—The limb should be placed on a splint for a week or two, but it need not be kept so rigidly at rest as in the other cases, because the filling-up of the cavity will not be so materially interfered with by movement. Great care should be taken here, even more than in the case of bone-grafting, to keep the neighbouring joints free and to prevent adhesions of the muscles to the margin of the cavity, because here, much more than in the former case, adhesions are extremely apt to occur. The splints should therefore be left off as soon as the wound in the skin has healed, and the patient encouraged to move the limb in bed, while at the same time passive motion should be practised. It is well, however, not to allow the patient to hang the leg down or to walk until the wound has healed, especially when the tibia is affected; in the case of the upper extremity, of course, the patient need not be in bed after he has recovered from the operation.

These patients have usually been pulled down very much by the previous acute illness and by the prolonged suppuration that has followed it, and steps must therefore be taken to improve their nutrition and to keep up their strength. They should be placed on the most generous



diet and should be given iron—preferably in the form of Blaud's capsules, 10 grains three times a day—and if possible they should be sent to the country. If unable to walk they should be wheeled out in the open air as much as possible. In all cases of long continued suppuration after necrosis it is well to examine the urine frequently for albumen; when once the necrosed fragment has been removed, the albuminuria, which is usually due to a certain amount of amyloid degeneration, will commonly pass off as the wound heals.

**Amputation.**—The foregoing refers to the treatment of sequestra in young people. In old people, say over fifty or sixty, whether the sequestrum be the result of a compound fracture, of an amputation, or of some acute disease in early life, the problem is somewhat different, because the chances are that proper obliteration of the cavity will not occur after removal of the sequestrum; it is very important for the old to get well as soon as possible. Hence it seems to us that in people of the age we have mentioned it is best to amputate the limb when the necrosis is extensive or affects the lower extremity. Attempts to get the cavity to fill up after removal of the sequestrum are extremely liable to end in disappointment; and it must not be forgotten that the operation of sequestrotomy is often accompanied by considerable shock, and—when a tourniquet is not used—by considerable loss of blood. In people of an advanced age this may lead to very serious consequences. The shock and the after-effects of the operation are certainly more severe after chiselling the bone to remove a sequestrum than after amputation, so that, both from the point of view of rapid healing and of the safety of the patient, amputation is the better practice. A further point of importance is the condition of the kidneys. In prolonged suppuration from an old sequestrum which has remained *in situ* for many years, severe albuminuria is often present, and in such cases it is safer to amputate than to remove the sequestrum.

**QUIET NECROSIS.**—Sir James Paget described a condition under the name of “quiet necrosis,” in which death of portions of bone occurs without any violent inflammation and without the presence of sinuses. These cases are extremely rare and it is probable that a good many of them are really cases of tuberculous disease of the bone; nevertheless we have met with a case where on chiselling away the thickened bone, a sequestrum was found lying in the middle of it, without any suppuration around. The history given was that there had been an inflammatory attack in front of the elbow joint, over the upper end of the radius, and that after the abscess healed, the radius began to enlarge and had attained a great size when the operation was performed. The bone was opened up on the view that the case was simply chronic osteo-myelitis, but, in doing so, a sequestrum was found lying in the midst of granulation tissue.

**Treatment.**—The only interest in the condition from the point of view of treatment is to remember that when thickened bone resulting from

chronic inflammation is being opened up, the possibility of finding a sequestrum should not be lost sight of. As will be mentioned immediately, circumscribed abscess sometimes occurs under these circumstances and in the same way a piece of dead bone may, though very rarely, be found; if found it must be removed and then there is usually comparatively little trouble in obtaining ready healing. If a deep cavity be left in the bone, bone-grafts may be at once introduced; or it may be left to heal by blood-clot. In any case the wound must be stitched up closely with a continuous suture.

#### PHOSPHORUS NECROSIS.

Phosphorus as a cause of necrosis requires special mention; the particular form which produces necrosis is the yellow phosphorus, not the red, and practically the lower jaw is always the bone affected. The disease is probably purely local; the phosphorus comes into contact with the bone through the medium of carious teeth. The gums become ulcerated and the inflammatory affection spreads to the periosteum and thus leads to the formation of spongy outgrowths from the bone. The gum becomes separated from the alveoli, fœtid pus is constantly poured out, and a large area of the jaw becomes affected. Indeed, the entire bone may in this way lose its vitality. The phosphorus sequestrum, therefore, is not merely normal bone that has died, but consists of the original bone with large spongy osteophytic growths on the surface.

Recent researches<sup>1</sup> seem to show that the condition is really a tuberculous one, and that the phosphorus merely predisposes the tissues to tuberculous infection.

**Treatment.**—**Prophylaxis.**—The first essential is to see that the patient works only in red or amorphous phosphorus and not in the yellow form. Further, the most scrupulous care should be taken to wash the hands thoroughly before meals, because it is probable that much of the mischief is due to particles of phosphorus coming into contact with the food, rather than to the actual phosphorus vapour. Another point of the first importance in prophylaxis is that the gums and teeth should be carefully watched while the patient is at work, and at the first sign of ulceration the work should be given up and antiseptic washes, such as sanitas or Condy's fluid, used until the ulceration is cured; any carious teeth should receive appropriate treatment.

**When the disease is established.**—Working in phosphorus should be abandoned at once. There are two alternatives in treatment, viz., either to wait for the separation of the necrosed fragment, or to excise the affected portion of the jaw at once, leaving the osteogenic layer of the periosteum intact as far as possible. The separation of the sequestrum in these cases is extremely slow, and a very long time

<sup>1</sup> See Prof. Ralph Stockman, *Brit. Med. Jour.*, Jan. 7, 1899.

may elapse before the affected portion is loose; and, as a large portion of the jaw will almost certainly be destroyed, it seems more feasible to proceed to the removal of the affected portion of the bone directly necrosis is established. If the periosteum be carefully separated along with the superficial layer of living bone, sufficiently firm bone will usually be thrown out to make a useful mandible. The operation of excision of the mandible will be described later when we discuss the affections of that bone.

## CHAPTER XI.

### TUBERCULOUS DISEASE OF BONE.

**VARIETIES.**—Tuberculous disease of bone is of course due to the tubercle bacillus, and is most common in young people. The bone is generally affected either in the epiphyses or in the shaft just outside the epiphyseal line; in some cases the medulla may be attacked, while in others the disease may begin beneath the periosteum. The affection may assume the following forms:

(1) **Acute tuberculous of bone.**—This may occur in the course of a general acute tuberculosis, or the disease may be limited to one bone, in which case it starts in connection with a pre-existing tuberculous deposit. The form met with in acute general tuberculosis is of no importance from the point of view of treatment; when the acute affection is limited to one bone, it influences the treatment in so far that nothing short of removal of the affected bone is likely to do any good.

(2) **Limited tuberculous deposits.**—These are found most frequently in the epiphyses, and may occur as soft caseating deposits in which the bone trabeculæ have more or less completely disappeared, or as sequestra imbedded in tuberculous material.

*Limited caseating deposits.*—When there is a limited caseating deposit in the end of the bone, the tendency is for the disease gradually to spread, and for the softening of the bone to continue until the deposit reaches the surface. Its further progress depends upon whether the spot at which it reaches the surface of the bone is within or without the joint. In the former case the articular cartilage over the deposit is destroyed, a communication is formed with the joint, and the result is rapid infection of the synovial membrane. These cases will be best considered when the subject of tuberculous disease of joints is discussed (see Part IV.).

When the tuberculous deposit reaches the surface outside the capsule of the joint, the periosteum becomes infected, and the tendency is for the soft tissues outside the latter to become attacked, and for a chronic abscess to form. At the same time that the tuberculous deposit is making

its way to the surface, the periosteum in the vicinity is becoming thickened, and new bone is being deposited, so that the bone usually becomes very considerably enlarged.

*Tuberculous sequestra.*—In the case of tuberculous sequestra the further progress is the same; the disease either makes its way gradually to the joint, or to the free surface of the bone. An abscess may then form outside and burst. When the abscess is opened or bursts spontaneously, a probe passes down into the interior of the bone and comes in contact with a dense tuberculous sequestrum.

(3) **Tuberculous osteo-myelitis.**—Here the medullary tissue is infiltrated with tuberculous material. This especially affects the shorter of the long bones such as the phalanges and metacarpal bones; it may end in the formation either of a soft caseating mass, or of sequestra as well. In the fingers it is known as “strumous dactylitis.” At first the disease is confined to the interior of the bone; during this time the periosteum around becomes thickened, and when the bone is a short one, like a phalanx, it assumes a fusiform shape. As the disease progresses, however, the hard shell of the bone is broken through at some point, and then infection of the periosteum occurs; subsequently a chronic abscess forms which, when opened, is found to lead into the interior through a hole in the bone.

(4) **Tuberculous periostitis.**—In this form the tuberculous material is deposited beneath the periosteum; it occurs especially frequently in the ribs and the vertebræ. The disease spreads partly into the bone and partly into the soft tissues around, and the result is that an abscess very frequently forms; at the same time the surface of the bone becomes eroded and carious, and small sequestra may also be formed. In the ribs actual fracture may occur.

**CLINICAL STAGES.**—Hence, tuberculous deposits in bone may be met with in various clinical stages. In the first place, the tuberculous deposit may be still confined to the interior of the bone, and no external disease may have as yet occurred. Secondly, the deposit may have reached the surface of the bone and have caused a chronic abscess over it; and thirdly, this chronic abscess may have burst, and septic sinuses leading down to a tuberculous deposit in the bone may be present.

In tuberculous osteo-myelitis the condition may also be similar; in some cases the bone is enlarged but still intact; in others there may be abscesses in connection with the enlarged bone, and in a third class there may be sinuses leading down to an aperture of communication with the medulla.

In tuberculous periostitis there will be some thickening about the periosteum in the early stages, but in exposed bones, such as the ribs, there may be a chronic abscess in connection with disease of the surface of the bone quite early in the case. In other cases again the abscess may have burst before it comes under notice, and there are then sinuses leading down to carious bone. The results in the cases where the

deposits open into joints will be best considered under Diseases of the Joints (Part IV.).

**TREATMENT.**—Of course in any given case the actual details of the treatment depend to a considerable extent on the bones or parts of the bones involved; here we can only deal generally with the subject, taking one or two of the cases as examples.

It will be unnecessary to treat of tuberculous deposits, tuberculous osteo-myelitis, and tuberculous periostitis separately; it will be sufficient if we take the three clinical divisions: (1) tuberculous disease of bone without abscess; (2) tuberculous disease of bone with abscess; and (3) tuberculous disease of bone with septic sinuses.

(1) **Of cases unaccompanied by chronic abscess.**—Here the great difficulty is to diagnose the existence of tuberculous disease at all. The surgeon must be guided to a great extent by the history of the case, by a previous or hereditary history of tuberculosis, by enlargement of the bone without any marked symptoms, by the general character of the enlargement and by the fact that the part affected is a common seat of tuberculosis. In certain cases, such as strumous dactylitis, there need be very little hesitation, the only other possibility being syphilitic disease. Skiagraphy will probably be of considerable value in these cases, as by its means alterations in the structure of the bone can be identified and sequestra demonstrated.

**Palliative measures.**—When the diagnosis of tuberculous disease of the bone has been made, the question lies between palliative and radical measures. By palliative measures we mean rest to the part, counter-irritation, pressure and good hygienic conditions, such as country air, cod-liver oil, syrup of iodide of iron, etc. These have already been referred to in speaking of tuberculous disease in general (see Part I., p. 254), and will be again referred to under Diseases of Joints; we need not therefore go further into the matter here. Sometimes these measures suffice to arrest the disease, and, in strumous dactylitis particularly, little else may be necessary. In the latter affection some salicylic wool should be applied firmly round the affected part by means of a bandage, and the whole finger and hand put up in plaster of Paris. This should be renewed every two or three weeks. When the hand is very small, a moulded poroplastic splint may be easier to apply. A good many cases recover if this treatment be steadily pursued for a long time—several months—and it is seldom that an operation is necessary or advisable, unless an abscess forms. In the case of other bones, counter-irritation, especially by means of the actual cautery (see Part I., p. 19), is often very useful.

**Radical measures.**—When, however, the deposit is in the articular end of a bone it is very liable to open into the joint and produce disease there, and therefore it is advisable to get rid of it as soon as possible. The best treatment is to cut down without delay and remove the deposit. The incision should be so planned that it does not

open the joint, because it is important to avoid infecting it with the tuberculous material. The incision should expose the bone where the thickening is most marked; if a tender spot can be detected it should always be cut down upon, because that will probably be the spot at which the deposit is nearest to the surface of the bone. A flap, consisting of skin and subcutaneous tissues, is turned aside and the bone exposed; if the periosteum be still intact and unaffected that may also be peeled off, and then the surface of the bone is removed with a gouge and hammer. If a caseous deposit be present, unduly soft bone is soon encountered; if, on the other hand, there be a sequestrum, it will be extremely dense.

**For a caseating deposit.**—In the case of a soft deposit, all the tuberculous material should be scooped out with a sharp spoon until a cavity with fairly firm walls is left, and then a thin layer of the denser bone which forms the wall of the cavity should be taken away by a stronger spoon or a gouge. For this purpose Barker's flushing gouges are very useful. Microscopical examination shows that the disease seldom extends any distance into the bone—not more than about an eighth of an inch beyond the actual soft deposit—so that only a thin layer need be removed. It is however very important to remove this as otherwise tuberculous disease may be left behind.

**For a sequestrum.**—If a tuberculous sequestrum be met with, it must be taken away. The characteristics of a tuberculous sequestrum are that it consists of thickened bone and is thus heavier and harder than the normal bone, but at the same time it is not generally very firm, and usually crumbles under the fingers. A second point with regard to tuberculous sequestra is that they are very slow in separating, and months or years may elapse before a small sequestrum is completely loose. The sequestrum, therefore, cannot be lifted out as can those that follow acute osteo-mylitis, but must be torn out of its bed with forceps. The wall of the cavity from which the sequestrum has been removed is also tuberculous, and must be scooped and gouged away in the manner just described for the soft deposits. We need hardly remark that in these cases strict asepsis is essential, as otherwise very serious suppuration may occur, and further, if any tuberculous tissue be left behind, it is likely to grow more rapidly afterwards.

If the whole of the tuberculous tissue has been got rid of, it will suffice to stitch up the wound, leaving the cavity to fill with blood-clot which subsequently becomes organised, but if there be any doubt about the complete removal of the tuberculous deposit, it is better to apply undiluted carbolic acid to the part, sprinkle the wound with iodoform, and stuff it with cyanide gauze impregnated with iodoform. On the following day the external dressing is removed, but unless the stuffing be loose it need not be disturbed for three or four days. Subsequently the wound is stuffed with iodoform gauze until it has completely filled with granulations, and then the stuffing may be given up and gauze and salicylic wool applied until healing is complete.

In tuberculous disease of the small cancellous bones such as those of the tarsus, it is often best, even in the early stage, to excise the bone without making any attempt to merely remove the deposit. The removal of such a bone as one of the cuneiforms, for example, does not seriously affect the after condition of the patient, and if done in the early stage it gives a most satisfactory result both in the way of cutting short the disease—which otherwise would be apt to spread to and infect the tarsal joints—and in its functional result. This subject will, however, be considered in connection with diseases of joints, especially those of the tarsus.

**(2) Of cases in which there is an unopened abscess.**—The abscess may originate either in connection with tuberculous periostitis or with deposits in the interior of a bone which have made their way to the surface. Wherever possible, the best treatment is to excise the abscess as if it were a cyst, and at the same time to remove the diseased periosteum along with the superficial layer of the bone, and clear out any deposit that may be present in it.

**Excision of a bone abscess.**—Let us take, for example, tuberculous disease of a rib with abscess; in the ribs the great majority of cases commence in the periosteum, and are examples of tuberculous periostitis. When the abscess is large it is not always possible to be sure at first which rib is affected. A free incision is made over the abscess, the direction of the incision being planned according to the part affected; as a rule it should be in the course of the muscular fibres. The skin and subcutaneous tissues are then turned aside, and the muscular fibres are separated from the abscess wall. This, however, is not always possible, for in many cases the muscle is involved in, or at any rate adherent to, the abscess wall. In the latter case the muscular fibres are divided, and the abscess is carefully defined until it is ascertained which rib it is attached to, care being taken to avoid accidental puncture of its wall; then the rib beyond the point of attachment of the abscess is exposed, the periosteum divided, and the rib cut across by cutting pliers on each side of the abscess. The intervening diseased portion of the rib can then be removed along with the abscess over it. As a rule, when the rib is lifted out, a cavity is found beneath it containing tuberculous material, for the pus usually surrounds the rib. This part of the wall cannot be dissected away, but should be very thoroughly scraped, care being taken not to puncture the pleura. The whole wound is then washed out, so as to get rid of any tuberculous material that may have lodged in it, and is stitched up and the usual antiseptic dressings applied. If the whole of the tuberculous material has been removed, healing by first intention occurs, and the patient is well in ten days; whereas if the abscess were merely opened, scraped out and glycerine and iodoform injected, the disease might go on for many months, and spread into inaccessible portions of the rib, or from one rib to another.

When similar treatment can be adopted in other bones this should



be done. For example, when there is an abscess in connection with a tuberculous deposit in one condyle of the femur, a curved incision should be made over it, the flap thrown back, and the abscess wall dissected out as far as possible. After removing this, the hole in the condyle is searched for, the bone chipped away all round it, and the deposit removed in the manner already described (see p. 199).

When the abscess is very large, or when from its connections it cannot be dissected out, it should be laid very freely open, as much of the abscess wall as possible removed with scissors and forceps, and any portions left behind thoroughly scraped. The diseased bone is then exposed and removed. In the case of the rib it is of course clipped off very readily by forceps beyond the carious part; in the case of bones like the end of the femur, it is chiselled away. After this, if good access has been obtained to the abscess wall, and the diseased bone removed, the wound can generally be stitched up, and healing by first intention secured without any further trouble. When the complete removal of the tuberculous tissue is doubtful, it is well to leave the wound open, sponge it out with undiluted carbolic acid, and stuff it with cyanide gauze sprinkled with iodoform.

In strumous dactylitis, which may be taken as representing tuberculous osteo-myelitis in the shafts of bones, similar treatment should be employed. It is often tempting to amputate the finger or the toe, but this is not usually necessary. If the abscess wall be thoroughly removed, and the medulla well scraped out, the wound will usually heal without trouble.

In abscesses connected with deep-seated bones, such as the spine or pelvis, the operation must be conducted on the lines already laid down for chronic abscess (see Part I., p. 249). The abscess is opened, the wall thoroughly scraped out, the cavity washed out so as to get rid of all the flakes and cheesy material, and then the 10 per cent. emulsion of iodoform and glycerine is injected and the wound closed. In some cases the whole deposit may be scraped out and a satisfactory result obtained, but as a rule this is only likely in cases of tuberculous periostitis; when there is a tuberculous sequestrum or a soft deposit in the bone, the abscess is very apt to re-form and the final result is doubtful.

**(3) Of cases in which there are septic sinuses.**—Here the treatment should be operative, because there is but little tendency to healing, and suppuration may go on for a very long time.

**Excision of sinuses.**—The sinuses should be excised, the area of bone from which they originated should be freely exposed and the focus of disease in it removed, if possible. Every attempt should be made to render the wound aseptic. The skin should be thoroughly disinfected, and the granulations at the orifice of the sinuses should be scraped away. A small piece of sponge saturated with undiluted carbolic acid should then be introduced into the sinus, care being taken, by placing sponges around the orifice, that the acid does not run over the skin, as

it would cause a sore. It is well to leave the piece of sponge in the orifice of the sinus, and to insinuate past it a probe which is held in position against the bone.

A large incision is then made, diverging on each side of the orifice of the sinus so as to enclose it, and the parts are carefully divided in the direction indicated by the probe, the sinus being included in the dissection, and its whole length removed. When the bone is reached, the sinus should not be cut away, but the healthy bone on each side of it is exposed and chiselled through, so that the diseased portion can be removed entire; then, in the case of the rib, any tuberculous material between it and the pleura should be thoroughly scraped, and undiluted carbolic acid applied to it. In the case of sinuses leading down to bones such as a condyle of the femur, the diseased area should be gouged and chiselled away in the manner already described (see p. 199).

It is best to stuff the wound with cyanide gauze impregnated with iodoform and allow it to heal from the bottom, or at any rate to wait until the whole surface is covered with healthy granulations and then to bring the edges of the skin together, leaving in a drainage tube for a few days. The part should be kept at rest, and when the disease affects the lower extremity, the pelvis, or the spine, the patient should remain in bed or on a couch which can be wheeled out into the open air.

While healing is taking place, the greatest attention should be paid to good hygiene; plenty of fresh air, nourishing food, and the use of cod-liver oil, are the principal points.

**Amputation.**—We have already referred to the fact that in strumous dactylitis, at any rate without sinuses, amputation can very often be avoided; and as a matter of fact it seldom comes into consideration except in cases where there is joint disease complicating the bone trouble. But it may have to be considered in extensive bone disease with numerous sinuses, where it is impossible to get proper access to the part, and where at the same time the patient is suffering from phthisis or albuminuria, or where the general health is bad. The indications for amputation however will be considered more appropriately in connection with joint disease (see Part IV.).

## CHAPTER XII.

### SYPHILITIC AND RHEUMATIC AFFECTIONS OF BONE.

#### SYPHILIS OF BONE.

SYPHILITIC affections of bone may occur in the secondary and tertiary periods of acquired syphilis, and also in the inherited form. The treatment is essentially that of syphilis itself, and we need only refer very shortly to the subject.

**IN SECONDARY SYPHILIS.**—Accompanying the congestive conditions of the skin at quite an early period of the secondary stage of syphilis there may be pains in the bones of a rheumatic character, which are probably due to congestion, and do not leave behind any permanent lesion. But at a later period of syphilis, from the sixth month onwards, there is a definite form of bone lesion—syphilitic periostitis—which may ultimately lead to the formation of bony nodes. The bones most often affected in this way are the more superficial ones, such as the skull (especially the frontal bone), the ribs, the sternum, the tibia, and the clavicle. The patient has nocturnal pains in the part, especially when warm in bed, there is some swelling and tenderness, and the swelling, though limited to one part of the bone, may occasionally be of considerable size. If the part be examined in the early stages, the periosteum will be found thickened, and beneath its deeper layer there is an effusion of gelatinous material. If the condition be left untreated, ossification may take place and a permanent mass of bone be formed, which is termed a syphilitic node. If, however, the ordinary treatment of secondary syphilitis be employed at once, the thickening may disappear entirely.

**Treatment.**—The patient should be put on mercury (see Part I., p. 232) and it is well to keep the part at rest and strapped with mercurial ointment. If there be much pain, evaporating lotions (see Part I., p. 8) may be used, or hot fomentations if the pain be very great: beyond this no local treatment is necessary.

**IN TERTIARY SYPHILIS.**—In the tertiary stage are found gummata of bone and syphilitic osteitis with great thickening. The gummata of bone may occur sub-periosteally or in the medulla, and there may be either a circumscribed gummatous mass or a diffuse infiltration of the whole bone with gummatous material. The circumscribed gummata are most frequent on the skull, where they may begin either under the periosteum or in the diploë. They also occur frequently in the vomer, the nasal bones, the palate, the clavicle, the tibia, and the epiphyseal ends of other bones. The gummatous material spreads from the deeper layer of the periosteum into and along the Haversian canals, and leads to rarefying osteitis in its vicinity, while condensation of the bone beyond takes place, so that a bone which has been the seat of syphilitic gummatous disease presents an eroded and worm-eaten surface, due to the great size of the Haversian canals, with very dense bone around. This condition is sometimes spoken of as syphilitic caries, and considerable destruction of bone may result from it. In other cases, portions of the condensed bone may die, and thus a syphilitic sequestrum is formed, the characteristic of which is that it is much denser and heavier than normal bone, because before dying it has been the seat of condensing osteitis; its surface is worm-eaten from the spread of the gummatous material along the Haversian canals. These sequestra, like those of tuberculous origin, often take a long time to separate. There is not the same stalactitic new formation of bone from the periosteum in connection with these sequestra as there is in ordinary necrosis, although sometimes, when the sequestrum is central, it may be more or less surrounded by bone.

In gummatous disease of bone there is often a good deal of pain, which is generally more intense than in the syphilitic node, of a boring character and worse at night; when gummata occur in superficial bones, they spread in the soft tissues and involve the skin, and a syphilitic ulcer forms, at the bottom of which there is bare bone, soft on the surface but very dense underneath, so that a probe cannot be pushed for any distance into it.

**Treatment.**—The treatment of gummatous disease of bone is that of tertiary syphilis and consists essentially in the administration of large doses of iodide of potassium together with mercury. The patient should begin with fifteen grain doses of the iodide three times a day, and very quickly increase them to thirty or forty grains; it is well to combine this with mercury (see Part I., p. 235).

*Operative.*—Gummatous bone disease is one of the forms of tertiary syphilis in which surgical intervention materially shortens the course of the case, and may lead to permanent cure. The operation consists in opening up the affected area, scraping away the diseased tissue, and chiselling away some of the dense bone. If a sequestrum be present, it should of course be removed. After removing the diseased and thickened bone, the whole surface should be thoroughly sponged with undiluted

carbolic acid, stuffed with iodoform gauze and made to heal from the bottom. At the same time the constitutional treatment should be vigorously pursued. As a rule very satisfactory results will be obtained in this way, whereas tertiary syphilis of bone is very often very rebellious to internal antisyphilitic remedies alone, more especially when there is an external ulcer.

**IN HEREDITARY SYPHILIS.**—The changes in the bones in hereditary syphilis are of great interest; one of the earliest is inflammation of the ends of the long bones, particularly those of the tibia, the humerus, the femur and the ulna. This affection is often symmetrical, and usually affects the diaphysis in the immediate neighbourhood of the epiphyseal line, the condition often going by the name of "osteochondritis." It generally occurs at a very early period of life; the bone becomes very much thickened in the neighbourhood of the epiphyseal line, and a tender swelling occurs which forms a collar around the end of the bone, and is due to very marked enlargement and periosteal deposit. In some cases the condition may go on to separation of the epiphysis and destruction of the epiphyseal line. The changes which are produced in this situation very much resemble those of rickets.

During the first year of life also there is a tendency to the production of bosses of spongy bone on the skull, especially near the sutures; four bosses are often found around the anterior fontanelle, giving rise to the natiform skull.

At a later period there may be gummatous changes in the bone similar to those which occur in adults, and there may be destruction of the nasal bones, of the palate, and of other bones in an exactly similar manner.

**Treatment.**—In the earlier stage of hereditary syphilis of bone, mercurial treatment (see Part I., p. 236) is the best. No special local application beyond the use of mercurial ointment is necessary except when there is much tenderness about the epiphysis, in which case it is well to fix the part. In the later stages iodide of potassium, combined with mercury, is the proper treatment (see Part I., p. 237).

#### RHEUMATIC PERIOSTITIS AND OSTEITIS.

Osteitis may also occur as the result of rheumatism, which affects bones as well as joints. Rheumatism chiefly gives rise to periostitis, with condensing osteitis beneath; in some cases the whole thickness of the bone may be involved.

**Treatment—Medicinal.**—In the early stages the treatment of rheumatic osteitis consists in the use of salicylates, iodide of potassium, rest and counter-irritation. The affected limb should be put on a splint, blisters applied over the inflamed bone, or Corrigan's cautery used (see Part I., p. 20); internally 10 to 30-grain doses of iodide of potassium, or 10-grain doses of salicylate of soda should be given three times a day.

**Operative.**—Should the disease not yield readily to this treatment, the best plan is to cut down and remove as much of the thickened periosteum as possible, and at the same time to gouge away a portion of the thickened bone ; in these cases it is not necessary to open up the medullary cavity.

In cases of so-called “neuralgic osteitis,” where the pain is intense and probably due to pressure on the nerves in the condensed bone and consequent neuritis, very free gouging of the affected portion is the only treatment that offers a satisfactory result. There is apparently very little thickening of the bone in these cases, but after the operation very marked improvement often follows. These operations are only permissible with strict asepsis.

## CHAPTER XIII.

### RICKETS: SCURVY-RICKETS.

#### RICKETS.

RICKETS may be defined as a disease of the period of growth associated with general disturbance of nutrition and characterised by alterations in the bony tissues and by deformities of the skeleton, as well as by various internal disorders. Cases occur where children are born with rickets (the so-called "foetal rickets"), but the disease generally commences during infancy, and begins to show its effects on the skeleton during and after the second year. In some cases, however, rickets first appears towards the age of puberty ("rachitis adolescentium").

**ETIOLOGY.**—The etiology of the disease is by no means clear, but, from the point of view of treatment, two theories only need be mentioned. The first is that the affection is due to injudicious feeding, particularly to too early weaning, accompanied by the administration of too much farinaceous, and too little albuminous food. It is supposed that the excess of farinaceous food leads to decomposition in the stomach, and consequent overloading of the blood with lactic or other acids; this is supposed to cause irritation of the nervous system, the lungs, the intestines, and the growing parts of the bones.

The other view is that the disease is due essentially to imperfect oxygenation of the blood, and that excess of carbonic acid in the blood is the irritating agent. In support of this theory it is pointed out that patients with rickets are most numerous during the early summer, the disease having been set up as the result of confinement to the house during the winter, the effects of the confinement becoming manifest towards the end of the spring or the early part of the summer. Similarly the season of the year when rickets is least prevalent is towards the end of the year, the children having had plenty of fresh air and sunshine during the summer. Rickets mainly occurs in the children of the poor, who are not only imperfectly fed but are also closely confined

to houses in which the hygienic conditions are bad. Probably both causes come into play.

**PATHOLOGICAL CHANGES.**—From the surgical point of view the main factor with which we have to deal in rickets is the osseous deformity; this manifests itself either in enlargements about the epiphyseal lines, or in curvature of the bones. We shall not refer to the other symptoms.

Enlargement at the epiphyseal lines always occurs; the curvature of the bones depends on mechanical factors and may not be present. In the thorax, enlargements are found along the line of junction of the costal cartilages and the ribs, forming the so-called "rickety rosary." When there has been obstruction to respiration, as in children who have suffered from bronchitis or broncho-pneumonia, there is generally the deformity known as "pigeon-breast," in which, as the result of atmospheric pressure, there is a depression at the point of junction of the ribs with the cartilages, so that the sternum projects, and the cartilages run forward towards it. The chest may also be constricted transversely, the lower ribs being everted. The spine is not uncommonly affected; usually there is a general antero-posterior curvature affecting its whole length, but sometimes the curvature may be lateral. The pelvis may be flattened antero-posteriorly or the acetabula may be approximated, and the pelvis may be heart-shaped; very often it does not develop properly and remains small throughout life.

The ribs and the bones of the extremities, especially the femur, the tibia and the radius become enlarged at the epiphyseal lines. This enlargement is constantly present, and in many cases, if the patient bears weight on the weak bones, there is also a certain amount of bending. The femur becomes curved antero-posteriorly, the tibia becomes flattened laterally and bends outwards, the common rickety deformity being bow-legs; genu valgum is also common. In other cases there is an antero-posterior curvature in the tibia just above the ankle joint.

The changes in the bones during rickets consist essentially in excessive preparation for the formation of new bone and imperfect deposit of the hard bony structure; the epiphyseal line is thus very much thickened and increased in breadth. The periosteum is also thickened, and the soft tissue in the Haversian canals and lining the medullary spaces is much increased in amount, while the dense bone is less than normal. Hence the bones are soft and bend easily when subjected to pressure. When the rickets passes off, fresh bone is formed in this soft material, and in consequence the bone becomes much denser and harder than normal, so that it is sometimes very difficult to cut through it.

**TREATMENT.**—In the treatment of rickets, attention should be paid to the *feeding* of the child, and to the general hygienic conditions. Farinaceous food should be avoided during the first year of life, and during the first nine months at any rate, the diet should consist entirely



of milk. If the mother be unable to suckle her child, a wet nurse is the best substitute, and failing this the child should be fed on cow's milk which is at first diluted with double the amount of water or barley water, and to which a little sugar of milk is added; later on, cow's milk may be given pure.

When the child is about nine months old, some farinaceous food, such as oatmeal, may be mixed with the milk, but it should be given in small quantity; the bulk of the diet should consist of milk. The patent foods and biscuits that are so commonly used should not be administered at all until the child is nearly a year old, and then only sparingly. When the child is about a year old, the addition of meat to the diet should be made. At first an egg once or twice a week, and on other days a little gravy and potato, or gravy and bread is sufficient; the child should not take solid animal food until towards the end of the second year.

The child should be placed under *good hygienic conditions*, should be out in the open air as much as possible, should take advantage of the sunshine to the utmost, and if possible should be sent to the sea-side or to the country; the clothing should be of flannel. The following regulations are in use at the Children's Hospital, Paddington Green, and may be taken as a type of regulations suitable for outpatient cases; they may easily be adapted for use in private practice.

#### FEEDING.

**1. Between 9 and 12 months.** Give cow's milk warmed and slightly sweetened. Not *Swiss* or any form of condensed milk. If diarrhoea or sickness comes on, or curds appear in the motions, boil the milk and add one part of lime, barley, or rice-water to two parts of milk.

Give twice a day a meal of milk, thickened with Robb's biscuit or wheat flour, or Mellin's, Ridge's or Savory and Moore's Food. Nestle's Food, which does not require milk, may also be given. All infants' foods should be given in small quantities at first.

**2. At 12 months.** Besides milk, thickened as above, eggs with milk, gravy with bread-crumbs, or well-mashed potato may be given; also rice, sago, arrowroot, semolina with milk; gruel and oatmeal porridge.

**3. At 18 months.** Give once a day a little fresh fish, such as plaice, or in addition, finely minced mutton.

Food should still be almost entirely milk and all things made with milk.

*Do not give* cheese, pastry, shellfish, salt fish, unripe fruit, nuts, sweets, tea, wine, beer or spirits.

*Feed at regular times*—not every time the child cries.

**4. Between 9 and 15 months.** Feed, by day, every three hours, and once during the night. Give one and a half to two pints of milk daily—plain, thickened and in puddings.

**5. After that age** feed every four hours by day, and give one pint of milk to drink during the day. Do not feed at night. *On no account* keep the child at the breast after it is nine months old. *Mother's milk* is useless to the child after that age: *and suckling is most injurious to the mother.* It is a mistake to suppose that suckling after this time prevents pregnancy.

## CLOTHING.

They should always wear flannel next the skin.

**By Night:** A long flannel night-gown, fastened below the feet and at the wrists and throat.

Let them sleep in cots by themselves—never in a draught, or between the window or fireplace and the door.

Bed-clothes should be warm and light.

Keep the window open all night in warm weather.

Keep a small fire burning all night in cold weather.

**By Day** (*a*) a flannel vest fitting closely round the neck—loosely elsewhere. All other clothing about the chest should be loose and warm.

(*b*) A well-fitting flannel binder round the belly reaching from just below the hips to the lowest part of the breast bone.

(*c*) *Flannel Drawers* should always be worn. They may be buttoned on to the binder, to which shoulder-straps should be added. The binder will then not slip up or down.

(*d*) In cold weather warm *stockings* or woollen gaiters *reaching to the top of the legs* should be worn.

All under-clothing as well as bed-clothes should be well aired before use.

## GENERAL DIRECTIONS.

1. Keep them out of doors most of the day in fine weather.

Do not let them be carried by other children not much bigger than themselves.

Get a perambulator in which they can lie down.

Wrap them up well, and use as a foot-warmer in cold weather a strong wine-bottle filled with hot water and placed in a thick stocking.

2. Keep them clean. Wash them all over night and morning with soap and warm water. Dry carefully with a soft warm towel. Then with the open hand chafe and rub the limbs from below upwards until the skin is rosy. The limbs should be rubbed one by one, the rest kept covered meanwhile. The back, if weak, should also be rubbed.

Children will not take cold if they are carefully dried, especially the head and ears, and are well warmed after the bath.

3. Children with bow legs or knock knees should not be allowed to stand, walk, or crawl.

If their backs are growing out, they should be kept lying on their backs.

The only *drugs* which seem to be of any special service are cod-liver oil and phosphorus. Cod-liver oil should always be given in rickets, even when the children seem to be well nourished. The best way to administer it is in one of the practically tasteless emulsions; the dose is a teaspoonful three or four times a day after food, and fortunately children rather like it than otherwise, so that there is usually no difficulty in getting them to take it. Phosphorus is also a very useful drug in doses of a hundredth of a grain, which is best given mixed with the cod-liver oil. The compound syrup of phosphates (Parrish's food), and syrupus ferri phosphatis are also good, but pure phosphorus is better. Iron may be of use in pale anæmic children, and the best form is probably the tinct. ferri perchlor., given

in four or five-minim doses twice or three times a day; the syrup of the iodide of iron in half-drachm doses is also useful.

The child should be sent to the *country*, and if possible to the seaside, and, while there, *sea-water baths* or, if they cannot be obtained, baths containing sea-salt are very valuable. The baths should be tepid, and after them friction to the limbs and abdomen should be employed for fifteen or twenty minutes until the skin is in a good glow.

The main surgical point to consider in rickets is the treatment of the deformities of the limbs which are so apt to occur. When the disease is progressing, the child should not be allowed to stand or run about, as otherwise deformity of the lower limbs and the pelvis will almost certainly result. The child should be kept in bed or lying on a mattress, and should be taken out whenever there is sunshine; in some places the treatment of rickets consists essentially in allowing the child to lie or play on a heap of sand exposed to the full glare of the sun with only a night-dress on.

When the deformity of the limbs is only slight, the probability is that, if prevented from standing and walking, the child will outgrow it; friction of the affected limbs and *manipulation* of the deformity in such a way as to gradually unbend the curve are powerful adjuncts to success and must not be neglected. It is remarkable how quickly a curve will disappear in a young child when carefully treated in this way.

When however the curve is marked before the patient comes under notice, the question of *splints* or of osteotomy has to be considered. These two methods each have their place. While the rickets is progressing and the bones are still soft, the application of apparatus is the proper treatment. Operation in progressive cases only leads to disappointment, as the deformity almost certainly recurs when the child begins to walk about; in some cases operation may result in non-union. When, on the other hand, the rickets has passed off, and the dense deformed bone is left, apparatus cannot be expected to exercise any effect, and operation must be considered.

The employment of apparatus for the different deformities of rickets has already been discussed in full (see Part II.). The method consists essentially in the application of splints along the concavity of the curve, pressure being brought to bear on the point of greatest curvature by means of an elastic bandage. Care must of course be taken not to use too great pressure upon the tender skin of a child, as otherwise sloughing may occur opposite either end of the splint, or at the point where the elastic band is applied. As a matter of fact no great pressure is required in these cases.

Before operating for rickets, the surgeon should wait until the acute stage has passed off, and the deformity has ceased to be progressive: usually *operation* is not advisable until the child is five or six years of age. The whole question of operative treatment for the various deformities resulting from rickets has already been fully discussed (see Part II.).

## SCURVY-RICKETS.

**DEFINITION.**—By the term “scurvy-rickets” is understood a condition that is really a true scurvy occurring in infantile life. The name is somewhat misleading as it seems to infer that a ricketty condition is an integral part of the affection, whereas, although both scurvy and rickets are not at all infrequently found associated together, the latter disease has no causal relation to the scurvy, which is of the same type as that found in adult life, and which, moreover, may occur in infants without any ricketty change whatever.

**ETIOLOGY.**—As is the case in adults, scurvy in infants is due to defective feeding, and is primarily caused by a lack of fresh animal and vegetable food. That this should occur among the children in large cities is at first sight somewhat difficult to explain, but an explanation has been suggested by Dr. Sutherland<sup>1</sup> and others who draw attention also to the fact that the disease has become decidedly more prevalent during the last fifteen or twenty years.

According to these authors it has been found that, while healthy breast milk and fresh cow's milk—even when the latter has been just raised to the boiling-point and allowed to cool—are perfect foods for infants from an anti-scorbutic point of view, the same cannot be said of either the “sterilised” milks or many of the artificial infants' foods upon the market.

With regard to the “sterilised” milks, it may be remarked that while “Pasteurisation”—*i.e.* subjecting the milk for 20-30 minutes to a temperature of 160° F.—does not affect its anti-scorbutic properties, true “sterilisation,” by keeping it at or above the boiling-point for 20 minutes or more, does so in a very marked degree.

The same is true of the various infants' foods prepared artificially, whether they take the form of preserved milks or starchy foods, or a mixture of the two; the treatment they have to undergo destroys their anti-scorbutic powers, and therefore they cannot be relied upon as the sole article of diet.

Even meat or meat-juice cannot be depended upon entirely to prevent scurvy; possibly it might do so were meat eaten quite freshly killed, but this is rarely the case, and scurvy has been known to occur where meat has formed part of the diet. Fruit and vegetables, of course, possess high anti-scorbutic properties.

It does not absolutely follow, however, that a child brought up for a long time on a diet of preserved milk or patent foods will develop scurvy; it is only safe to say that a child so brought up is not proof against the affection. There is often a history of some preceding trouble in the ali-

<sup>1</sup>Dr. G. A. Sutherland, *Clinical Journal*, 1897. The reader desirous of further information on this subject may with advantage consult this paper, from which many of the above points are taken.

mentary canal, and the disease not infrequently comes on after a specific fever. It is far more common in the first two years of life than at any other period.

**PATHOLOGICAL CHANGES.**—The only morbid changes that concern us from the point of view of treatment are those occurring in the bones.

Whereas in adults spongy, bleeding gums are the most frequent signs of scurvy, in infants the disease mainly manifests its presence by subperiosteal hæmorrhages in the long bones. At some point along the course of the bone a firm swelling develops, which gradually increases in extent, and may spread along the entire length of the shaft. This swelling consists of more or less fluid blood extravasated beneath the periosteum, and also, to a lesser extent, among the deeper muscles. As a rule, fluctuation is difficult to make out. The femur is the bone most frequently affected, and the bones of the lower extremities are usually attacked before those of the upper.

Fractures, either spontaneous or following very slight manipulation, are very apt to occur in bones thus affected, and union does not take place until the disease is arrested. In cases of scurvy pure and simple, these fractures are commonest in the shafts of the long bones, while in the cases of scurvy associated with rickets, separation of one or both epiphyses of the bone affected is more likely to be met with.

Spongy and bleeding gums are not very noticeable in these cases. If the child has no teeth, there is but little alteration in the gum. The older the child is, however, the more prominent this symptom becomes, while the lesions in the long bones are proportionately less severe.

**SYMPTOMS.**—A child affected with scurvy becomes listless and anæmic, sallow in colour, and irritable if disturbed. There may be the characteristic bleeding and spongy gums or hæmorrhages from the bowel or into the subcutaneous tissues. Later on there are extravasations of blood beneath the periosteum of various bones, chiefly those of the extremities, and with these there is inability to use the affected limbs and intense pain when they are handled. If the case be left untreated, the hæmorrhages increase, and the child dies from exhaustion or some intercurrent affection.

**TREATMENT.**—**Prophylaxis.**—No child who is brought up upon a suitable diet can develop this condition. There is no known case of the disease among infants brought up on breast-milk during the ordinary lactation period; after that time it is said that the milk undergoes changes which rob it to a certain extent of its anti-scorbutic powers.

Should the breast milk fail, its place must be taken by pure fresh cow's milk, and it is most important to remember that no artificial food or prepared milk—otherwise than by scalding, boiling, or Pasteurising—should be given during this period unless as a temporary measure because the child is unable to digest fresh milk. Even then it will be well to administer orange-, grape- or lemon-juice in teaspoonful doses twice a day.

After the age of nine months, vegetables and fruit should be added to the diet, which will still be mainly milk. It may be well here to append the table of instructions issued to mothers at Paddington Green Children's Hospital, which may be made to serve as a model either for private or hospital practice :

## HOW TO BRING UP BABIES.

### FEEDING.

#### I.

**If the mother is perfectly healthy and has plenty of milk,** breast milk alone should be given until the infant is 8 months old.

Suckle every two hours by day and twice by night until the child is 3 months old ; then suckle every three hours by day and once only by night. Too frequent suckling makes the milk poor and does not satisfy the baby.

The mother's nipples should be bathed with warm water both before and after suckling. Also wash the inside of the child's mouth with a small piece of clean linen and warm water each time after the breast is taken. This will prevent "Thrush."

Begin to wean at 8 months and wean completely at 9 months. Between the 8th and 9th month let the child have three times a day a mixture of two parts of cow's milk and one part of barley water, sweetened with one lump of sugar or one-third of a teaspoonful of Extract of Malt (*not* Fluid) to each hottle. The cow's milk should be just brought to the boil. The barley water should be made as follows : wash one tablespoonful of pearl barley and put it in a saucepan with one pint of cold water. Let it come to the boil and simmer beside the fire for half an hour. Strain and use as required : should be prepared fresh twice daily.

#### II.

**If the mother has only a little milk,** the child should still have it ; give also one part of cow's milk and two parts barley water (made and sweetened as above).

There is no harm in mixing the milks. It is better to get ordinary dairy milk than milk from one cow.

Should diarrhœa or vomiting come on, give equal parts of milk, lime water, and barley water.

#### III.

**If for any reason the breast cannot be given,** feed as follows :

*Up to 3 months :* one part of cow's milk and two parts of barley water—prepared and sweetened as above—every two hours by day and twice by night, in quantities of about six tablespoonfuls at each feed.

*Between 3 and 6 months :* equal parts of cow's milk and barley water may be given—one and a half to two pints a day. One-third of a teaspoonful of butter, or a teaspoonful of cream may be given twice daily.

*Between 6 and 9 months :* two parts of cow's milk to one part of barley water. Then add gradually more milk and less barley water until at 9 months the child is taking plain milk, heated as above.

*On no account give* any infant's food, condensed milk, bread, biscuits, or tops and bottoms until the child is 9 months old except by doctor's orders.

If the cow's milk does not seem to agree, consult a doctor, not the chemist.

*Never give babies, at any age, sweets, pastry, fruit, cheese, salt meat, salt or fried fish, tea, wine, beer, or spirits.*

*Between 9 and 12 months:* beside one to one and a half pints of cow's milk, the child may be given—not oftener than once in the day—any plain milk-pudding, porridge made with milk, or bread and milk made as follows: put a slice of *stale* bread without crust to soak in a basin of cold water for two hours; then pour off the water, beat up the bread, and pour over it a quarter of a pint of boiling milk. Sweeten with loaf sugar. This should be freshly made for each meal.

*Between 12 and 15 months:* add to the above, potato and gravy, or half an egg once daily.

*After 18 months:* finely minced or shredded mutton and fresh fish may be added, but cow's milk should still be the principal food.

Feed only at meal times. Never between meals, "Just to keep them quiet." Babies often cry, not because they are hungry, but because they are thirsty. A little pure water or barley water flavoured with orange juice will satisfy them.

The bottle should have a nipple, but no tube. Scald it out both before and after use and cleanse with a brush.

Prepare only enough milk for one meal. Never give what is left over in the bottle for the next meal. Taste the milk before feeding, and be sure it is not sour or smoked.

#### GENERAL DIRECTIONS.

I.—*Sleeping.* The child should sleep in a cot or basket alone. Many babies are overlaid every year from sleeping with their parents.

If they kick off the bedclothes, put them in long flannel night-gowns, fastened below the feet and at the wrists and throat. They must not lie between window and door, or fireplace and door. Keep the window open all night in hot weather. Keep a small fire burning all night in cold weather.

II.—*Clothing.* Should be loose round the chest and close round the belly. Do not let them go about with nothing on below the armpits but petticoats. A flannel binder round the belly and warm drawers should always be worn.

III.—*Washing.* Wash them all over with soap and warm water night and morning. Dirty children are always delicate. They will not take cold if carefully dried, especially about the head and ears, after the bath. It is a good plan to put them to bed between the blankets for half an hour after the morning bath.

*Fresh air and sunlight* are nearly as important as food to children. Take them out every day in fine weather.

**Curative.**—*General.*—When the disease is established, the effect of proper treatment is generally most marked. All artificial foods should at once be cut off and the child put upon a diet of fresh scalded cow's milk, properly diluted according to the age of the patient. With this many authorities recommend the administration of fresh meat juice.

More important than either of these, however, is the addition of fresh fruit and vegetables to the dietary. The most useful fruits are oranges, lemons, and grapes; the vegetables may be dressed in the ordinary manner or given as soups.

The drug treatment does not call for much notice. There is no specific drug for the disease, and all that is necessary is to treat on ordinary medical

ines any complications that may arise. The child must be placed under the best possible hygienic conditions, and if rickets be present that must, of course, receive appropriate treatment (see p. 208).

*Local.*—The treatment of the affected bones is of importance. Absolute rest in bed must be insisted upon, both on account of the liability to fracture, and because the child is very apt to suffer from severe attacks of syncope. For the first of these reasons also the greatest care must be taken in handling the child while performing the ordinary nursing functions.

The limb affected should be put at perfect rest upon a suitable splint, and any fracture that may occur must be put up in suitable apparatus. Sandbags will, however, often be found better for fixing the limb than splints, as the tenderness is extreme. A sheet or towel is placed over the limb and sandbags of suitable size rolled up in each end. As the disease subsides, splints may be applied, and union will occur satisfactorily.

The subperiosteal extravasation usually becomes absorbed as the child improves under treatment; rest will facilitate this. Sometimes, especially when there is some pyrexia and much tenderness, it may be impossible to be sure whether or not there is suppuration going on beneath the periosteum. The question can easily be cleared up by the use of the trochar and cannula or a large aspirating needle. Should the extravasation be excessive, however, absorption will be very slow, and under these circumstances, provided that the child is otherwise improving, it may be advisable in exceptional cases, when absorption has almost come to a standstill, to cut down upon the swelling, incise the periosteum, and turn out all the clots. We have operated with great advantage in this manner. A sufficiently free longitudinal incision is made into the swelling and the clots removed partly by the finger, partly by gentle irrigation with 1-8000 sublimate solution, and partly by compressing the limb. When as much of the clot has been removed as possible, the wound is sewn up without a drainage tube, and the usual cyanide dressings are applied. It is well to put on a large mass of wool outside this, and to fasten it firmly on so as to exert some compression on the limb and prevent re-accumulation of blood.

Slight oozing only takes place beneath the periosteum after the operation, and this is rapidly absorbed if the limb be kept at rest on a suitable splint. By treating these cases in this way the absorption of the effusion will be hastened, the adhesions between muscles, etc., lessened, and the course of the case shortened. The operation is of course only permissible under the strictest antiseptic precautions; septic infection would entail widespread necrosis at the very least, as the periosteum in these bad cases is separated from the bone throughout the entire diaphysis.



## CHAPTER XIV

### OSTEOMALACIA: OSTEITIS DEFORMANS: LEONTIASIS OSSIUM: ACROMEGALY: ACTINOMYCOSIS AND TUMOURS OF BONE.

#### OSTEOMALACIA.

THIS is a disease which usually occurs in women after pregnancy, and the chief manifestation of which is softening of the bones; it affects the whole skeleton and leads to great deformity. There is rarefaction of the bones with loss of calcareous salts; the bones at first are slightly enlarged, the medullary cavity is increased in size and contains red marrow, while the compact tissue becomes much thinned and is often perforated like a sieve. The bones are extremely liable to fracture, and, short of that, they bend in a most extraordinary manner. The disease is extremely grave and usually proves fatal in about two years from its commencement; death occurs from cachexia, from asphyxia, or from some acute affection of the respiratory organs.

**Treatment.**—The patient should be put under the best hygienic conditions. Among drugs, phosphorus, phosphoric acid and more especially phosphate of zinc (a twentieth or a twenty-fifth of a grain in pill three times a day) are advocated, but they do not seem to produce any particular effect. If the patient be pregnant it is well to produce abortion. Improvement has been recently reported from the use of tabloids of bone marrow, while some observers report good results from oöphorectomy; but the main dependence must be placed on the bone marrow tabloids. Those usually supplied contain  $1\frac{1}{2}$  grains of marrow, and two or more may be given three times daily.

#### OSTEITIS DEFORMANS.

This disease usually occurs after the age of forty-five, and affects males more often than females. It begins insidiously with slight pain and

aching in the bone ; it generally starts in the tibia, spreads to the femur, and gradually affects the chief bones of the skeleton. The bones become enlarged and heavy, but they also bend, so that the femur and tibia become bowed forward, and walking is difficult from the increased weight, deformity, and muscular weakness. The spinal column becomes bent, rigid and thickened. There is loss of height, the hands hang lower than usual, the chin is raised and the chest is sunk on the pelvis.

The changes consist of absorption of the bone trabeculæ and rarefying osteitis, in parts resulting in the formation of large and irregular Haversian canals, while in other parts formative changes are going on. The cause of the trouble is not known. The disease usually progresses steadily, and the patient ultimately dies of exhaustion, though in some cases bone tumours may appear, and death not infrequently results from them.

**Treatment.**—Practically nothing can be done. The patient is generally put on a milk diet under the best hygienic conditions, alkalis are given, and tabloids of bone marrow or thyroid extract may be administered. Massage is employed with the view of keeping the muscles in action, but nothing seems to have any power in arresting the disease.

#### LEONTIASIS OSSIUM.

This disease is characterised by large bony outgrowths affecting the upper jaw and sometimes the skull. They form masses of spongy bone, which may fill up the antrum, the nasal cavity or the orbit, and press against the base of the skull, causing blindness from pressure upon the optic nerve, and ultimately death from intra-cranial pressure.

Here also there is no remedy. In some cases the bosses on the upper jaw may be chiselled away if they project into the orbit, so as to save the eye, but as a rule the disease recurs almost immediately.

#### ACROMEGALY.

This is another disease for which there is also little to be done. It generally commences between the ages of fifteen and thirty-five, and consists in enlargement of the hands and forearms, the feet, the jaw, and sometimes of other bones. It is accompanied by mental slowness and often imbecility, wasting of muscles, exaggeration or loss of reflexes, and increasing weakness. The bones are more porous than usual. The cause is unknown ; the pituitary body has been found enlarged in several cases. Many giants are acromegalic. Tabloids of thyroid extract or of pituitary body are usually prescribed, but treatment is absolutely futile.

## ACTINOMYCOSIS.

This disease is due to a fungus called the actinomyces, which is common in cattle. It may affect either the soft tissues or the bones, and it has three main seats—the mouth and its neighbourhood, especially the bones, the respiratory, and the abdominal organs.

We need here only refer very shortly to the disease as it affects the bones. Of these the lower jaw is the one most commonly attacked, and the affection begins as a hard tumour, generally about the angle of the jaw. This tumour increases slowly in size until suppuration occurs, and an abscess forms and bursts, either into the mouth or externally. The disease goes on spreading, and destroying the bone which becomes worm-eaten and excavated, and the pus which escapes contains yellow granules. If a few drops of pus be received in a watch-glass, spread out and held up to the light, these yellow grains can usually be seen very distinctly: if put under the microscope, they are found to be composed of clumps of actinomyces. The disease, when once established in the bone, may lead to metastatic deposits elsewhere, sometimes in the glands, sometimes in other bones. There is usually no fever accompanying the affection, which varies very much in its virulence, sometimes being quite mild, and in other cases being almost beyond the reach of treatment.

**Treatment.**—As soon as the disease is evident, the affected bone should be cut down upon; if only a small portion be affected, the diseased area should be completely excised; if it be too extensive for this, the swelling must be thoroughly opened and scraped away until as far as one can judge the whole disease has been removed. Very satisfactory results are obtained in this way; the disease is at first quite local, and does not recur if only the operation be done thoroughly enough. Iodide of potassium in large doses (gr. xxv.-xxxv.) three times a day is also useful.

## TUMOURS OF BONE.

Many tumours occur in bones, developing either as primary growths, as secondary deposits in connection with tumours in distant parts, or from extension of tumours commencing in the soft parts in the neighbourhood.

The primary tumours of bone are chiefly exostoses, chondromata and various forms of sarcomata. Secondary tumours are sarcomata or carcinomata, arising either by metastasis or by extension from neighbouring parts. Hydatid cysts also occur.

**TREATMENT.—Of primary tumours.**—The treatment of tumours of bone has already been referred to under the treatment of tumours in general (see Part. I., Chapter XV.).

**Of Exostosis.**—The exostoses occur in two forms, the ivory sessile variety found chiefly on the skull, and the spongy pedunculated form in

the neighbourhood of the epiphyseal lines. The spongy exostoses may be multiple, and may interfere with the movements of the joints or muscles in their neighbourhood; whenever a patient has an exostosis which is causing him any inconvenience there should be no hesitation in removing it unless it be in some inaccessible region.

The removal of an ordinary spongy exostosis is a comparatively easy matter because ossification generally commences very early at the point of junction of the exostosis with the bone, and growth only proceeds in connection with the layer of cartilage which covers its surface; hence an exostosis of large size may have a very narrow neck.

An incision is made down to the tumour, the neck is cleared, and chiselled off or clipped through with bone forceps, after which the growth is shelled out of its capsule and the soft tissues. The operation must be performed strictly aseptically; before the antiseptic period even this slight damage to the bone was often followed by severe sepsis, and many patients died of pyæmia; at the present time, however, they are perfectly simple and safe.

The treatment of ivory exostoses is not so easy; they usually occur on the bones of the skull, and seldom attain any great size; as a rule they do not cause any trouble beyond possibly a little deformity. They are sessile and very dense, and a widespread fissured fracture of the skull may be produced in chiselling them away; therefore, unless special circumstances, such as pressure on nerves or important structures such as the eye, call for their removal, they are better left alone (see also Part I., p. 260).

**Of Chondroma.**—The chondromata are commonly met with in bones; they occur most frequently in connection with the phalanges and metatarsal or metacarpal bones. They are usually multiple, and grow either from the outside or in the interior of the bone. They are usually benign, and as a rule it is sufficient to cut down on them, remove the projecting portion and then thoroughly chisel or gouge away any deposits of cartilage which may be present in the neighbourhood. If growing in the interior of the bone, the outer layers of the bone must be chiselled through, and then the soft chondromatous material scooped out. Sometimes, no doubt, recurrence takes place after these operations, but they can be repeated without risk, if the operation be done aseptically. In some cases these enchondromata do not appear to be quite simple, and where there is any suspicion of malignancy, it is better to amputate if possible.

**Of Sarcoma.**—The sarcomata of bone may be of various kinds. Perhaps the most common is the *osteo-sarcoma*, or *periosteal sarcoma*, beginning in the periosteum and spreading along it. These tumours usually show imperfect ossification, and the secondary tumours are similar; they are very malignant, and the chances of curing the patient are very small. Amputation wide of the disease affords the only chance of success, and no attempt should be made to save any portion of the affected bone; the operation must be performed through or above the neighbouring joint.

Unfortunately, metastatic deposits occur very early, and most usually affect the lungs.

*Spindle-celled sarcoma* is also common in connection with the periosteum of bones, and in this case amputation through the joint or bone above is also necessary.

*Round-celled sarcoma* also occurs in connection with bones. This growth is often found in the interior of the bone, its most common seat being perhaps the head of the humerus. It is very malignant, but curiously enough, the tumours which commence in the interior of the bone do not spread widely throughout it, so that if the lower end of a bone, such as the femur be affected, amputation below the trochanters may be done in preference to enucleation of the entire bone; the medulla must be examined carefully to see that no disease has spread up it. If the growth be in its most common situation, at the head of the humerus, the amputation must be through the shoulder joint, taking care to remove all the ligaments and muscles around.

*Myeloid sarcomata* practically only occur in connection with bone. They are chiefly met with in the lower end of the femur, the lower end of the tibia, and the lower jaw. They are the least malignant of all the sarcomata; in fact it is an open question whether they give rise to secondary deposits, and therefore the treatment need not be so drastic as that of the other forms. A good many cases are now on record where the disease has not recurred after the growth has been thoroughly scooped out of the bone, but in doing this it is necessary to be quite sure that all the soft tissue has been removed. Sometimes this is not feasible when the myeloid sarcoma has been in existence for some time, because, after the growth is scooped out, no bone is left behind; in these cases it is well to amputate, but the operation need only be done through the bone at a short distance above the tumour.

**Of secondary tumours.**—As a rule there is no object in operating upon the secondary malignant tumours of bones, such as epitheliomata or carcinomata, for their occurrence implies such general infection of the body that it is not worth while subjecting the patient to the risk of operation: as a rule, therefore, the treatment in these cases consists in applying proper apparatus with the view of steadying the part should fracture have occurred, and of relieving the pain.

## DIVISION II.—AMPUTATIONS.

### CHAPTER XV

#### AMPUTATIONS: GENERAL CONSIDERATIONS.

##### PRESENT POSITION OF AMPUTATION IN SURGERY.

IN reviewing the position that amputation occupies in surgery at the present time, one cannot fail to be struck by the great changes that have taken place in recent years; changes so profound that it is no exaggeration to say that our views on amputation have been quite revolutionized. Among the most important alterations we may briefly notice the following:

**Greater deliberation of present-day operating.**—The first great point of importance is the entire disappearance of those brilliant operations in which the limb was removed (usually by transfixion or by the circular method) in a few seconds. Their place has been taken by more careful, deliberate and elaborately planned operations, in which the chief consideration is not the length of time taken in removing the limb, but the proper formation of a sound stump provided with a sufficient covering of soft parts, and as long as the condition of the tissues will allow. This change has been chiefly brought about by the introduction of anæsthetics, by means of which the surgeon is able to take time over the operation, and to plan and carry out its steps with due deliberation.

**Infrequency of amputations.**—A second and equally striking point is the comparative infrequency with which amputation is now performed. It was formerly the custom to submit to amputation many cases in which the question does not now even occur to the surgeon, for, thanks to the introduction of asepsis, conservative surgery is carried to a degree formerly undreamt of. In compound fracture, for example, amputation was formerly the rule, but now it is possible to save a large proportion of the cases, either by employing conservative methods, or, at the worst, by means of partial amputations which were out of the question at a time when the risk of sepsis was constantly present to the surgeon's mind.

**The increasing favour of irregular flaps.**—A third very noticeable fact is that nowadays amputations are rarely carried out on the hard and fast lines formerly laid down for the surgeon's guidance. The employment of irregular flaps and the use of irregular amputations is coming more and more into vogue; in fact, the particular method of amputation that is adopted in any given case now depends, not upon the surgeon's predilection for any one form of incision or kind of flap, but upon the actual conditions of the part. Thus, in amputating for injury, the main idea present in the surgeon's mind is how to insure the patient a stump that shall be as useful as possible, and he will therefore often shape his flaps in an irregular manner, so as to obtain a longer or more useful stump. To describe the various irregular amputations that are constantly being done would be quite impossible, while it is safe to say that many of the set amputations found in text-books are only performed upon the cadaver. A factor which has greatly assisted in this direction is the introduction of antiseptics. By their means the chances of inflammation in the stump have been greatly diminished, the risk of sloughing of partially-injured flaps has been reduced to a minimum, while the danger of secondary hæmorrhage has practically disappeared. Thanks to asepsis, we are now enabled even to fashion the flaps from tissues that have been bruised by the injury, so long as their vitality has not been markedly interfered with and the circulation in them remains good after they have been cut; in the formation of flaps, tissues which would formerly have been removed are nowadays utilized without the least hesitation.

**Predominance of the skin-flap.**—Another noticeable feature in present-day methods is the increasingly frequent use of skin-flaps, and the diminution in the amount of muscle employed to cover the bone. This depends also upon the fact that inflammation is absent from aseptic wounds, and that the swelling and consequent sloughing of the skin-flaps which led to their rejection in former times is therefore not likely to occur.

#### THE ESSENTIALS OF A GOOD AMPUTATION.

There are three essential points in all cases of amputation. In the first place the bone must be satisfactorily covered; in the second, the diseased or injured parts must be completely removed; and in the third place, the limb remaining must be as useful as possible. Where sufficient covering has been provided for the bone, the end of the stump will be rounded and supple, but firm enough to bear considerable pressure without pain.

**Position of the cicatrix.**—When the end of the stump is required to bear pressure, the cicatrix must not be in such a position that it will be exposed to any pressure from the divided end of the bone; it is also most important that the flap shall not be adherent to the bone, and that the cicatrix shall be painless. These requirements can generally be easily arranged for with a little care. In amputating in the lower extremity the

incision is so planned that the line of union of the flaps lies behind the bone, because the posterior muscles of the limb are stronger, and contract to a greater extent than those on the front. Were the flaps to meet upon the anterior aspect of the limb, this contraction would cause the scar to be pulled directly over the end of the bone.

**Avoidance of adherent flaps.**—Adhesion of the flaps to the bone is avoided by making sure that the entire wound heals by first intention. If this be the case, and the flaps be of sufficient length, they will not adhere to the bone, for firm adhesions between the latter and the deeper tissues are usually the result of suppuration and granulation of the flaps.

**Painless scar.**—If the large nerves be divided at a higher level than the other structures in the flap there is no chance of their being pressed upon by the cicatrix or becoming adherent to the bone. This is a point of the highest importance, because, should the nerves become involved in the scar, bulbous enlargement will occur, neuritis will be set up and the patient will suffer from intense neuralgic pain, aggravated by the slightest pressure. The ends of the tendons should also be cut short unless there be some special reason for retaining their action upon the stump; if adherent to the end of the bones, they may pull upon them and materially interfere with the patient's comfort and his ability to bear pressure upon the stump.

#### METHODS OF AMPUTATING.

**THE CIRCULAR METHOD.**—This was the earliest form of amputation known, and was for a long time in general use. It was subsequently elaborated into what is known as the modified circular method,—a plan still frequently adopted for amputating in the upper extremity. In the circular method, the skin and subcutaneous tissues are first divided by one sweep of the knife drawn circularly round the limb. The divided structures are then forcibly retracted for two inches or more by an assistant, and a series of circular sweeps of the knife is made through the muscles and soft structures down to the bone at the level of the edge of the retracted skin. The whole of the soft structures are then retracted as far as possible, and the bone is cleared and sawn at a point well above the division of the muscles (see Fig. 65). The result of this is that when the structures are allowed to fall into position again, a somewhat conical depression is seen in the stump, at the apex of which lies the divided end of the bone, the base being formed by the circular cuff of skin.

**Objections.**—This method however has many objections. In the first place, it is often difficult to perform, especially if the limb be conical, for the retraction of the different layers is not easily effected, and if the cuff of skin has to be dissected up and turned back, one of the chief advantages of the operation, viz. its celerity, is sacrificed. In other cases again, the retraction of the soft parts may be much hindered by matting together of



the muscles, etc., as a result of old inflammatory changes. When the edges of the incision are sutured, the cicatrix lies over the end of the bone, and may give rise to considerable puckering of the stump. Moreover,

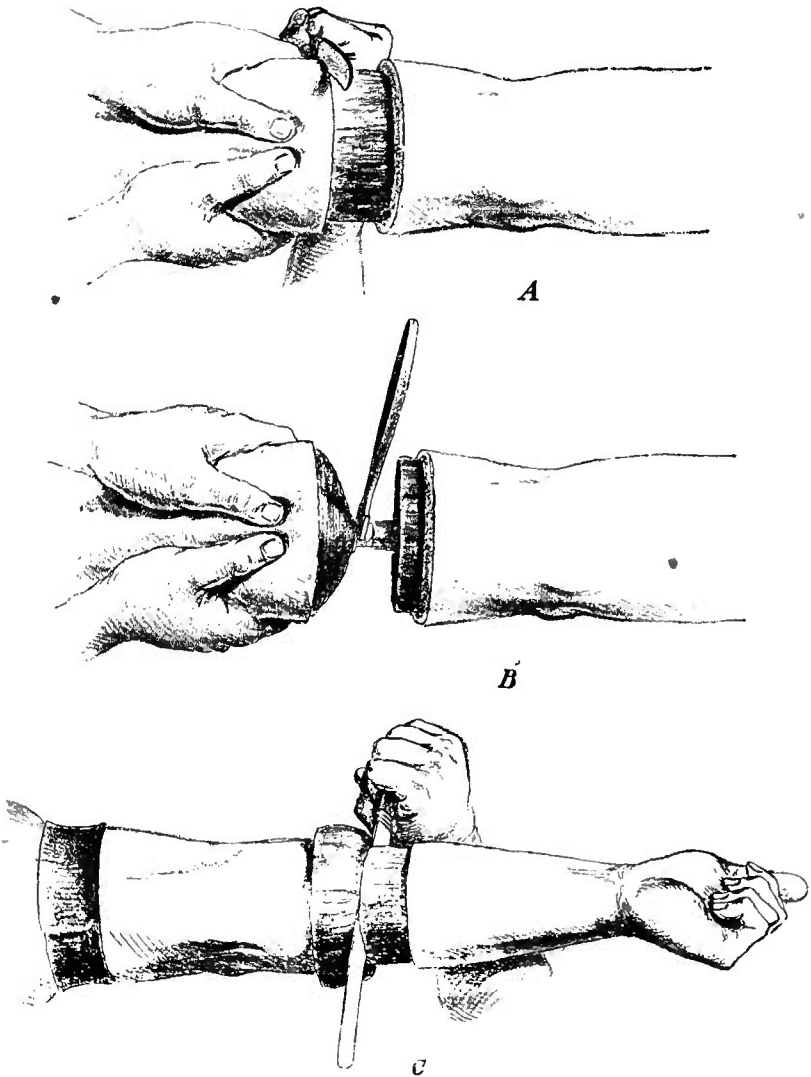


FIG. 65.—CIRCULAR METHOD OF AMPUTATION. In *A* the skin has been divided by a circular sweep of the knife, and is being strongly retracted by an assistant prior to the circular division of the muscles which is seen accomplished in *B*, where the periosteum, after being divided circularly, is being stripped up by a rugin. *C* shows another but slower method, in which the cuff of skin is dissected up and turned back before the circular incision is carried through the muscles.

the skin flap is by no means abundant, and there is often considerable tension when the edges are brought together.

**THE MODIFIED CIRCULAR METHOD.**—The circular method has been put aside in favour of what is termed the modified circular method, by which, in place of the circular division of the skin, two equal

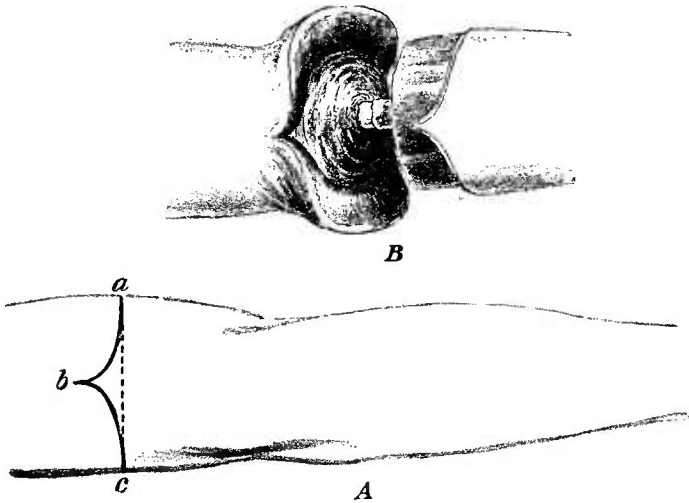


FIG. 66.—THE MODIFIED CIRCULAR METHOD OF AMPUTATION. The dotted line *ac* in *A* is the ordinary incision in the circular method, while the thick line *abc* shows the modified circular incision. The skin flaps are shown in *B* as well as the circular division of the muscles.

flaps of skin and subcutaneous tissue are cut,<sup>1</sup> just slightly longer than the cuff of skin produced in the circular method just described. By dividing the skin in this manner, the division of the muscles is greatly

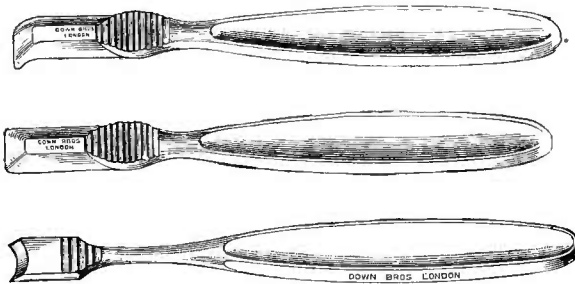


FIG. 67.—RUGINES OR PERIOSTEUM DETACHERS. These are of different shapes according to the purposes for which they are used. The concave edge of the lowest of the three is for detaching the periosteum from a circular bone.

facilitated, and there is no difficulty in the retraction of the skin flaps. After the flaps have been raised, the muscles are divided by a series of

<sup>1</sup>In the case of a fore-arm of ordinary size, the lower limit of the flaps will be about  $1\frac{1}{2}$  inches below the seat of the circular division of the muscles, and this again about  $1\frac{1}{2}$  inches below the point of section of the bone. In the upper arm each of these measurements will be increased to  $2\frac{1}{2}$  inches or more.

circular sweeps of the knife; after each cut they are firmly retracted until the bone is exposed opposite the proposed point of division (see Fig. 66). It is well to carry the last sweep of the knife right down through the periosteum, which is thus divided circularly on the same level as the muscles; as the latter are retracted, the periosteum should be stripped up by a rugine (see Fig. 67) along with the muscular mass. The result of this is that, when the bone has been sawn and the parts relaxed, a tube of periosteum falls over the cut end of the bone and thus produces a nicely rounded end for it. The muscles should never be first stripped off the periosteum, and the latter then separated from the bone. Muscles and

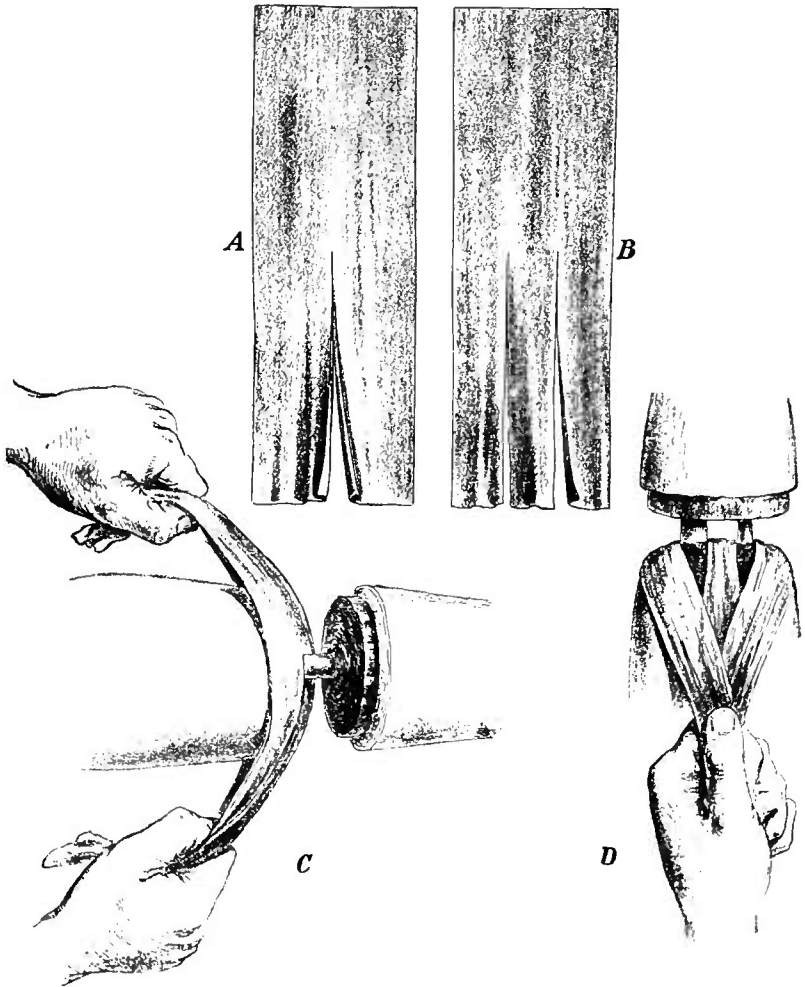


FIG. 68.—BANDAGE RETRACTORS FOR AMPUTATIONS.

*A* and *B* show two-tailed and three-tailed bandage retractors respectively. *C* shows the method of using the two-tailed retractor to protect the soft parts, while *D* shows the three-tailed retractor used for a similar purpose.

periosteum should be stripped off the bone together or the vitality of the latter will be endangered.

*Retractors.*—In the circular method the retraction of the muscles is often difficult, especially in a conical limb like the thigh, and there is some danger of wounding the assistant's fingers unless mechanical means of retracting the muscles be employed. A very simple form of retractor which can easily be extemporized is made from a broad piece of bandage or muslin which has been carefully disinfected. This is split longitudinally down the centre for about half its length (see Fig. 68, *A*), and then the two tails thus formed are applied one on either side of the bone, and an assistant, seizing the two tails with one hand and the undivided end with the other, firmly retracts the soft parts (see Fig. 68, *C*). A similar retractor can be made by taking two pieces of ordinary bandage and laying one on either side of the bone, crossing the ends and making traction upon them. When amputation is being performed in a limb with two parallel bones, such as the fore-arm, the retractor may conveniently take the form shown in Fig. 68, *B*, where a piece of muslin is split into three tails, the centre one being passed between the two bones, and the lateral ones outside them. Another form of retractor, suitable for limbs in which there is either a single bone or two parallel ones, is shown in Fig. 69.




FIG. 69.—METAL RETRACTOR FOR AMPUTATIONS. By sliding one half of the retractor over the other the size of the central hole can be varied to fit either a single or two parallel bones.

**Cases suitable for this method.**—The modified circular method is still performed in certain situations, such as in the upper extremity. Here it is no drawback to have the cicatrix lying directly over the ends of the bone; on the contrary, this may, as we shall presently mention, be actually desirable. In the lower extremity, however, the method is generally modified, by making one of the flaps longer than the other; as a rule the anterior flap is made considerably longer than the posterior, so that the former can be folded

over the end of the stump, and the cicatrix made to lie well behind the cut end of the bone. During the healing process, the cicatrix becomes still more markedly pulled up on the posterior surface of the limb.

**THE FLAP METHOD.**—In the so-called “flap method” the circular division of the muscles is also abandoned. Two flaps are made, generally of unequal length, the commonest form being that with a long anterior and a short posterior flap. The first two inches or so of the longer flap should consist merely of skin, subcutaneous tissue and deep fascia, but as it is dissected upwards above this point, the knife is gradually made to take up some of the muscle in the flap; a steadily increasing thickness of muscular substance is then taken up as the flap is

raised, so that, when the point is reached at which it is proposed to divide the bone, the muscle is divided right down to that structure (see Fig. 70). In the posterior flap it is well to take up only skin, subcutaneous tissue, and deep fascia for the first two inches or more, and then to complete the flap by cutting through the muscles more or less directly down to the bone. There is no need to take up the muscle gradually as in the other flap on account of the greater contraction of the muscles on the posterior aspect of the limb. When the flaps have been retracted, the bone is divided at a slightly higher level than the base of the flaps. Here again, as in the circular method, a collar of periosteum may be raised in a similar manner and with a similar object. No retractors are required to keep the muscles out of the way of the saw in this form of amputation. The flaps are folded back and the soft parts are then well out of the way of harm.

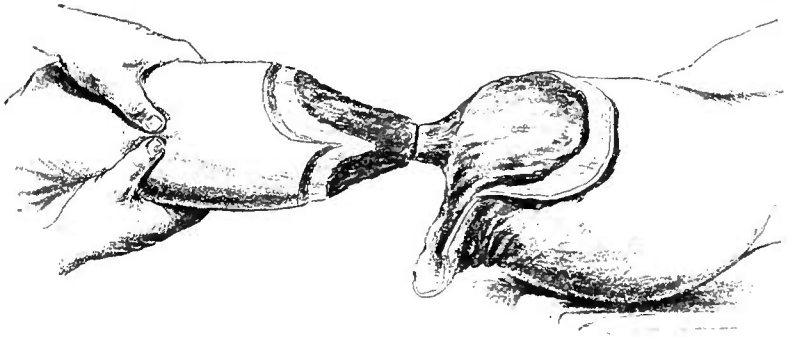


FIG. 70.—FLAP METHOD OF AMPUTATION. The flaps—long anterior and short posterior—are cut from without inwards. The steps of the operation are fully described in the text.

The advantage of fashioning the lower end of the flaps from the skin and subcutaneous tissues only is that they can be brought together more easily and with less tension than can flaps cut by transfixion, or those in which the muscle is taken up from the first. Either of these procedures renders it exceedingly difficult to tuck in the large protruding muscular mass met with when the wound is being stitched up; owing to its elasticity, the skin retracts considerably, while the muscles on the other hand protrude beyond it. After transfixion operations it was not infrequently necessary to cut away a quantity of muscle before the flaps could be sewn up without tension.

**The length of the flaps.**—It is important to remember that the skin is a very elastic structure and will retract considerably after it has been divided; the skin flap therefore undergoes considerable shortening after it is raised. Similarly the muscles retract and not only become shorter themselves but pull the skin up along with them. Although the skin can be again stretched to its original length when the wound is stitched up, there is a certain risk of interfering with its vascular supply in

doing this, and, therefore, whenever the flap method is employed, the flaps should always be cut longer than is necessary to just cover the ends of the bone. If no retraction had to be taken into consideration, it is obvious that the combined length of the two flaps should be equal to the diameter of the limb at the point of section of the bone, but as a matter of practice it is found that if the flaps be made this length they will provide insufficient covering on account of the retraction we have just alluded to. In order to allow for this therefore they should be cut at least one-third longer than the diameter of the limb at the point of section of the bone. It was formerly the custom to fashion the flaps even longer than this, with the object of avoiding even the slightest tension upon the stitches; at the present time, however, when we are sure of obtaining union by first intention, a slight amount

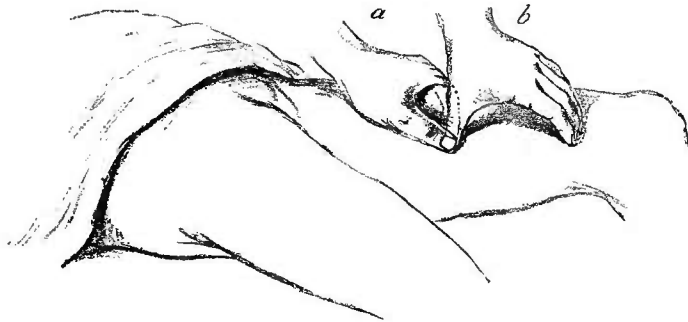

FIG. 71.—HOW TO ESTIMATE THE LENGTH OF THE FLAPS IN AMPUTATING. The transverse diameter of the limb at the point where the bone is to be sawn is ascertained. This is position *a*. Keeping the thumb in its original position, and maintaining the same distance between it and the forefinger, the hand is rotated into position *b*, which thus enables the length of the diameter of the limb to be marked along the thigh. This is for an amputation by lateral flaps, and the length of each flap would therefore be two-thirds of this measurement.

of stretching of the skin flap is of no consequence, while on the other hand it is important to avoid a long dependent bag of skin at the end of the stump, in which blood and serum may easily accumulate and interfere with union. Another point of great importance nowadays is that unduly long flaps entail an unnecessarily high division of bone. At the same time, if the beginner be in any doubt as to the length of his flaps, it is better to cut them too long than too short. It is a perfectly simple matter to cut them down afterwards, and this is far better than the fault so often committed of cutting the flaps too short and of being obliged therefore to take away more bone in order to enable them to come together. The point of bone section should always be the fixed point.

*How to estimate the length of the flaps.*—The length of the flap may be roughly estimated by grasping the limb at the point where it is proposed to divide the bone without compressing the soft parts at all; if antero-posterior flaps are to be made, the antero-posterior diameter of

the limb should be grasped, whilst the lateral diameter is estimated when lateral flaps are to be cut. Having done this, the thumb should be kept stationary whilst the rest of the hand is rotated upon it, without altering the distance between the thumb and the forefinger, so as to bring the latter vertically below the former (see Fig. 71). The distance thus marked off will roughly indicate the length of the anterior flap, and a third of it that of the posterior. Sometimes of course it may be advisable to have an anterior flap only, in which case the span thus marked out will require lengthening by about a third in order to give the right measurement.

**THE RACKET METHOD.**—Various other amputation methods are employed, the one most in favour being the so-called “racket incision.” In amputations of the fingers at the metacarpo-phalangeal joints, for instance, this is a very useful method and is done as follows. A straight incision is commenced about an inch above the joint and is carried vertically down

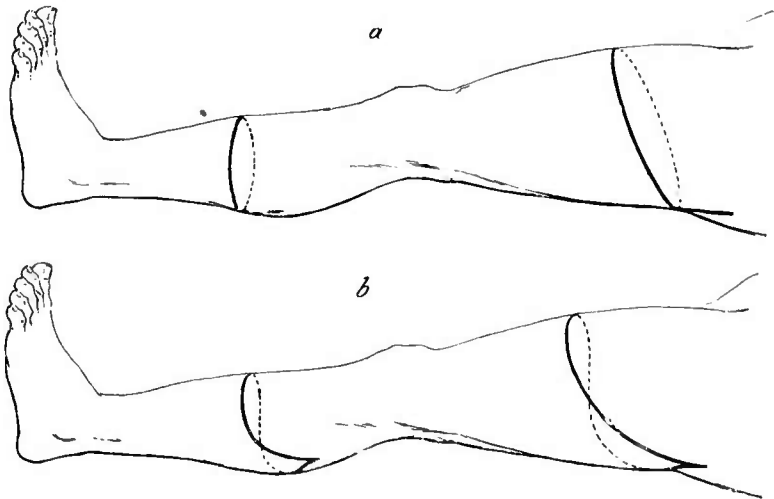


FIG. 72.—VARIOUS TYPES OF RACKET-SHAPED INCISIONS. In the upper figure *a* are seen the primary types, the simple circular incision with the vertical handle. In the leg the incision is transverse to the long axis of the limb, in the thigh it is oblique. The lower figure *b* shows the evolution of the “hooded flap” (in the leg) and the “oblique lanceolate” incision of Kocher (in the thigh) by sloping the incision gradually from the greatest transverse diameter of the racket to the upper limit of the handle.

over the knuckle; when this has almost reached the level of the web, it is carried around the base of the finger and back again to the point at which it diverged from the vertical incision. This racket-shaped incision is really a combination of an oval with a vertical incision, the advantage of the latter being that the bone can be cleared at a point considerably higher up than the base of the flap (see Fig. 72, *a*).

**Other modifications.**—This method, or some modification of it, is applicable to a large number of cases. A very useful adaptation has been introduced for amputations in the lower extremity. In this the oval

of the racket, instead of starting abruptly from the lower end of the vertical incision or handle, begins to diverge almost from the very commencement of the latter, so that practically there is no vertical incision at all, the flap being a single long oblique one (see Fig. 72, *b*). Anterior oblique flaps made in this way in the lower extremity fall over the end of the bone and produce a more or less vertical cicatrix situated well behind the bone. This form of flap is often spoken of as the "hooded flap" and is one of which we are particularly fond in amputations of the lower extremity.

Besides these general types, there are a large number of specially devised amputations for use in particular situations. For example, there is a most admirable amputation known as Syme's, for use at the ankle, in which the skin of the heel is utilized to form the flap covering the ends of the tibia and fibula.

**IRREGULAR AMPUTATIONS.**—While, however, it is well to be intimately acquainted with all the typical methods of amputation suitable for different situations, it is of extreme practical importance for the surgeon to remember that he can modify any of these to meet the varying circumstances of any individual case, and that he may use lateral, oblique or irregular flaps according to the nature of the case with which he is dealing, so long as he is thereby enabled to provide a satisfactory stump without sacrificing more of the limb than is absolutely necessary. While no doubt the set operations may be of use in cases of disease, the patient's interests are nearly always better served, in the majority of cases in which the surgeon is nowadays called upon to amputate, by some irregular form of amputation than by one on old-fashioned lines.

#### METHOD OF PERFORMING A TYPICAL AMPUTATION.

We shall now describe a typical form of amputation, for example one by the flap method, and its after-treatment, so as to call attention to various details.

**Preliminary steps.**—Certain preliminaries require to be attended to before the actual performance of the amputation. These consist on the one hand in thorough disinfection of the skin and avoidance of all risk of infection of the stump, and on the other in taking measures to minimize the loss of blood during the operation.

**Disinfection.**—We have already dealt with this point very fully in Part I., p. 161. The skin for a considerable distance around the proposed area of operation should be first shaved, then rubbed over with turpentine to remove all grease, and thoroughly and systematically scrubbed with soap and strong mixture, some hours before the operation if possible; a gauze dressing is put on, and the disinfection is again repeated when the patient is under the anæsthetic. When there are septic sinuses in the immediate vicinity of the amputation, these should be scraped out



immediately before the operation and purified by introducing into them small pieces of sponge impregnated with undiluted carbolic acid. The skin in the neighbourhood of the sinuses should be covered with a wet cyanide dressing wrung out of a 1-20 carbolic acid or a 1-500 sublimate solution (it does not matter which). This dressing should extend almost up to the lowest limit of the flaps and should be firmly bandaged on with a wet aseptic bandage so as to prevent the discharge from the sinuses finding its way into the region of the amputation wound during the operation. This is necessary whether we have to deal with sinuses or with larger open sores. (Quite apart from the presence of sinuses, it is always well to wrap up the whole of the limb to be removed in a towel soaked in a 1-20 carbolic acid solution. It is difficult to asepticize the whole limb satisfactorily, and the assistant to whom the task of holding it is entrusted might readily infect the wound. This he cannot do if, instead of grasping the skin, he holds the limb encased in an aseptic towel. Wherever it is possible, however, the best plan is to place the limb in charge of an assistant who will have nothing to do with the rest of the operation.)

**Arrest of hæmorrhage.**—The next preliminary point is to arrange for the arrest of hæmorrhage during the amputation. This was formerly done by digital compression of the main vessel, but although this may be necessary even now in some operations, such as those about the shoulder joint, it is a comparatively ineffectual method. The blood supply of the stump is generally derived from more than one large vessel, and the compression of the main arterial trunk does not by any means arrest all the bleeding; moreover, when digital compression is employed, the assistant is apt to get tired, and may relax the pressure at an inconvenient moment. The best plan, whenever there is room to permit of it, is to encircle the limb by elastic tubing or by an elastic bandage—the so-called Esmarch's bandage.

**Esmarch's method.**—In Esmarch's complete method the limb is bandaged spirally with a firm elastic bandage from the extremity to a point well above the region of amputation. At the upper limit of this bandage a length of india-rubber tubing is stretched and wound horizontally around the limb, and when this is fastened in position the bandage is removed. By this means, no doubt, nearly all the blood in the limb is forced into the general circulation and thus is saved to the patient. There are, however, two important conditions in which there are such great objections to the method as to practically render it inapplicable. Should the amputation be done for malignant tumour, the result of compressing the latter by the elastic bandage may very well be to force portions of tumour substance into the circulation, and thus to give rise to secondary deposits elsewhere. Again, should septic conditions be present, as for example septic sinuses or cellulitis, pus may be forced by the bandage through the interstices of the tissues and may lead to general infection.

**Lister's method.**—A plan that is equally efficacious in rendering the limb bloodless is that advocated by Lister, who elevates the limb for three or

four minutes before the horizontal elastic tubing is applied. The effect of elevating the limb is to empty the veins by gravity and to cause the arteries to contract reflexly, so that on the one hand all the venous blood rapidly runs out of the limb, while on the other comparatively little arterial blood finds its way into it. The limb is kept elevated for about three minutes, and the elastic tubing is then applied horizontally in the desired position, as high above the seat of amputation as the anatomical conditions of the parts allow; it will then be found that practically as little blood is lost as when Esmarch's complete method is adopted. It is important however to remember that the limb should not be kept elevated too long, as otherwise the arteries will recover and dilate, and more blood will flow into the limb.

*Seat of tourniquet.*—In applying the tourniquet, it is important to put it on as far away as possible from the amputation wound; if it be applied too near to the seat of operation the tubing may offer a serious barrier to the retraction of the muscles, because it binds them firmly to the bone, so that they cannot well be pulled up. Another disadvantage is that the band is very apt to slip off over the flaps when the bone is sawn.

*Material for tourniquet.*—When the amputation is being performed in the lower extremity, a band of stout india-rubber tubing is the best material to employ; the muscles are numerous and fleshy, and considerable force is required to arrest the circulation satisfactorily. In the upper extremity, however, the use of stout tubing of this kind is apt to be accompanied by undue pressure upon the nerves, which may give rise to more or less temporary paralysis. A better plan is to substitute for it a broad elastic bandage wound several times horizontally around the limb; this exerts more equable and evenly diffused pressure. In certain special cases, such as amputations at the hip joint, etc., modifications of this method will be required; they will be referred to subsequently. In any case the tourniquet, either india-rubber or elastic bandage, should be disinfected by soaking for some hours before use in 1-20 carbolic acid solution. After the elastic tourniquet is removed there is no doubt unduly free and persistent oozing from the stump. In most amputations however it is unnecessary to keep the tourniquet in position long enough to produce any marked or lasting paralysis of the vessels, and therefore there is not the same objection to the use of the bandage in them as there is in various other more prolonged operations.

**Prevention of shock.**—In the more important amputations, and particularly in feeble subjects, the prevention of shock is a matter of the highest importance. The various measures both for the prophylaxis and treatment of shock have already been dealt with in detail in Part I., p. 139. The more important of these are performing the operation upon a warm table, preliminary injections of strychnine, and rectal enemata of brandy and beef-tea. As a rule, however, there is but very little shock, even in such amputations as those through the thigh, except in cases of primary

amputation done for injury where profound shock is present before the operation is done. In these cases, in amputations through the hip joint, and in those who are extremely feeble as the result of long standing disease, however, shock must be carefully guarded against.

**The amputating knife.**—The choice of the amputating knife is of some importance. It should not be too long, as otherwise it is difficult to mark out the flaps and to dissect them up firmly and accurately. When the amputation is to be done by cutting the flaps from without inwards, as is done nowadays, the knife chosen should not be more than six inches long. This gives the surgeon sufficient control over the blade, while at the same time it enables him to divide the muscles by broad sweeps of the knife. Should however the amputation be performed by a circular division of the muscle, or by flaps cut by transfixion, it will be necessary to employ a knife which is nearly a quarter as long again as the diameter of the limb at the point of division of the bone.

**Cutting the flaps.**—In amputating, the surgeon should stand on the patient's right of the limb to be removed, and the first points for decision are the spot at which the bone is to be divided and the length and position of the flaps. The directions for ascertaining the length of the flaps have already been given (see p. 230). It is well to cut the flaps from without inwards rather than to employ the transfixion method, which was formerly much in vogue on account of its greater rapidity. The great advantage of cutting the flaps from without inwards is that the surgeon is thereby enabled to gauge the relative amount of skin and muscle divided much more easily and accurately; the extra time consumed in the operation is trivial and of no practical importance.

**Shape of the flaps.**—The shape of the flaps is of great importance; they should be practically square, with merely the corners rounded off. The common fault with beginners is to make the flaps too pointed; that is to say, the line of incision is made to approach the middle line almost from the starting-point, whereas in order to get a satisfactory covering for the stump, it is necessary to carry the incision almost vertically down, parallel to the long axis of the limb, almost to the lower border of the flap. About an inch from this point it should curve slightly towards the middle line and then run transversely across the limb to a corresponding point on the opposite side, when after a slight curve upwards it should be carried almost vertically up to a point opposite to that from which it started. In order to prevent mistakes at a later stage it is well, especially for a beginner, to proceed to mark out the posterior flap before proceeding to dissect up the anterior one. This flap should be in most cases about a third the length of the anterior one, and is made by drawing the knife transversely across the back of the limb, just rounding off the flap slightly where this incision joins the lateral vertical ones.

**Raising the flaps.**—In cutting the flaps the edge of the knife must always be held strictly at right angles to the surface of the skin, as

otherwise the end of the flap will be bevelled, and an imperfectly nourished edge will be left which may lose its vitality. The incisions marking out the flaps should extend through the skin, subcutaneous tissue and deep fascia; the latter must always be taken up with the skin as it contains the main blood supply of the superficial structures. The skin flap is then gradually raised from its free edge. For the first two inches nothing but the deep fascia and the structures above it are raised, but after that the knife is made to gradually and obliquely divide the muscles so that more and more of this structure is taken up as the flap progresses, until as its base is reached everything is being peeled off right down to the bone (see Fig. 70). When the raising of the anterior flap is complete, it is held out of the way by an assistant whilst the limb is elevated and the posterior flap is raised from without inwards in a similar manner. Some authorities recommend that the latter should be cut by transfixion. This is no doubt more rapidly and more easily done, but it has the objection that there is no projecting margin of skin beyond the muscles, and that therefore there may be some difficulty in stitching up the stump. The only situation in which transfixion may be advantageously employed is in regions such as the lower third of the thigh or the fore-arm, where the structures divided by transfixion are mainly tendinous. As a general rule it may be said that a far neater and more satisfactory stump is obtained by the slightly slower but much more careful method of cutting both flaps from without inwards.

**Sawing the bone.**—After the flaps have been raised down to the bone they are firmly retracted by an assistant, and a succession of circular sweeps is made around the bone dividing the periosteum. A cuff of periosteum (see p. 227) may now be raised if the operator desires; as a rule this is unnecessary. The knife is then laid aside, the heel of the saw—which should have fine teeth—is pressed firmly over the bone and a groove cut by drawing the saw towards the operator from the heel to the point. The saw may be steadied while the groove is being cut by pressing the tip of the left thumb or forefinger upon the bone just above the proposed line of section; the blade of the saw is then pressed against this fixed point and cannot slip upwards. The bone is sawn through by light and rapid sweeps, the assistant taking special care to hold the limb absolutely horizontal. This is a somewhat difficult task; the assistant is apt on the one hand to push the limb up, in which case the saw becomes locked, while on the other, if reproved for doing this, he is apt to unduly depress it, so that after the saw has divided the greater part of the bone the remainder snaps off. To assist in maintaining the horizontal position of the limb, the operator should grasp the bone just above the point of division. Any sharp spicules of bone left should be removed by a pair of cutting pliers applied with the flat side against the portion of the bone remaining. It is very useful also in some cases,—as in the tibia,—where the bone is subcutaneous and a sharp edge would

otherwise be left beneath the skin flap, to saw the projecting portion off obliquely so as to round off the cut end (see Fig. 73).

**Securing the vessels.**—When the limb has been removed, the flaps are drawn down in position to see roughly if they are of sufficient length, and if this inspection be satisfactory the surgeon proceeds at once to pick up the main vessels. The larger of these are of course readily recognized both by their anatomical situation and by their appearance. The large veins should be picked up and ligatured as well as the arteries. The best material for ligature is catgut sufficiently strong to allow the knot to be firmly tightened, but not too coarse. After the main vessels have been tied, the surgeon may clamp a few of the others before the tourniquet is removed. The larger of these are usually found amongst the muscles, and their situation can often be determined by squeezing the latter and thus causing a drop of blood to exude from the cut end of the vessel. When this has been done, an assistant should be told off to compress the main artery of the limb whilst the tourniquet is removed, and it is a good plan to fold one of the flaps firmly over a large hot

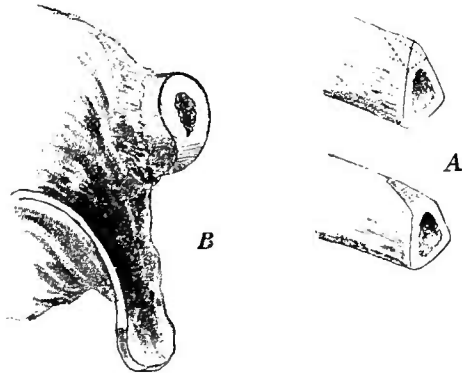


FIG. 73.—METHODS OF ROUNDING OFF THE END OF THE BONE IN AMPUTATIONS. *A* shows the direction of the saw-cut and the appearance of the bone-end after the sharp tibial crest has been sawn off. *B* shows the result after treating the linea aspera of the femur in a similar manner.

sponge so as to stop the oozing in it whilst the bleeding points are being picked up in the other flap. Should it be found that there are several largish vessels bleeding, the assistant can readily compress the main vessel from time to time, and by proceeding in this way very little blood indeed need be lost. While the vessels are being picked up, the limb should be raised into the vertical position. It is well to tie all the clamped vessels with fine catgut. No doubt many of them would stop oozing after having been clamped for a little while, but on the whole considerable time is saved by tying them all and there is less risk of the flaps subsequently becoming separated by blood-clot. After the vessels have been tied, the main nerves should be identified, seized with forceps, pulled down and cut short, and the same may be done with any tendons present in the stump.

**Stitching up the flaps.**—After the bleeding has been arrested, the

flaps are brought into position and stitched up by a continuous silk suture. The easiest method of ensuring that the flaps shall be stitched up accurately is to introduce one or two interrupted sutures before employing the continuous one, as they serve to keep the flaps temporarily in position. One of these may be introduced through the centre of the flaps and one on either side.

**Drainage.**—It is well in all cases to employ a drainage tube, which should be kept in for four or five days; otherwise the stump is apt to fill with blood, which is chiefly due to the oozing following the application of the tourniquet. This may cause delay in healing from the accumulation of serum within the flap or, when the skin is thin and somewhat wanting in vitality, even sloughing of the flaps may occur from the pressure exerted by the blood distending them. A drainage tube is all the more necessary because it must be remembered that it is impossible in amputation wounds to apply sufficient pressure to stop capillary oozing, because of the danger of sloughing of the flaps from the pressure thus applied. The drainage tube should be of good size—generally about No. 16—and should be introduced at one of the angles of the wound, the one chosen being the angle furthest away from any possible source of septic infection,—a point of great importance in amputation in the upper third of the thigh or through the hip joint. It is advisable of course that the point chosen should also be the most dependent one, but where this would bring the tube too near to some source of infection it must be abandoned in favour of the one furthest away from this; for after all the dependent position of the opening is a matter of comparatively slight consequence.

**Dressings.**—The ordinary cyanide gauze dressings should be applied, and care must be taken to have a sufficiently large amount, because otherwise the dressing is apt to slip off owing to the movements of the patient. It is not uncommon for the stump to jerk about very freely after amputation, and this may loosen and detach the dressing to such an extent that if only a small quantity be put on the wound, the stump may be found next morning without any dressing at all. In order to obviate this jerking of the stump, a splint should always be applied.

**Splint.**—The simplest form of splint for amputations of the lower extremity is a trough of Gooch's splinting, which is made to encircle rather more than half the circumference of the limb. The splint is covered first of all with a piece of mackintosh or jaconet upon which is laid a large mass of salicylic wool. The stump is then placed upon the splint, and suitable padding is applied so as to afford it equal support in all directions; the bandage which fixes the splint must be applied from the extremity upwards, and special care must be taken to see that the upper turns of the bandage do not exert any constriction upon the limb; if they do, the venous return will be interfered with and increased oozing will ensue. When the amputation is through the thigh, the bandages fixing both the dressings and the splint must always be carried up around the pelvis, as otherwise they will slip off. After the splint has been applied, the limb should be

raised upon an inclined plane or on pillows. The latter generally suffice in amputation through the leg, and the limb may be fastened to the pillows by means of bandages. In the thigh it is well to use an inclined plane of wood, and to fasten the splint to this by strips of bandage. This inclined plane should be so planned that it can be weighted either by a heavy sandbag or by leaden weights, so as to prevent it from being affected by the jerking movements of the limb.

**After-treatment.**—The dressings should be changed on the day following the operation, as there is always a considerable amount of blood poured out during the first twenty-four hours. The frequency with which the dressings will require changing subsequently will depend upon the amount of discharge. The drainage tube can generally be left out about the fourth day, except when there has been free bleeding from the wound and considerable accumulation of blood-clot between the flaps; in these cases it should be retained for two or three days longer. Occasionally, however, particularly in drunkards, the blood poured out between the flaps does not coagulate properly and a considerable quantity of tarry blood may be squeezed out for several days after the operation; in these cases the drainage tube should not be discontinued until this has entirely ceased. The continuous suture can generally be removed at any time after the first fortnight, but in the more important amputations at any rate, it is well to leave the interrupted sutures referred to above (see p. 238) in position for a week or so longer so as to guard against any separation of the flaps from accidental damage.

**Support to the stump.**—When the wound has nearly healed, it is often necessary to employ some special method of bandaging the stump. In many cases no doubt this is not necessary, but it may be called for when the flaps have been cut a little too short and there is consequently considerable tension upon them. The bandage is applied here with the object of pushing down the muscles over the end of the bone and preventing the retraction of the flap, and therefore the stump must be bandaged from above downwards. A special stump bandage is also called for when a large, heavy posterior flap has been turned forwards, which if unsupported would tend to drag the scar backwards over the end of the bone; a typical example of this is seen in Syme's amputation.

*Gauze and collodion bandage.*—Before applying this bandage, considerable support may be given to the flaps by applying the gauze and collodion arrangement shown in Fig. 74. A piece of dry gauze, one or two layers thick and about the width of the transverse diameter of the limb, is fastened by collodion to the skin for a considerable distance above the divided end of the bone. When the collodion is dry, an assistant, grasping the limb above, pushes the tissues well down over the bone, and the free end of the gauze is then pulled upon and folded down over the end of the stump and fastened to the posterior surface of the limb by more collodion, the soft parts being held in position until the collodion is quite dry.

*Bandaging the stump.*—Outside this a bandage may be applied to reinforce

the action of the gauze. The bandage should be wetted, partly because it adheres better when wet, and partly because it shrinks as it dries and thus obtains a firmer hold upon the limb. An assistant should push the soft parts down over the end of the bone, and the bandage is commenced

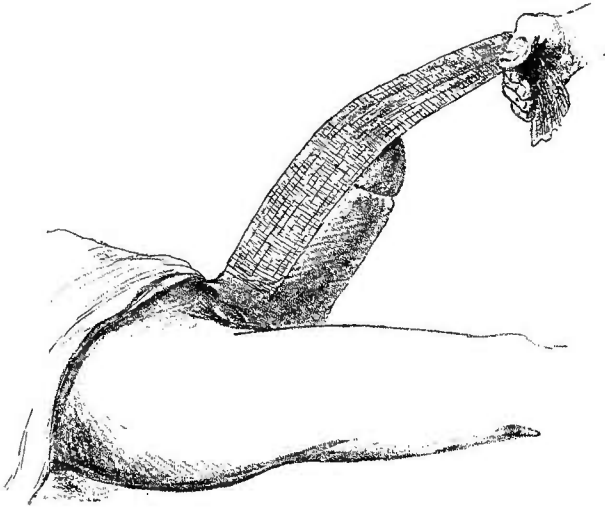


FIG. 74.—GAUZE AND COLLODION BANDAGE FOR AN AMPUTATION STUMP. When the collodion is dry, the soft parts are pushed well down, and the gauze is then folded down over the end of the stump, applied to the posterior surface of the thigh and secured with collodion to it, being held firm until the collodion is quite dry.

eight inches or more above the end of the stump, which it is made to encircle, and from this point, either by the figure of eight method or by reversing, it is made to compress the limb evenly from above downwards so as to push down and fix the skin and the muscles and thus to relieve the tension on the stump.

When the free end of the stump is reached the bandage is finished off as a typical *stump bandage*, applied as follows. The last circular turn is fixed by the thumb at the centre of the limb in front, and the bandage is then brought vertically downwards over the centre of the free end of the stump, and carried up to a corresponding point on the centre of the limb behind, where it is caught and fixed by the forefinger; from this point the bandage is again brought over the free end of the stump, slightly to the opposite side of the middle line, up to the thumb, beneath which it is again caught, and then a series of similar turns are carried backwards and forwards to alternate sides of the middle line, each turn overlapping its predecessor by about two-thirds of its width until the whole of the end of the stump is covered (see Fig. 75). Finally these vertical turns are caught and fastened beneath a few turns of the bandage carried circularly around the limb, which is then fastened off, leaving the whole stump well covered in and firmly supported.

In applying this stump bandage it is important to remember that the turns which pass over the end of the stump should always commence in the



direction of the longer flap, so as to stretch this as much as possible ; for example, if the anterior flap be the longer, the bandage should be carried from the anterior surface of the limb over the end of the bone and up on to the posterior surface ; should the long flap be the posterior one, the bandage should be commenced on the posterior surface. As we have already said it is necessary, when the amputation is through the thigh, to carry the upper part of the bandage around the pelvis in form of a spica, so as to prevent its slipping off the limb entirely.

When the case is one in which there is a long heavy posterior flap, as occurs for example in Syme's amputation, the chief object of a stump

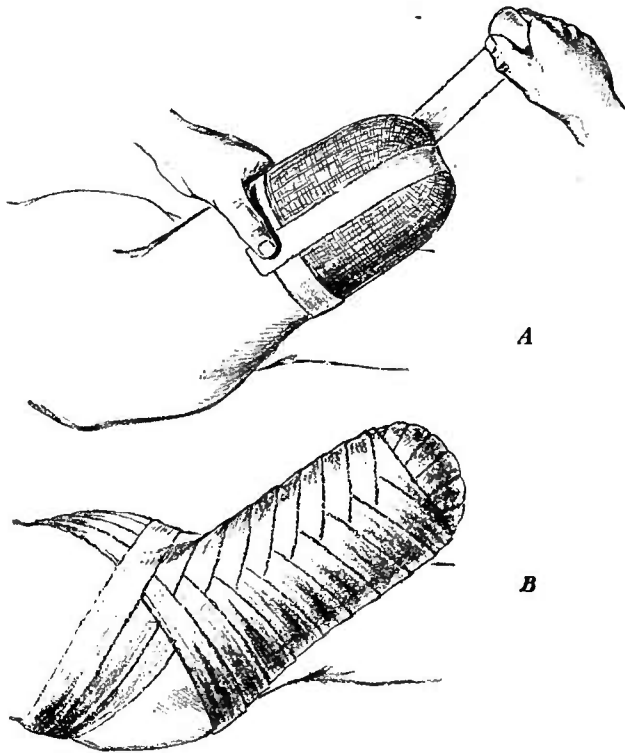


FIG. 75.—THE STUMP BANDAGE. In *A* is shown the method of commencing to cover in the end of the stump. The direction of the bandage is changed from circular to antero-posterior by placing the thumb upon it as shown above. The bandage is then carried over the end of the stump and up along its posterior surface, where it is caught beneath the forefinger and then brought back again, slightly to one side of the middle line, beneath the thumb once more. In *B* the bandage is shown completed and carried up as a spica around the pelvis.

bandage is to support the flap and push it well forwards ; this form of bandage must therefore be employed for some weeks after the amputation wound has healed, as otherwise the scar is apt to be pulled downwards over the end of the bone. In this case of course the bandage is commenced on the posterior aspect of the limb, carried downwards over

the flap and upwards on to the anterior surface, and then back again and so on. In Syme's amputation, it is well to apply, in addition, a pad of lint behind the posterior flap so as to still further push it forward. In all cases where it is necessary to support the stump by bandages or strapping in this manner, the limb should be put on the splint in such a position that the utmost possible relaxation of the long flap is obtained.

**When the amputation becomes septic.**—This accident may happen either from some error in the management of the case or as the result of an amputation carried out through the region of septic sinuses. The treatment will be that of a septic wound (see Part I., p. 185). The most important point is the establishment of free drainage of all recesses of the wound. When the septic condition has subsided and granulation is established, the chief attention will be directed to preventing the retraction of the flaps. This is best done by the gauze and collodion dressing just referred to, which may be put on next the skin; and also by the stump bandage which is applied outside the dressings in the manner just described. Here also special care has to be taken to keep the limb on the splint in such a position as to relax the long flap as much as possible until the wound has healed.

**Faulty stumps.**—Apart from the question of sepsis in amputation wounds, which of course very seldom occurs at the present day, a stump may be faulty from either of two conditions already referred to: namely, adhesion of the cicatrix to the end of the bone, with possibly the involvement of nerves in the scar, or from the formation of what is known as a conical stump.

**From adherent cicatrix.**—The condition of adherent cicatrix has already been referred to; it usually results from septic infection of the wound and subsequent healing by granulation, which is followed by adhesion of the flaps and the scar to the bone. It may however result, even after a perfectly aseptic operation, from faulty planning of the flaps.

Should the cicatrix become adherent to the bone, there is often very great pain on pressure. This may occur even although the larger nerves have been cut short as recommended above, and is then due to the implication in the cicatrix of the smaller nerve branches, which may become bulbous and give rise to excessive pain. Quite apart from the neuralgic condition of a stump in which the cicatrix is adherent, there is very apt to be persistent and often spreading ulceration in the scar, owing to the low vitality of the cicatricial tissue which readily breaks down upon the slightest pressure. This may leave an ulcer in which it is very difficult to obtain cicatrization. In stumps of this kind the nutrition of the entire end of the stump is apt to be very defective; it is cold and livid in colour, and is very liable to be affected by low forms of inflammation and obstinate ulceration.

**Treatment.**—In all these cases of adherent cicatrix the best plan is to re-amputate, and a far better result is obtained by performing an entirely

fresh amputation and fashioning new flaps than by simply opening up the wound and resecting a portion of the bone. If such a partial operation be done, the nerves are still left implicated in the cicatrix, and fresh adhesion between the latter and the bone is very apt to occur. Hence, in all cases, except possibly in those in which a re-amputation would involve the loss of a joint,—as for example when the first amputation has been performed in the upper third of the leg,—it is better to fashion fresh flaps which do not contain any cicatricial tissue. Where however an important joint, such as the knee-joint, may have to be sacrificed if fresh flaps are to be made, it may be worth while trying to see whether the removal of a portion of the bone after opening up the old cicatrix will suffice. If it does not, recourse can still be had to amputation above the joint.

**From conical stump.**—The so-called conical stump may result from three causes. In the first place the flaps may be so badly planned at the time of the operation that they can only be made to meet with difficulty over the end of the bone, the result being that, as the muscles waste, the skin becomes more and more tightly stretched over the end of the bone, and the stump therefore becomes conical. Secondly, the condition may result from excessive wasting and contraction of the muscles after an amputation in which the flaps have been accurately fashioned at the time of the operation; this generally occurs in very muscular subjects in whom healing by first intention has failed, the resulting suppuration and granulation leading to considerable wasting and contraction. Lastly, it not infrequently happens that in young subjects, in whom a perfectly successful amputation has been performed through bones in a condition of active growth, the stump gradually becomes more and more conical as time goes on; this condition appears to depend on want of proper relation between the development of the soft parts generally, and the growth of the bone; the latter structure growing out of all proportion to the former.

**Treatment.**—It is generally sufficient to open the wound, and to remove as much bone as may be necessary to make a satisfactory stump. When the conical condition is produced by excessive growth of the bone it may be necessary to have recourse to this more than once, for the stump may again become conical as growth goes on. Hence in operating on a case of conical stump for the first time it is well to excise what might at first sight appear to be an unnecessary amount of bone, with a view of obviating the necessity for a second operation for the same condition. The amount of bone removed must of course vary with the age of the patient: when he is approaching the period at which growth is complete it will not be necessary to remove as much as when he is young, and when the bone may therefore be expected to grow considerably.

## CHAPTER XVI.

### AMPUTATIONS IN THE UPPER EXTREMITY.

#### AMPUTATIONS OF THE FINGERS.

**General considerations.**—The chief point for consideration in amputating the fingers is whether it is advisable to save a phalanx or a portion of a phalanx, or whether the amputation should be performed at the metacarpophalangeal joint, and the finger thus entirely removed. As a matter of fact, in most of the fingers,—and particularly in the index and little fingers,—the retention of even a very small portion of a phalanx is of great value, provided always that the flexor and extensor tendons can be made to act upon it. Some surgeons consider it useless to save any portion of the phalanges when the amputation is done above the centre of the middle phalanx<sup>1</sup> because the tendons retract and their action upon the remaining portion of the finger is therefore lost. This view has been strengthened by the commonly recommended practice of stitching up the divided end of the tendon sheath, so as to prevent the passage of pus along it into the palm. There is however no necessity whatever to stitch up the tendon sheath, provided that the operation be done aseptically, and there is no objection to securing the end of the divided tendon either to the orifice of the sheath or to the periosteum in its vicinity, so as to enable it to act upon the portion of finger remaining.

**AMPUTATION OF THE TERMINAL PHALANX.**—When only the last phalanx is diseased there is no dispute as to the advisability of retaining the rest of the finger, since the insertions of the flexor and extensor tendons are not completely divided in the amputation, and the movement of the inter-phalangeal joint is therefore not interfered with.

**By a long palmar flap.**—The best method of amputating the terminal phalanx is by means of a long anterior flap; this is in fact the only plan by which sufficient skin can be obtained to cover the head of the second

<sup>1</sup> The terms *above* and *below* are used in the upper extremity in a sense synonymous with the adjectives *proximal* and *distal* respectively. Thus “above the centre of the middle phalanx” means “on the proximal side of the centre” etc.

phalanx. Further, the palmar flap is thick and contains the terminations of the sensory nerves, whilst the cicatrix lies upon the dorsal aspect of the finger and is out of the way of pressure.

In performing the operation the surgeon stands in front of the patient, while an assistant standing on one side grasps the other fingers, flexes them and pulls them away from the affected member, so as to leave the finger to be operated on as free as possible. The surgeon takes the tip of the finger in his left hand, with the thumb upon the nail and the fore-finger beneath the pulp, and flexes the last joint to about a right angle.

Then, with a straight, narrow bistoury about two inches in length, a transverse incision is made across the dorsal aspect of the head of the second

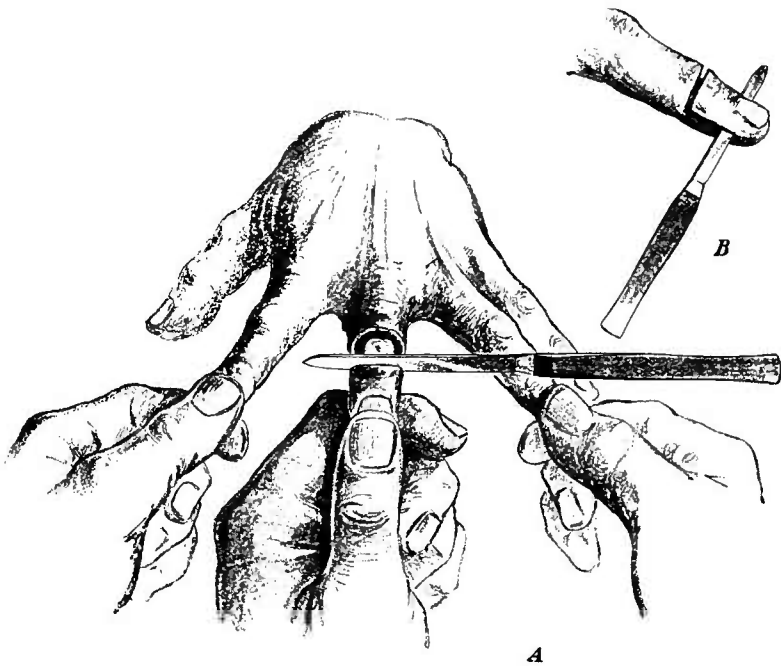


FIG. 76.—AMPUTATION OF THE TERMINAL PHALANX OF A FINGER. *A* shows the position of the limb when the transverse posterior incision is made. The next stage is shown in *B* where the palmar flap is being fashioned. The blade of the bistoury is unduly long.

phalanx, about an eighth of an inch below the level of the lowermost crease upon the palmar surface of the finger; this incision divides everything down to the head of the second phalanx, and the lateral ligaments are easily divided by a touch of the knife (see Fig. 76, *A*). The joint is then still further flexed and the phalanx pulled somewhat forwards, while the knife is gradually insinuated around the base of the terminal phalanx and then made to fashion a long palmar flap by keeping the blade parallel to, and in close contact with the anterior surface of the bone as the knife is carried

down towards the tip of the finger. When the flap is of sufficient length, the cutting edge of the knife is turned at right angles to the skin which is then divided (see Fig. 76, *B*). Very few vessels require ligature, generally none at all, as only the terminations of the digital arteries are divided.

In this way a long rectangular palmar flap is made which can be turned up over the head of the second phalanx and united to the skin on the dorsum. A mistake often made is to cut the flap of a pointed or triangular shape, either from carelessness in not making the knife follow the anterior aspect of the bone closely, or from continuing the knife in the horizontal direction until it cuts its way out, instead of turning it at right angles to the skin when finishing off the flap. In order to cut the flap satisfactorily it is necessary to have a knife with a narrow blade which is of equal breadth throughout,—in other words, a bistoury and not a scalpel.

The situation of the inter-phalangeal joint can almost always be determined by the guide given above; if not, it may be remembered that the line of the joint is a little below the prominence formed by the head of the second phalanx when the joint is fully flexed. Should the surgeon not happen to have a suitable narrow bistoury at hand, he can first of all cut the palmar flap from without inwards, and then proceed with the rest of the amputation as described above.

In aseptic cases, where there is no disorganisation of the joint, it is unnecessary to do anything to the head of the second phalanx; its cartilage may be left behind and gives no trouble. When, however, the operation is performed for septic affections, such as whitlow, or when there has been a bad crush or lacerated wound of the tip of the finger, the articular cartilage should be removed from the head of the second phalanx as it would otherwise be almost certain to necrose; it is well also under these circumstances to sponge over the surface of the wound with undiluted carbolic acid so as to destroy any organisms which may have gained access to it. In these cases it is well to introduce a fine drainage tube at one angle of the flap for two or three days after the operation; in other cases no drainage is required.

*After-treatment.*—The usual antiseptic dressings are applied and an anterior splint which extends into the palm should be put on; the one made of block-tin and used for fracture of the fingers (see p. 102) is as good as any. When the wound is aseptic, the dressing need not be changed for about ten days; healing will then be complete and the stitches may be taken out. When the wound is septic, the after-treatment will be that already described for a septic wound (see Part I., p. 186). In these cases the splint must be carefully re-applied until the wound has soundly healed, as otherwise the flap is very likely to fall forward and to leave the head of the middle phalanx exposed.

**AMPUTATION THROUGH THE SECOND PHALANX.**—The operation just described is also applicable to amputations through the middle phalanx, the palmar flap being cut from without inwards and the bone being divided by a fine saw or a pair of cutting pliers. When the

amputation is done above the middle of the phalanx a long posterior flap with a short anterior one will usually give a better result. It is in amputations above the middle of the second phalanx that the stump left is likely to be useless unless special care be taken to preserve the action of the tendons,—especially the flexors,—upon it.

**Fixation of tendons to the stump.**—After the amputation has been completed, the flexor tendons should be stitched to the cut end of the sheath, or failing that, to the periosteum; in order to facilitate this, care should be taken to divide the flexor tendons on a somewhat lower level than that of the bone section. They can as a general rule be secured by catch forceps before they are divided; should they escape and retract up their sheath, they can be protruded by flexing all the fingers and squeezing the palm downwards. They should be stitched with fine catgut either to the edge of the sheath or to the periosteum on the front of the bone. The tendons thus acquire an intimate connection with the bone, and flexion of the stump of the finger is preserved. It is as a rule not so easy to stitch the extensor tendon in a similar manner, but in order to get the best possible result it is well to do so.

**AMPUTATION THROUGH THE FIRST PHALANX.**—If the tendons be sutured in this manner, even a small portion of the first phalanx may be retained with advantage to the patient. Certainly when the entire phalanx can be saved, this should be done, instead of sacrificing it by amputating at the metacarpo-phalangeal articulation as used to be recommended. In the index and little fingers it is of great importance to save even the smallest portion of the first phalanx.

**AMPUTATION AT THE METACARPO-PHALANGEAL JOINT.**

—This operation is more frequently performed than is amputation through the finger itself, and is required for severe cases of whitlow, for bad crushes of the finger and particularly for tuberculous disease either in the form of strumous dactylitis or tuberculous joint mischief.

**Importance of retaining the metacarpal bone.**—In amputating in this situation it is always well, if the circumstances of the case permit, to avoid interfering with the head of the metacarpal bone. It is true that the removal of a finger, particularly if it be the ring or middle finger, leaves a somewhat unsightly gap in the hand, but nevertheless the limb thus left is much more useful than when the head of the metacarpal is removed. At the same time the latter procedure no doubt gives a better appearance to the hand and leaves little trace of the operation, but the power of the grasp and the general utility of the hand are considerably diminished. Certainly in men, and particularly in those who have to earn their living by manual labour, the metacarpal bone even of the index or the little finger should be left untouched. In those however who are not so situated and to whom the sightliness of the hand is of more importance than its strength, the head of the metacarpal bone may be removed, so as to avoid attracting attention to the gap between the fingers.

**The racket-shaped incision.**—Various operations are described for removal of the fingers, but the best for general use, particularly for amputations of the middle and ring fingers, is by means of the racket-shaped incision. The hand should be pronated, the other fingers bent and kept out of the way by an assistant, while the surgeon seizes the finger to be removed, flexes it at the metacarpo-phalangeal joint through about half a right angle and, entering the point of the knife just above the knuckle, carries the incision directly downwards over the dorsal aspect of the phalanx

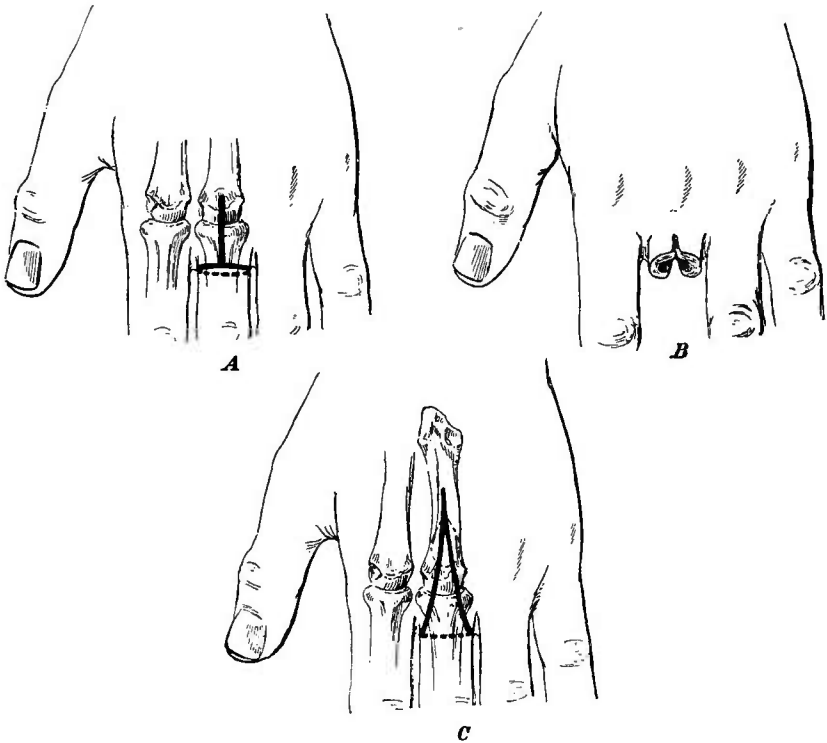


FIG. 77.—AMPUTATIONS OF THE FINGERS.

- A.* The ordinary racket-shaped incision for amputation at the metacarpo-phalangeal joint.  
*B.* The same amputation, but with a notch made in front to improve the appearance.  
*C.* Incision for removal of a finger along with the head of its corresponding metacarpal bone. The oblique section through the latter is shown by the thin dotted line.

to a point opposite the centre of the web of the finger. From this point the incision passes forwards and very slightly downwards to the edge of the web. It then runs transversely across the front of the finger on a level with the crease on its palmar surface as far as the web on the opposite side, whence it is carried upwards to join the vertical incision from which it started (see Fig. 77, *A*). This incision should go down to the bone all round. The finger is then fully extended and the flaps are dissected up. If the tendons have escaped division in the first incision, they are put upon



the stretch and divided. The base of the phalanx is cleared by two or three sweeps of the knife and the metacarpo-phalangeal joint is reached and opened from the palmar surface. This is best done by hyper-extending the finger and putting the anterior ligament upon the stretch; it can then be nicked with the point of the knife, the lateral ligaments divided in a similar way and the finger removed. The only vessels requiring ligature are the digital branches of the palmar arch which will be found on either side of the head of the metacarpal bone slightly towards its anterior aspect and close to the bone. The flaps should come into perfect apposition on approximating the fingers, and should form a good covering for the head of the metacarpal.

In most cases the incision should run transversely across the palmar aspect of the finger as we have just described, and should not extend at all upwards into the palm. Sometimes, however, particularly in labouring men in whom the skin of the palm is very thick, an unsightly projection of skin may be left at the palmar end of the incision when the flaps are brought together. This can be readily removed by taking out a **V**-shaped portion there, when the projection will disappear (see Fig. 77, *B*). This should be done after the amputation has been completed rather than by carrying the original incision up into the palm; the surgeon is better able to see exactly how much skin can be taken away after the finger has been removed.

Unless the case be septic, a drainage tube is quite unnecessary. The cartilage over the head of the bone may also be left, and there is no necessity for any interference with the tendons or the tendon sheaths. Should the case be septic however, the cartilage should be removed, the tendon sheath sewn up with fine catgut and the wound sponged over with undiluted carbolic acid.

*After-treatment.*—The usual antiseptic dressings are applied, and the hand is placed upon an anterior splint extending some distance up the fore-arm, so as to fix the wrist joint. The fingers next the seat of amputation on either side should be fastened together by strips of gauze so as to avoid all tension upon the stitches. In a week or ten days the wound should be healed, when the stitches may be removed and the splint discarded.

#### **REMOVAL OF THE HEAD OF THE METACARPAL BONE.**—

Should it be desired, for the sake of appearances or on account of disease, to remove the head of the metacarpal bone at the same time, this may be readily done by simply prolonging the vertical dorsal incision somewhat upwards. The head of the bone is then freed from the surrounding parts by a periosteum detacher and the point of the knife, and may be cut off by cutting pliers or by a special metacarpal saw. The incision through the bone should be made obliquely from behind downwards and forwards (see Fig. 77, *C*).

#### **AMPUTATION OF THE INDEX AND LITTLE FINGERS.**

These amputations may be effected through very similar incisions. In

order to render the scar less noticeable the vertical incision, or handle of the racket, may be made upon the ulnar or radial sides of the metacarpal bones respectively (see Fig. 78, *A*).

When it is desirable to remove the head of the metacarpal bone as well as the finger, the line of section through the bone should be obliquely downwards and to the opposite side. It is then also well to slope off the angle of junction between the oval of the racket and the handle, and thus to convert the incision into a long oblique one, in preference to the typical racket-shaped incision (see Fig. 78, *B*). This gives a more slightly scar.

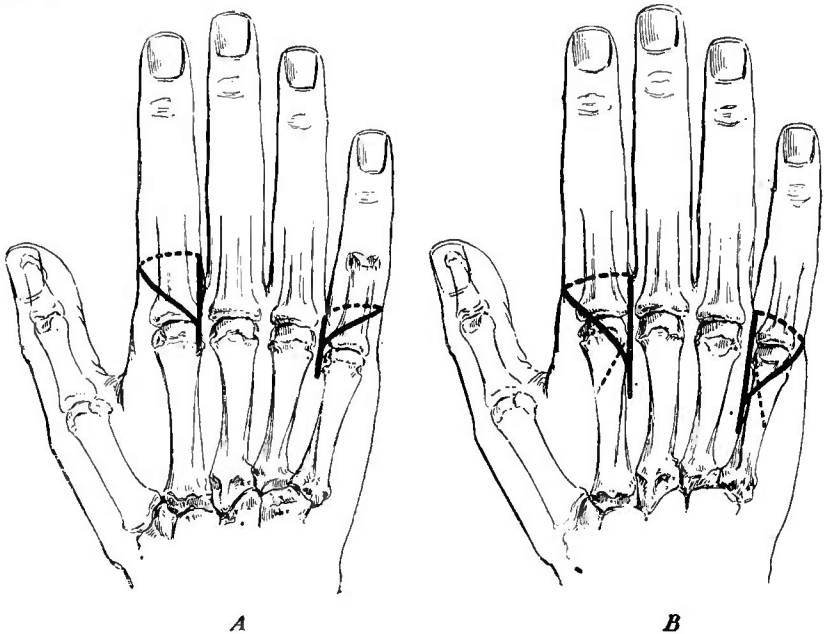


FIG. 78.—AMPUTATIONS OF THE INDEX AND LITTLE FINGERS.

*A.* Incisions for amputation at the metacarpophalangeal joints.

*B.* Incisions for similar amputations but accompanied by removal of the head of the metacarpal bone. The dotted line shows the line of section through the latter.

**AMPUTATION OF A METACARPAL BONE.**—It may sometimes be necessary to remove the metacarpal bone as well as the finger. This should be done if possible without opening the carpo-metacarpal articulation. Generally it will be sufficient to divide the bone just below its base, and this can be readily done by simply extending the vertical portion incision upwards. The sides of the bone can then be cleared and the shaft divided at the desired spot, when the anterior surface of the bone can easily be cleared by pulling it forcibly backwards.

As a rule however it is but seldom necessary to remove the metacarpal bone as well as the finger. When amputation of the metacarpal is called for it is done for some disease of the bone itself, such as tumour, tuberculous

osteo-myelitis and the like, and under these circumstances it is often possible to remove the metacarpal and to leave the finger intact. This will give in place of the metacarpal a firm cicatrix which is generally sufficient to give satisfactory support to the finger, the only alteration being that the latter is somewhat drawn up between the heads of the metacarpals on either side, so that there is apparent shortening.

The operation may be done through a dorsal incision extending the whole length of the metacarpal bone. It should commence well above the base and diverge a little to each side opposite the knuckle (see Fig. 79); the incision should only go through the skin, and the extensor tendon should be pulled aside and carefully preserved. If the amputation be done for any other affection than tumour or periosteal disease,

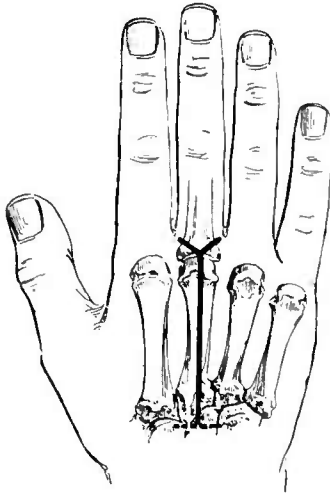


FIG. 79.—AMPUTATION OF A METACARPAL BONE ALONE. The diagram shows the best incision. The upper transverse dotted incision is not always required.

it is well to strip the periosteum off on either side and preserve it. The ligaments connecting the base of the metacarpal with the bases of the adjacent bones are then divided by a narrow-bladed knife inserted in the interosseous spaces with the edge upwards. The dorsal and the carpo-metacarpal ligaments are next put on the stretch and divided with the point of the knife. The head of the bone is separated from the metacarpals on either side, the metacarpo-phalangeal articulation is opened, and the head of the bone seized with strong forceps and pulled forcibly backwards. This will allow the structures to be separated from the anterior surface of the bone right back to its base. The anterior carpo-metacarpal ligaments are then divided by the point of a narrow-bladed knife, the bone being twisted first to one side and then to the other. By operating in this manner there is no risk of injuring the structures in the palm.

In cases of tumour of the metacarpal bone the operation is of course rendered more difficult by the presence of the growth, and it is well especially in cases of sarcoma, to take the neighbouring metacarpal on one or both sides so as to avoid a risk of leaving disease behind. This method of procedure is better, even in cases of tumour, than amputation of the hand. When more than one metacarpal bone is removed, however, it is well to take away at least one finger in order to preserve the full use of the hand. Unless this be done the fingers are apt to be crowded together as the wound contracts, and considerable interference with their usefulness may ensue.

The results of the operation are fairly satisfactory. This operation is one of the many new procedures which has resulted from the introduction of antiseptics; if it be done with full antiseptic precautions the patient runs no risk from the opening of the carpo-metacarpal articulation. Without them the operation would of course be quite unjustifiable on account of the almost certain occurrence of suppuration in the wrist joint and all its attendant evils.

**PARTIAL AMPUTATIONS OF THE HAND.**—Besides the operation just described there are many partial amputations which may be performed on the hand, for which it is almost impossible to give directions, as they may be varied widely to meet the circumstances of the different cases. The essential points to bear in mind are that even the smallest portion of a hand is of the greatest value to the patient, and its place can never be properly taken by any sort of artificial substitute; consequently no considerations such as opening joints, or tendon sheaths, or partial removals of bone should be allowed to stand in the way of operations of this kind, provided always that strict asepsis can be maintained, and provided that the case be not one of suppuration. The majority or the whole of the fingers may be removed, large portions of the metacarpal bones, and even of the carpus may be taken away, but, so long as the smallest portion of the bony structures of the hand or wrist can be left behind, this should be done. Of course the flaps to cover the bone remaining must be fashioned according to the circumstances of the case; wherever possible they should be taken mainly from the palmar aspect, as those structures are more vascular than those on the dorsum, and are therefore less likely to slough. Moreover the long flexor tendons can then be retained in the flap, and will help to increase the usefulness of the wrist very considerably. It should always be remembered that the flexor tendons in these partial amputations should be seized when the flap is raised, cut as long as possible and stitched to the end of the stump in order to retain the power of flexion; if this be omitted, the object of the operation will be largely defeated, as the tendons will retract up their sheath and movement may be almost entirely lost, even though a considerable portion of the bony structures of the hand be left. The same remark applies in a lesser degree to the extensor tendons.

**AMPUTATION OF THE THUMB.**—The operations for amputation of the thumb are practically the same as those for removal of the fingers, but the larger size of the bones of the thumb must be remembered and proportionately longer and larger flaps must be cut. What has been said as to the importance of leaving portions of the fingers behind applies still more strongly to the case of the thumb; every additional inch or fraction of an inch that can be preserved is of immense value to the patient, and in practice the operations necessary for the removal of the thumb will nearly always be some form of partial amputation rather than the complete and typical operations described in the text-books.

The *terminal phalanx* of the thumb may be removed in a manner exactly similar to that described for removal of the tip of the finger (see Fig. 80, *A*).

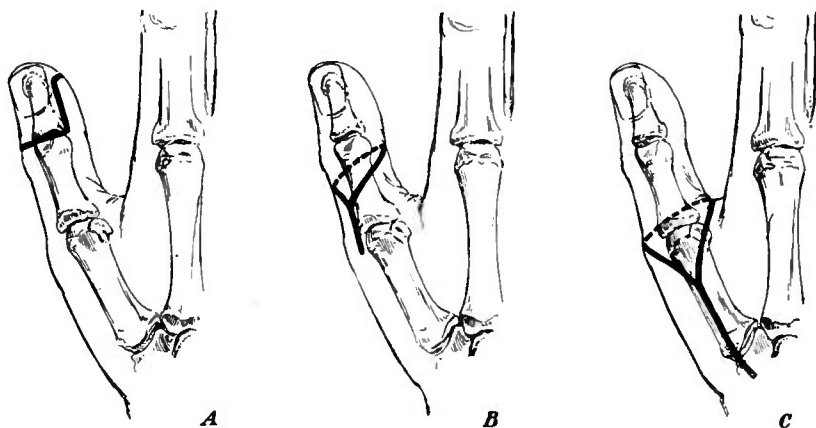


FIG. 80.—AMPUTATIONS OF THE THUMB.

*A.* Incisions for amputation of the terminal phalanx.

*B.* Incision for amputation at the metacarpo-phalangeal joint.

*C.* Incision for removal of the thumb along with its metacarpal bone.

*Amputation at the metacarpo-phalangeal joint* is best done by a racket-shaped incision which must be carried well down beyond the head of the metacarpal so as to insure plenty of covering for the large head of the bone. In order to avoid pressure on the scar and also to avoid damage to the tendons, it is well to carry the handle of the racket upwards on the outer or radial side of the thumb rather than over the dorsal surface; the oval part of the racket should reach as far down as the middle of the first phalanx (see Fig. 80, *B*). The scar is thus made to lie to the outer side and is therefore more out of the way of pressure than if the incision were made in a position similar to that for amputating the fingers. In this amputation care must be taken to attach the tendons to the end of the stump (see p. 247).

When the *first metacarpal bone* is to be removed, it is important to preserve the short muscles of the thenar eminence intact, as they form a fleshy pad which will be of considerable use in aiding the grasp of the hand after

removal of the bone. The best incision for this purpose is a racket-shaped one, commencing just above the articulation of the bone with the trapezium and carried down on the dorsal surface to a point short of the head of the metacarpal, and then diverging laterally to the web (see Fig. 80, *C*). The parts are dissected off the bone on either side, the metacarpal bone removed and the large thenar pad of muscles is left uninjured. This procedure is of course not always possible, because the disease or the injury may affect the structures higher up or may involve the thenar pad itself, but the principle should be borne in mind and applied wherever possible. In disarticulating the metacarpal bone from the trapezium, the articulation is best opened from behind, the thumb being bent downwards into the palm, and the ligaments rendered tense and divided by the point of the knife. The internal lateral ligament may next be divided, great care being taken to keep the knife close to the metacarpal bone. After that the external lateral ligament can be cut through, and then, by twisting the bone round, the anterior ligaments can be got at and divided without any trouble; the bleeding is comparatively slight. The radial artery does not require ligature and in fact should not be seen; only some of its digital branches near the end of the flap require ligature.

#### AMPUTATION AT THE WRIST JOINT.

This is an amputation which can be very rarely called for; it is generally limited to bad crushes of the hand, and to some cases of malignant disease. In tuberculous disease of the wrist joint amputation, when required, has to be performed through the bones of the fore-arm.

Amputation through the wrist joint gives a very useful stump, because the fore-arm retains its power of pronation and supination, while the expanded lower ends of the bones of the fore-arm give a fair point of fixation for an artificial hand. The operation should therefore be done wherever it is practicable.

**General considerations.**—The shape of the flaps depends upon the amount of skin obtainable. The best flap is obtained from the palm, but this is not always available; in many cases the best result is obtained by means of the modified circular method with equal dorsal and palmar flaps. In some cases the tissues in the palm may be entirely destroyed and a single dorsal flap may have to be employed. No portion of the bones of the fore-arm should ever be removed unless it is absolutely necessary; even the styloid processes of the radius and ulnar should be preserved. Above all things it is necessary not to interfere with the radio-ulnar articulation.

**Modified circular method.**—In doing the modified circular operation comparatively short flaps will suffice, but these must extend a little lower upon the radial than upon the ulnar side so as to compensate for the lower position of the styloid process of the radius. The following are the steps of the amputation which will most usually be performed under

the circumstances in which this operation is called for. The fore-arm should be held horizontally at right angles to the trunk in a position of full supination; both flaps should be cut from without inwards, and the palmar flap should be dissected up first. It facilitates the operation to detach the pisiform bone and raise it with the palmar flap; it can easily be dissected out afterwards. An incision is made commencing at the tip of one styloid process and carried obliquely downwards along that border of the hand for about an inch. It is then carried across the back of the hand to a point an inch below the opposite styloid process and thence runs obliquely upwards to the tip of that structure. A similar incision is then carried across the front of the wrist; this should extend slightly further down the palm than the one on the dorsum (see

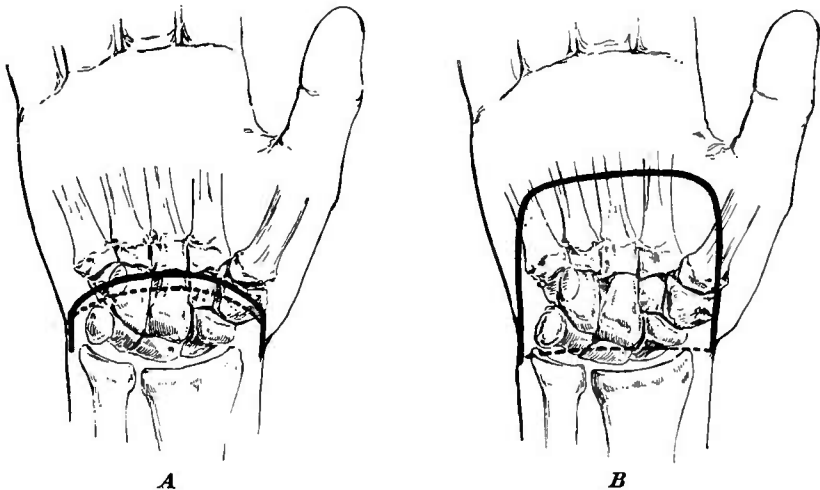


FIG. 81.—AMPUTATIONS THROUGH THE WRIST JOINT.

*A.* The modified circular method.

*B.* Amputation by a long palmar flap.

The thick lines show the palmar, the dotted ones the dorsal incisions.

Fig. 81, *A*). The flaps are dissected up, the hand is disarticulated, and, when the edges of the wound are sutured together, the incision lies over the lower end of the bones.

**By a long palmar flap.**—When the tissues in the palm are intact, a longer palmar flap can be made, and then little or no dorsal flap will be required. In cutting this long palmar flap however it must be remembered that it should be broad and not pointed; the incision should commence on the outer aspect of the styloid process of the radius and should run downwards along the outer side of the thumb to a little above the transverse crease of the wrist; it should then be carried transversely across the palm to a corresponding point on the opposite side, and then along the ulnar border of the hand to the tip of the styloid process of the ulna (see Fig. 81, *B*). The structures are divided down to the bone,

and all the soft parts are turned up from the front of the carpus. The two upper extremities of the palmar flap are then joined across the back of the wrist by a slightly curved incision with its convexity downwards. This gives a short skin flap which is raised and turned back, and the ligaments of the wrist joint are then divided and the wrist and hand removed. The palmar flap when turned up forms a fleshy and sensitive pad covering the ends of the bones of the fore-arm.

A drainage tube is generally required for the cases in which a long anterior flap has been made; as a rule it is not called for in the modified circular form. The limb should be placed upon an internal rectangular splint with the fore-arm in a position midway between pronation and supination. The splint will require careful padding to keep the stump free from pressure, and after a fortnight the wound will be found healed and the splints and dressings may be left off.

#### AMPUTATION THROUGH THE FORE-ARM.

This is the form of amputation that is perhaps most commonly required for tuberculous disease of the wrist joint. In this affection it may sometimes be possible to save more of the arm by amputating through the joint itself and then sawing off or gouging out the surfaces of the radio-ulnar articulation; but as a rule it is advisable to divide the bones above the joint.

**Modified circular method.**—In the fore-arm the best amputation is the modified circular form with equal anterior and posterior flaps. The scar lies directly over the end of the bones, which is the point of least pressure, because the pressure exerted by an artificial limb upon the stump must necessarily fall either upon its anterior or its posterior aspect and not upon the end of it, as is the case in the lower extremity. A further advantage of this modified circular operation is that the bones may be divided on a lower level than by any other operation; the flaps being antero-posterior and of equal length seldom have to be more than an inch or an inch and a half long, and thus the amputation can be performed close to the seat of disease and yet a sufficient covering for the bones can be obtained. This gives the patient the longest possible stump—a point of great importance in the adaptation of an artificial limb. In some cases of injury it may be possible by employing either a long anterior or a long posterior flap or irregular flaps, to divide the bone on a lower level than would be necessary for equal antero-posterior flaps. If this be the case the latter method should be abandoned in order to secure a longer stump. Every inch that can be saved is of the greatest value.

The modified circular amputation has already been described (see p. 225). The limb should be abducted and fully supinated and the surgeon, standing to the patient's right of the limb, marks the proposed point of division of the bones by placing the forefinger and thumb of his left hand upon them, one on either side of the limb. The knife is then entered about half an inch be-



low one of these points and is made to trace a short anterior flap terminating at a corresponding point on the opposite side. When this is done, a similar posterior flap is marked out (see Fig. 82). The two flaps combined should be equal to slightly more than the diameter of the limb at the point at which the bones are to be divided, the additional length being required to allow for shrinking of the flap from retraction of the muscles. These latter are divided by a series of circular sweeps, the periosteum divided on the same level as the muscles and peeled up by a raspatory to the point at which the saw is to be applied (see p. 227). In sawing the bones care must be taken to avoid splintering, and they should therefore be held quite horizontal and the saw made to cut each bone to the same depth. When the division is nearly complete, however, the section of the radius should be finished off first as it is the more moveable bone and the ulnar can be better steadied. The vessels requiring ligature are the radial, the ulnar, and the interosseous arteries, of which only the latter are at all difficult to secure; they lie close upon the interosseous membrane and retract when they are cut.

After the vessels have been secured, the tube of periosteum is pulled down over the ends of the bones and the wound is stitched up, a small drainage tube being inserted at one angle. The object of peeling up the periosteum is to guard against a fusion of the cut ends of the bones; this would involve loss of pronation and supination.

The arm is placed upon an internal rectangular splint with the fore-arm midway between pronation and supination. After about ten days the wound should have healed, the stitches may be taken out and the splint left off. In all cases the limb should be put up in the above position, so that, should fusion of the ends of the bones occur, the limb is in the most advantageous position for the application of an artificial extremity.

#### AMPUTATION THROUGH THE ELBOW JOINT.

This is not nearly so frequently done as is amputation above or below the articulation; chiefly because the large size of the lower end of the humerus necessitates comparatively long flaps, and therefore the operation can only be done when the soft parts at the disposal of the surgeon are comparatively abundant. It should however be performed wherever possible, as of course the increased length of the stump is of advantage, and the expanded end of the bone gives a better point of support for an artificial limb. The operation is usually done for a tumour affecting one

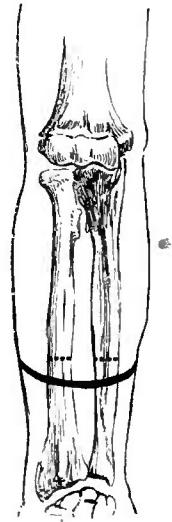


FIG. 82.—MODIFIED CIRCULAR AMPUTATION THROUGH THE FORE-ARM. The flaps are antero-posterior and of equal length. The dotted line marks the point of section of the bones.

or both of the bones of the fore-arm and sometimes for crushes of the latter; it can be but rarely performed for elbow-joint disease.

In many cases it is found necessary to make irregular flaps, but wherever it is possible, it is best to make a long antero-internal and a short postero-external flap. It is important in providing a covering for the lower end of the humerus to bear in mind the large size and irregular shape of the bone, and also the exact position of the elbow joint. It is hardly necessary to remark that the line of the latter does not correspond to the tip of the olecranon. The best guide is the head of the radius, the position of which is easily found by placing the thumb immediately beneath the external condyle and pronating and supinating the fore-arm. The upper limit of the radial head usually lies about half an inch below the most prominent part of the condyle, and may be taken as a good guide to the line of the joint.

**By a large antero-internal flap.** An elastic bandage is placed around the upper third of the arm, the elbow is flexed to an angle of  $135^{\circ}$ ,

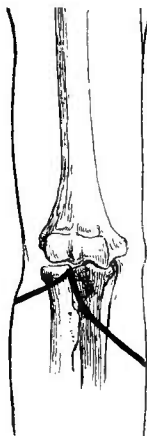

FIG. 83.—AMPUTATION THROUGH THE ELBOW JOINT BY A LONG INTERNAL FLAP. The incision for the large internal flap is carried up to a corresponding point behind the joint. The relative length of the flaps may be varied to suit the circumstances of the case.

and the antero-internal flap marked out. This commences at the centre of the bend of the elbow, and is carried down parallel with the long axis of the humerus for about three inches; with the arm at the angle above mentioned, the lower limit of the incision should meet the inner border of the fore-arm at about this point. The incision is then curved backwards and upwards to the base of the olecranon. After this flap has been marked out, a somewhat similar one is cut from the external surface, but this should only be about an inch in length (see Fig. 83).

When these flaps are retracted, the soft structures are taken up right down to the bone. Disarticulation is performed by forcibly flexing the elbow, cutting the triceps through at its attachment to the olecranon and then dividing first the lateral and then the anterior ligaments. It is recommended by some authors that the base of the olecranon should be sawn through and left *in situ* so as to preserve the attachment of the triceps; this however is not of any real advantage.

The large antero-internal flap will be found to fold completely over the lower end of the humerus, and to cover up the prominent internal condyle without any risk of exposure of that structure even should the flaps retract somewhat. The vessels requiring ligature are the brachial itself, which of course should be secured before the Esmarch's bandage is taken off, and a few smaller vessels, such as the terminations of the superior and inferior profunda arteries and some of the anastomotic branches about the joint. A drainage tube should be inserted at the upper angle of the flaps

behind, and the arm placed upon a trough of Gooch's splint, laid upon a pillow and treated in the usual manner.

Various other flaps may be employed to cover in the lower end of the humerus according to the circumstances of the case with which the surgeon has to deal. A large variety of operations have been described, such as amputation by a long anterior and a short posterior flap, by an external skin flap, by the circular method, and so on. It is probable that in the majority of cases the operation that we have described may not be feasible owing to the lack of sufficient soft parts, and in these the modified circular method will probably have to be adopted. The obliquity of the condyles must be remembered; the flaps must extend further downwards on the inner than on the outer side. For a description of the modified circular method see p. 225.

#### AMPUTATIONS THROUGH THE ARM.

Amputation in this situation may be required for extensive injuries to the fore-arm, for tumour, or for tuberculous or other disease of the elbow joint not suitable for excision. It is important to retain as much of the humerus as possible so as to give sufficient leverage for an artificial limb, and therefore the section of the bone must be made on as low a level as is consistent with the entire removal of the disease.

**Modified circular method.**—This is practically the operation of choice for amputation in the upper arm, since in it there is the least sacrifice of bone. The exact position of the flaps, whether antero-posterior, lateral or irregular, is not a matter of great consequence; probably antero-posterior ones are on the whole the best. The old operations by transfixion and the formation of long flaps necessitated the removal of an undue length of bone, and have therefore nothing whatever to recommend them. For a description of the modified circular method see p. 225.

In amputating through the upper arm the vessels requiring ligature are quite few. The brachial artery, its superior and inferior profunda branches, with possibly a few muscular twigs, are all that will give any trouble. When the amputation has to be done high up, it may be somewhat difficult to arrest the circulation through the limb preparatory to the operation. As a rule this is best done by placing a sufficiently firm pad in the axilla and applying over it a piece of stout indiarubber tubing in a figure-of-eight, around the axilla, crossing over the outer end of the clavicle, the two ends being finally tied beneath the other axilla. There may possibly be a tendency for the tubing thus applied to slip if it encroaches upon the field of operation, and the following is the best plan to avoid this. Two strips of sterilised bandage should be passed beneath the tubing opposite the front and back of the shoulder so as to form loops around it (see Fig. 84). After the tubing has been fastened in position, these two loops of bandage are entrusted to an assistant who pulls upon them and thus keeps them in position and prevents them from slipping down over the flaps when the bone

is divided. If no assistant be available the ends of the two bandages can be tied together over the root of the neck upon the opposite side.

On the whole, however, the simplest plan of controlling the circulation when the amputation is to be performed high up through the humerus by the modified circular method, is to deepen the incision and expose the brachial artery after the anterior flap has been cut, and then to divide it between two ligatures before proceeding further with the operation. Care must be taken not to damage the artery above the point of ligature in the subsequent steps of the operation.

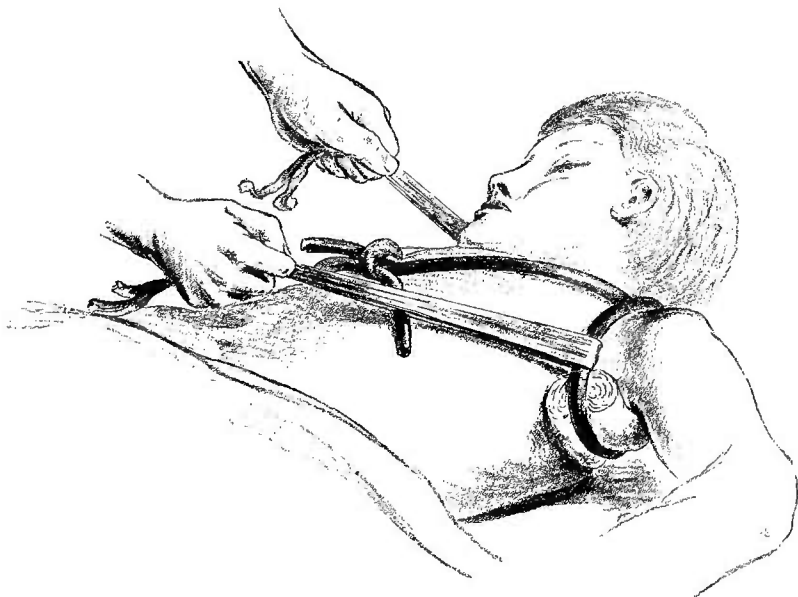


FIG. 84.—METHOD OF CONTROLLING HÆMORRHAGE IN AMPUTATIONS OF THE UPPER ARM. The rubber tubing is applied in a figure-of-eight around the shoulder, over a pad in the axilla (drawn too large in the figure), and is kept from slipping off when the bone is sawn by the slips of bandage passed beneath it front and back, and held as depicted above.

#### AMPUTATION AT THE SHOULDER JOINT.

A large variety of methods of amputating through the shoulder joint have been described from time to time, the most popular until recently being that by means of the deltoid flap. Here again, however, irregular operations of all kinds will be the most useful in actual practice, as the operation is usually called for in cases where it may be extremely difficult to obtain flaps by the orthodox methods. When a set operation is possible, probably the best and most satisfactory in its results is Spence's operation (see Fig. 85, *A*). Spence describes his operation as follows:

**Spence's operation.**—"Supposing the right arm to be the subject of amputation. The arm being slightly abducted and the head of the

humerus rotated outwards, with a broad straight bistoury, I cut down upon the inner aspect of the head of the humerus, immediately external to the coracoid process, and carry the incision down through the clavicular fibres of the deltoid and pectoralis major muscles till I reach the humeral attachment of the latter muscle which I divide. I then with a gentle curve carry my incision across and fairly through the lower fibres of the deltoid towards but not through the posterior border of the axilla. Unless the textures be much torn, I next mark out the line of the lower part of the inner section by carrying an incision through *the skin and fat only* from the point where my straight incision terminated across the inside of the arm to meet the incision at the outer part. This insures accuracy in the line of union, but is not essential. If the fibres of the deltoid have been thoroughly divided in the line of incision the flap so marked out

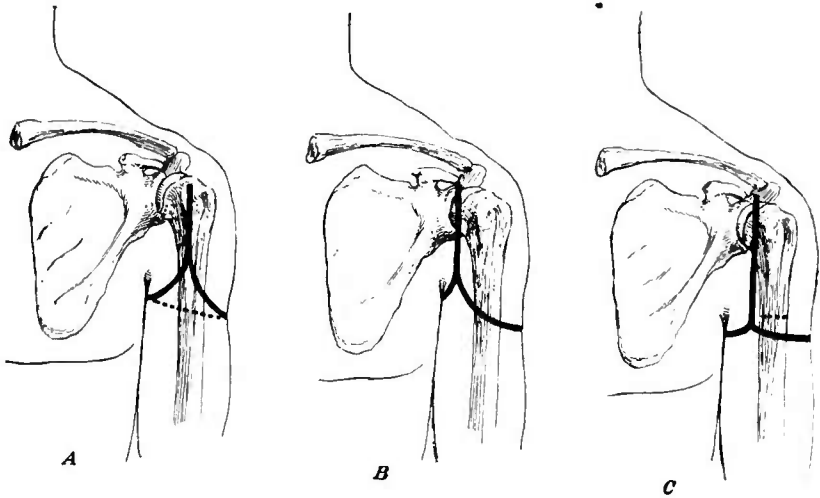


FIG. 85.—METHODS OF AMPUTATING AT THE SHOULDER JOINT.

A. Spence's amputation.

B. Amputation by a long deltoid flap. The incision for this flap is carried up to a corresponding point on the back of the shoulder.

C. Furneaux Jordan's method applied to the shoulder. The transverse incision is a circular amputation with the edges just rounded off where the vertical incision meets it. The dotted line denotes the point of section of the bone. The upper end of the latter is subsequently enucleated.

along with the posterior circumflex trunk which enters its deep surface can be easily separated from the bone and joint, and drawn upwards and backwards so as to expose the head and the tuberosities by the point of the finger without further use of the knife. The tendinous insertions of the capsular muscles, the long head of the biceps and the capsule are next divided by cutting directly on the tuberosities and head of the bone, and the broad sub-scapular tendon especially being very freely exposed by the incision, can be much more readily and completely divided than in the double-flap method. By keeping the edge of the posterior flap out of the way by a broad copper spatula or the fingers of an assistant,

and taking care to keep the edge of the knife close to the bone, as in excision, the trunk of the posterior circumflex is protected. The only vessel which bleeds is the anterior circumflex divided in the first incision, and if necessary a pair of catch forceps may be placed on it at once. With regard to the axillary vessels they can either be compressed by an assistant before completing the division of the soft parts on the axillary aspect, or to avoid all risk the axillary artery may be exposed, tied and divided between two ligatures so as to allow it to retract before dividing the other textures. In cases where the limb is very muscular I dissect up the skin flap from the deltoid at the lower part and then divide the muscular fibres higher up by a second incision, so as to avoid redundancy of muscular tissue. The advantages I claim for this plan are, first, the fulness and better form of the stump left after healing; second, the posterior circumflex artery is not divided except in its small terminal branches in front, whereas both in the large deltoid flap and the double methods the trunk of this vessel is divided in the early stages of the operation, and retracting often gives rise to embarrassing hæmorrhage. In the case of the deltoid single-flap method the vitality of the flap must be seriously compromised as it depends chiefly on that vessel for its arterial supply. Third, the great ease with which disarticulation can be accomplished."

The above operation will chiefly be called for in cases of tumour or disease of the upper end of the humerus, or for tuberculous disease of the shoulder joint itself; in the latter case the operation must of course be extended by removing the glenoid cavity, which can be cut away with bone pliers after the limb has been removed; in addition, all the synovial membrane must be carefully dissected out, as well as the bursa beneath the deltoid if that should happen to be affected.

**Operation by a deltoid flap.**—In cases of tumour occupying the head of the humerus, Spence's operation is not applicable, and in these either the deltoid flap method or some more irregular form of amputation based upon it will be the best (see Fig. 85, *B*).

*Means of controlling bleeding.*—It will be necessary here to take precautions to control the circulation before cutting the flaps. A variety of plans for this purpose have been proposed, that most commonly employed being either digital or instrumental compression of the subclavian artery as it crosses the first rib. In order to do this at all efficiently it is necessary to make an incision through the skin and deep fascia just over the clavicle as for ligature of the third part of the vessel, and through this to introduce the thumb or a special instrument called a 'key'<sup>1</sup> to compress the vessel. The objection to this method is that in the first place it is necessary to make a second wound; and in the second place the compression is apt to be very uncertain since, if a 'key' be used, the instrument is very liable to become displaced during the manipulations attendant upon the removal

This consists of a **L**-shaped piece of wood, the cross-piece being short and covered with indiarubber. The instrument should be sterilised by boiling before use.

of the limb, while, on the other hand, if an assistant be employed to make digital compression, he is very apt to become tired and to relax his pressure upon the artery. The safest plan in all cases is to secure and divide the artery in the axilla between two ligatures at the commencement of the operation. The incision for this purpose may often be so planned as to mark out one of the flaps.

*Incision.*—The operation is done by carrying an incision from the tip of the coracoid process downwards as far as the insertion of the deltoid, if the state of the tissues permits, or, if it does not, as far down as possible upon the outer side of the arm. From this point it is carried backwards and upwards to the root of the acromion. When this flap is dissected up it should consist for the first inch or two of skin, subcutaneous tissue and deep fascia; then, should the deltoid be free from disease, this may also be raised as the flap is further dissected up. It is generally easy to expose the axillary artery in the incision before proceeding to dissect up the flap: the vessel should be divided between two ligatures, the upper part being stripped up out of the way, so that it shall not run any risk of damage during the later stages of the operation.

*Disarticulation.*—After the deltoid flap has been raised, the two ends of the incision are united by another incision on the inner side of the arm which forms a flap of sufficient length with its convexity downwards. The length of this must of course vary with that of the deltoid flap. Where it is possible to cut the latter the full length the internal flap need only be extremely short. A longer one will be called for if from any cause the deltoid flap has to be made shorter than usual.

The deltoid flap is held well up and disarticulation is effected; the external rotator muscles are divided close to their insertion into the great tuberosity, the capsule is opened and the knife is slipped round the head of the bone and made to divide the tissues forming the deeper part of the internal flap.

*Removal of the joint entire.*—When the amputation is done for malignant disease of the upper end of the humerus, it is as well to remove the glenoid cavity and the whole of the capsule of the joint, lest the disease should have infected this structure; in these cases the division of the rotators should be effected not immediately over the tuberosities, as is done in excision, but at some little distance from the joint; then, if the condition of the parts permits, the neck of the glenoid cavity should be cleared without opening the capsule at all and should be snipped off with powerful cutting pliers or divided by a chisel, and the whole of the glenoid cavity with the capsule of the joint intact should be removed in one piece without opening the joint at all. In some cases of course the anatomical condition of the parts will prevent this.

**By lateral flaps.**—Another amputation recommended in this situation that requires mention is that by lateral flaps. The incisions for this operation commence just below and external to the tip of the coracoid process and curve downwards and to either side until they meet at a

corresponding point in the axilla. The flaps should be of equal length and should measure from 4 to 5 inches. It is quite easy to secure the axillary artery in the inner flap as the incision is being deepened, and thus no compression of the vessel is required.

**The Furneaux Jordan method.**—Another amputation which may sometimes be performed is similar to Furneaux Jordan's amputation at the hip joint. This may be applicable to cases of long-standing bone disease, especially extensive osteo-myelitis or necrosis. In it the arm is amputated by the circular method at about the level of the insertion of the deltoid, the flaps being made somewhat antero-external and postero-internal; an incision is then carried vertically upwards upon the inner side of the arm from the junction of the flaps towards the tip of the coracoid process. This incision is deepened down to the bone, the periosteum is peeled off and the upper extremity of the bone is extracted (see Fig. 85, *C*).

The merit of this operation is that a certain amount of new bone may form from the periosteum left behind; failing that, there will be a firm fibrous centre to the stump which should be of considerable value in giving support to an artificial limb. There is a possibility of subsequently laying open this bed of periosteum and inserting bone-grafts into it.

The cases however in which an operation of this kind can be done are extremely few nowadays as amputation for necrosis is of the greatest rarity; even should it be necessary to open up the whole length of the bone in order to remove the sequestrum, this is preferable to amputation. In acute necrosis moreover it is very questionable whether it is safe to leave the periosteum. Therefore, Spence's method is the best where it is practicable, and, failing it, the methods by the deltoid or lateral flaps are those that seem to offer the best prospects of success.

#### REMOVAL OF THE ENTIRE UPPER EXTREMITY.

**Indications.**—In some cases, although very rarely, it becomes necessary to remove the entire upper extremity, that is to say, the upper limb together with the scapula. The cases calling for this severe operation are essentially those of malignant disease of the upper end of the humerus where the scapula has become involved, or malignant disease of the scapula which has spread to the shoulder joint or the parts in the region of the shoulder to such an extent that it is impossible to leave the arm behind. The operation has also been done for extensive recurrence in the axilla and structures about the shoulder after cancer of the breast; but we are strongly of opinion that when breast cancer has advanced so far as to necessitate an operation of this kind the case is hopeless and operation does not offer the least prospect of prolonging life. There are several methods of doing the operation; that described by Berger or some modification of it is perhaps the best.

**Position.**—The patient should be drawn as far as possible to the



edge of the table, so that the shoulder on the affected side projects beyond its edge, and the thorax should be well raised by sandbags. The first step in the operation consists in dividing the clavicle and ligaturing the subclavian vessels.

**Preliminary incision for ligature of subclavian vessels.**—An incision is made along the upper border of the clavicle, commencing at the posterior edge of the sterno-mastoid, and terminating at the outer end of the bone. The incision is carried down to the bone and if the periosteum be healthy, it may be separated by a rugine; the bone is then carefully cleared below and divided at the junction of the two curves either with a saw or with cutting pliers. The outer end of the clavicle is seized and raised by lion forceps, whilst the periosteum and tissues beneath it are stripped off. The outer end of the bone can then either be disarticulated from the scapula—which is probably the best plan—or it may be snipped across with cutting pliers just short of the articulation.

This exposes the axillary vessels and the brachial plexus, which are only covered by the subclavius muscle, several layers of the fascia, and the periosteum of the clavicle. These structures are divided and separated until the artery and vein are seen lying over the first rib. Both vessels are then tied separately in two places and divided between the ligatures. It is well to ligature and divide the artery before the vein is similarly treated, as by doing so the blood in the limb may be to some extent preserved if the extremity be raised after division of the artery so as to allow the blood to flow back through the vein. This has the additional advantage that the vein will then cease to be distended with blood and will therefore be smaller, more easily manipulated, and not so likely to get torn. However in some cases the vein may be very large and may overlap the artery to such an extent that it may be necessary to tie it first.

The divided ends of both vessels are separated upwards and downwards by the handle of the knife, and then the various portions of the brachial plexus should also be divided and the lower ends stripped downwards. Before completing this stage of the operation it is well to insert the handle of the knife or the finger beneath the deep fascia of the neck and to separate the tissues to a moderate extent, lifting them up and searching for and if possible ligaturing the supra-scapular and the posterior scapular arteries: the former is usually readily found and can be ligatured at once: the latter may also be identified, but it is not worth while spending time in the search.

**Raising the anterior flap.**—The next step is to mark out the incisions for the removal of the extremity; these form practically an oval incision including the shoulder and part of the scapula. An assistant abducts the arm to a right angle and pulls the trunk well over so that the shoulder projects free of the table and then the front portion of the incision is marked out. From the centre of the incision over the clavicle the knife should be carried downwards with an outward curve over the coracoid process to the junction of the anterior fold of the axilla with the arm. It

is then carried transversely across the axilla to its posterior fold and thence to the inferior angle of the scapula (see Fig. 86); the assistant meanwhile so manipulates the arm as to facilitate the fashioning of the flap.

This anterior incision is now deepened by dividing the muscles; when these are healthy they may be divided close to the humerus and a flap of skin and muscle is turned inwards so as to expose the contents of the axilla, which of course consist of the vessels already divided above, and of fat and glands, which should be stripped down in one mass so that they can be removed along with the upper extremity. The arm and shoulder are next rotated outwards so as to expose the ventral aspect of the scapula, and the serratus magnus and the rhomboids are divided

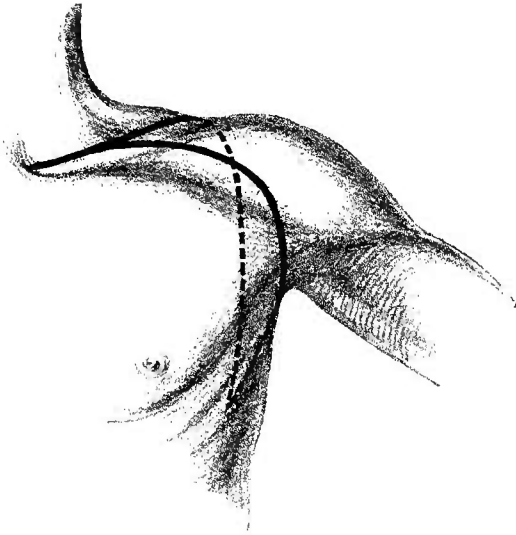


FIG. 86.—INCISIONS FOR REMOVAL OF THE ENTIRE UPPER EXTREMITY. The thick line shows the incision on the anterior aspect of the trunk, the dotted one that on the posterior.

near their insertion into the posterior border of the scapula; the levator anguli scapulæ is similarly treated. The posterior scapular artery, if not already secured, will be divided here and may be clamped.

**Raising the posterior flap.**—The patient is now turned over upon the sound side, the arm pulled forcibly across the chest by an assistant, and the posterior incision which runs from the extreme outer end of the incision over the clavicle to the inferior angle of the scapula by the shortest route is marked out. As this incision is deepened and the flap is turned back, the few remaining muscular fibres are divided, and the extremity is thus removed.

Although the main vessels have been already tied, numerous small points are found to bleed, and these should be clamped and tied. The greatest difficulty is met with at the posterior border of the scapula when the posterior

scapular artery has not been secured in the early steps of the operation, and this region is the one to which attention should be first directed after the extremity has been removed. The best plan is to pack a large number of sponges over the whole raw area immediately the extremity is severed, and to have pressure exerted upon them by an assistant; one sponge after another is then removed and the vessels picked up. Usually the amount of bleeding is not at all excessive.

Before the wound is stitched up, careful search should be made for any diseased glands that may have been left behind, and these should be carefully removed. A large drainage tube is inserted at the lower angle of the wound, the usual antiseptic dressings are applied, and fixed in position by a broad sheet of muslin passing around the trunk. This should have an aperture on the opposite side through which the sound arm is passed; it is then firmly pinned around the thorax. The wound heals rapidly; the drainage tube may be left out about the fourth or fifth day and the stitches taken out about the tenth.

#### REMOVAL OF THE SCAPULA.

It may sometimes be possible to remove the scapula alone and to leave the extremity intact; in this way a very useful arm may be left. In some cases, although very rarely, partial removal of the scapula may be practised, but, as the operation is usually done for malignant tumours of the bone, it is as a rule not advisable to attempt to leave behind any portion, except possibly some part of the acromion process. This structure is of importance, as its retention materially increases the usefulness of the limb.

The removal of the scapula alone is considerably more difficult than removal of the entire upper extremity, the points of greatest difficulty being the severing of the muscles attached to the coracoid process and the free hæmorrhage which is apt to result from the sub-scapular artery or its dorsalis scapulæ branch.

In order to overcome these difficulties we have recommended<sup>1</sup> that the operation should be commenced by making a separate incision into the axilla designed to detach the muscles from the coracoid process and to ligature the sub-scapular artery; this should be done before the ordinary incisions for the removal of the bone are made. This procedure has the further advantage that when the growth projects forward into the axilla, as it did in the case which led us to employ it, the disease may involve the vessels or the nerves, or, if it does not actually involve them, it may so displace them forwards that there would be some risk of dividing them towards the end of the operation. Through the agency of the axillary incision however these important structures can be thoroughly separated from all connection with the scapula or the tumour, and can be kept out of the way by an assistant throughout the remainder of the operation.

<sup>1</sup> See *Clinical Society's Transactions*, vol. xxviii., p. 284.

**Preliminary incision.**—The operation, as thus modified, is begun by making an incision similar in direction to that for ligation of the third part of the axillary artery (see Part II., p. 337) but of considerably greater length. It should be about six inches long, commencing below at the junction of the axillary artery with the brachial, and should run up in the line of the former vessel so that the axilla is fully opened throughout its whole extent. The anterior fold of the axilla is raised so as to expose the coracoid process, the muscles attached to which—namely, the pectoralis minor, the coracobrachialis, and the short head of the biceps—are then divided by a knife or scissors kept close to the bone. This fully exposes the axillary artery, and its sub-scapular branch is at once identified and ligatured. The large vessels and nerves are then raised by the hand passed beneath them

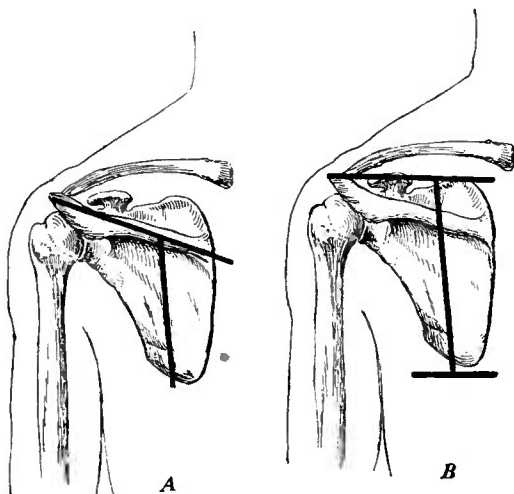


FIG. 87.—AMPUTATION OF THE SCAPULA.

*A.* The most suitable incisions when the deltoid and latissimus dorsi muscles are not involved in the growth.

*B.* Incisions useful when these muscles are so involved. The vertical incision in these cases often has to be made an elliptical one.

[The preliminary axillary incision recommended in the text is not shown.]

and separated from any adhesion to the growth. Should the latter encroach at all upon them, a broad copper spatula may be passed between them and it and left in position during the rest of the operation.

**Incision for flaps.**—The patient is now turned over almost upon the face, and incisions are made for the removal of the scapula. When the growth does not involve the muscles over the back of the bone, a convenient incision is one beginning over the acromion process and carried downwards and backwards along the spine of the scapula to about a couple of inches beyond the vertebral border. From the centre of this incision a second is made running vertically downwards to the inferior angle (see Fig. 87, *A*). When however the tumour involves the muscles upon the back of the bone, this incision will have to be modified according to circumstances. In many cases a portion of the skin over the tumour will have to be included in

an oval incision and removed. In other cases an **I**-shaped incision gives the best result. This incision, commencing at the acromion process, runs along the upper border of the scapula to its vertebral angle: from the centre of this a vertical incision is carried down to the inferior angle, and at the lower end of this a second transverse incision is made. This gives two flaps which are turned outwards and inwards, and which will consist simply of skin and subcutaneous tissue (see Fig. 87, *B*).

When however the first incision described can be employed it is of considerable advantage, as the attachments of the trapezius and the deltoid can afterwards be stitched together and thus the movements of the arm may be more satisfactorily preserved. The incision is deepened and the attachments of the trapezius to the upper border of the spine and of the deltoid to its lower edge are divided. The flaps with the muscles are turned aside. An assistant then forcibly pulls the arm forwards and downwards and thus puts the rhomboidei on the stretch so that they are easily divided. The finger is then passed beneath the posterior border of the bone and the serratus magnus is pulled forward and rapidly cut through. If the acromion is to be left behind it should now be snipped across with bone forceps, or if it is to be taken away it should be disarticulated from the clavicle. The teres major should next be divided, and after that the rotator muscles of the humerus are cut across close to the scapula if they be free of the disease, or close to the humerus if they be involved in it. The scapula is now freed except for the attachment of the levator anguli scapulæ, the omo-hyoid and the supra-scapular vessels and nerves. When they are divided, disarticulation at the shoulder joint is performed and there is nothing to prevent the removal of the bone, as the structures attached to the coracoid process have already been divided.

The arteries requiring ligature are the posterior and the supra-scapular. These can often be tied or clamped before division. The posterior scapular is seen immediately after the division of the rhomboidei and the levator anguli scapulæ, whilst the supra-scapular is not divided until just before the bone is removed, and it can easily be seen above the supra-scapular notch: the sub-scapular has of course been already secured through the preliminary anterior incision.

After the bleeding has been arrested, the trapezius and the deltoid muscles which have been detached from the spine of the scapula (when the condition of the parts allows this to be done) are sewn together by catgut in the manner recommended for suture of muscles (see Part II., p. 199). As we have already remarked, the union of these two muscles is of great importance to the subsequent usefulness of the arm. If the rotators of the humerus have been divided close to the scapula they may be stitched to the serratus magnus in the same manner: but this is not a matter of so much consequence, because they readily form adhesions to the scar, which gives them a more or less fixed point to act from.

**After-treatment.**—The wound should be sewn up with a large drainage tube inserted at its lower angle; a large gauze dressing is applied, with suitable sponge pressure over the flaps to prevent accumulation beneath them. The arm must be well pushed up against the acromion and supported by a suitable sling, a pad being placed in the axilla to throw the head of the bone away from the side. This support to the arm must be continued for three or four months after the wound has healed, so as to allow the parts to become consolidated before the weight of the limb is allowed to tell upon them. Passive movement of the upper extremity should be begun in about three weeks, when the patient should also attempt active movement.

**Results.**—The results obtained are really extremely good, particularly when the acromion process is left. As a rule all underhand movements are perfect and the most complicated manipulations can be performed; overhand movement however is practically never regained.

## CHAPTER XVII.

### AMPUTATIONS IN THE LOWER EXTREMITY

#### AMPUTATIONS OF THE TOES.

**General considerations.**—These operations may be called for under circumstances similar to those demanding amputation of the fingers, but there is this great difference between the two cases, that, whereas in the fingers it is important to preserve all the bone that can safely be retained, in the toes it is best to remove the entire phalanx instead of leaving part behind. With the exception of the great toe, a portion of a toe is of no use whatever to the patient; on the contrary it is likely to become drawn up, to press against the boot and to give rise to pain and ulceration. As long as the heads of the metatarsal bones are left and the tread of the foot is thus unimpaired, the loss of one or indeed several toes is a matter of no great importance.

In the case of the great toe, however, the exact contrary is the case; through it a great portion of the weight of the body is transmitted to the ground and it is therefore important to save even a small portion of the first phalanx. But if this be done, it is essential that the tendons should be stitched to the periosteum or to the edge of the tendon sheaths in a manner similar to that described for removal of portions of the phalanges of the fingers (see p. 247).

**Methods of amputating.**—The methods of amputation for the toes are absolutely identical with those for the fingers, and we need not therefore describe them again. The incisions are illustrated in Fig 88, *A*. It must be remembered that the metatarso-phalangeal joint is relatively higher above the web than the metacarpo-phalangeal joint, and the articulation is not so easily made prominent by bending the toes as it is by bending the fingers.

**Removal of the metatarsal bones.**—The metatarsal bone may also be removed along with its corresponding toe in a manner similar to that employed for the hand, by prolonging the handle of the racket-shaped in-

cision upwards over the dorsal surface of the metatarsal to just beyond its base (see Fig 88, *B*). In the case both of the great and the little toes it is of the utmost importance to remove as little as possible of the metatarsal bone because both of them play an important part in supporting the weight of the body. It is also important to remember that no incisions should be carried into the sole of the foot, nor should they be placed either upon its inner or outer borders, as otherwise the resulting scar will be subject to pressure and may be a source of considerable pain.

It is also of the highest importance to remember that the skin of the toes and the feet, especially in the region of the nails, is extremely difficult to disinfect thoroughly, and special care will have to be taken in

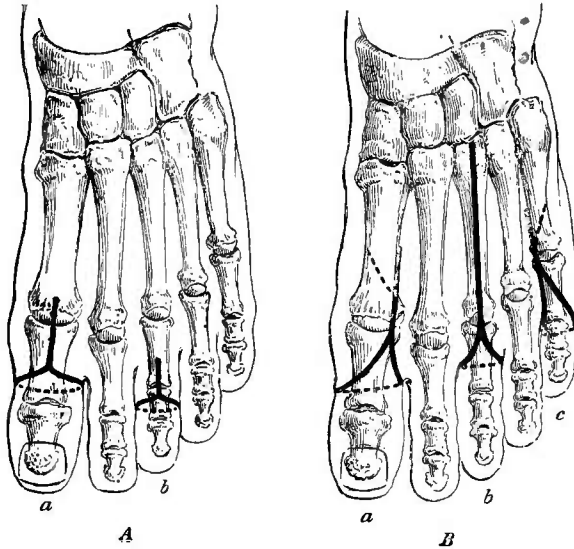


FIG. 88.—AMPUTATIONS OF THE TOES.

*A.* Amputations of the phalanges; *a* is an amputation at the metatarso-phalangeal joint, *b* one through the first interphalangeal joint.

*B.* Amputations of the toes along with the metatarsal bones; *a* and *c* are amputations of the great and little toes with the heads of the metatarsals respectively. As little of the bone is removed as possible. The dotted line shows the direction in which the bone is divided. *b* shows the removal of a toe with its entire metatarsal bone.

the purification in all these operations; in fact, it is a good rule to keep the skin soaking in disinfectant solutions, such as a 1-2000 corrosive sublimate or a 1-20 carbolic acid solution for 24 hours before the operation; this can be done by means of a wet gauze compress in which evaporation is prevented by covering it with mackintosh or jaconet which overlaps the compress widely in all directions.

#### AMPUTATIONS OF THE FOOT.

A great variety of amputations are described for use in the foot, but in actual practice it is extremely rarely that the majority of these can be



performed. A point of practical importance for the practitioner to remember is that, just as in the hand, it is very necessary to leave behind as much of the foot as possible, and that therefore irregular amputations will be far more frequently of use than the set operations described in the text-books on operative surgery.

**General considerations.**—There are one or two practical points common to the various operations on the foot which it may be well to mention here. In selecting flaps, the skin from the plantar surface will form the best material, and should be utilised wherever possible. No scar should be allowed on the plantar surface or upon either side of the foot, as it would be exposed to considerable pressure; it should lie either over the end of the stump, to which there is no particular objection, or somewhat on the dorsal surface; if possible it should lie just over the dorsal aspect of the end of the stump. If it comes too high up upon the instep it may be subjected to friction from the boot. So great is the value of even a small portion of the foot—even though only enough be retained simply to preserve the action of the ankle joint—that it is in some cases quite allowable to make flaps that are too short to meet accurately, and to skin-graft the gaps left between them. This however should only be done when the interval so grafted lies upon the dorsum, for a skin-grafted patch upon the sole would interfere considerably with the patient's walking. We have, however, in more than one instance, in bad burns of the foot where the sore would not heal, done a partial amputation through the ulcerating surface so as to loosen the scar, and then skin-grafted the remainder of the wound with highly satisfactory results.

*Lisfranc's operation.*—Several set operations are described for amputation of the foot, but as they are practically never performed we shall not go into them in detail. The first of these is Lisfranc's in which disarticulation is effected through the tarso-metatarsal joints, and the stump is covered in by a long plantar flap which is made to fold upwards over the end of the tarsus. On account of the difficulties experienced in disarticulating the base of the second metatarsal bone, this operation was modified by Hey, who sawed the base of the bone across.

It can very readily be understood that in cases requiring amputation in this situation it is extremely seldom that a plantar flap of the requisite length will be obtainable. Should the case be one of severe crush of the toes, some much more partial operation will probably suffice; should the damage involve the metatarsal bones, it is practically certain that the tissues in the sole of the foot will be as seriously injured as those upon the dorsum. In cases of gangrene also, amputation is quite impracticable so near to the gangrenous part, and should the case be one of tumour, the amputation will of course have to be performed at a higher level. Therefore, the operation is practically only performed upon the dead subject.

*Chopart's amputation.*—Similar remarks apply equally to the amputation known as Chopart's, which is frequently performed upon the dead subject

and in examinations, but is extremely rarely done for the living. The operation consists of a disarticulation at the medio-tarsal joint, the covering being obtained by a long plantar flap which extends forwards to the balls of the toes. In disease of the tarsus this operation is inadvisable, because the disease is sure to extend to one of the articular surfaces of the astragalus or the os calcis, and it is not easy to remove all the diseased synovial membrane. In cases of injury a long plantar flap will be unattainable, and in cases of gangrene the front part of the plantar surface will probably be involved in the gangrenous process. Quite apart from these drawbacks to the operation itself, the after results are not all good. The tendo Achillis always draws up the heel and therefore depresses the front of the stump. Even if tenotomy be performed at the time of the operation, this tilting of the stump recurs at a later period when the tendoii has united. The result is that the patient bears pressure upon the end of the stump and there is considerable pain and ulceration. In our opinion these operations might with great advantage be left out of text-books on operative surgery.

**Sub-astragaloid amputation.**—One of the set operations upon the tarsus however, namely, the sub-astragaloid method, is very valuable and well worthy of trial. The operation consists in removing the whole of the tarsus below the astragalus leaving the latter behind with the ankle joint

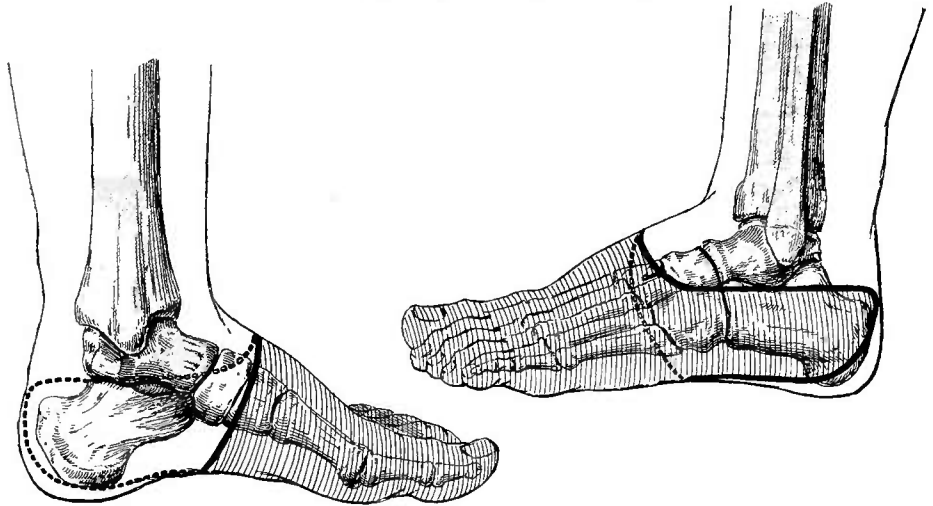


FIG. 89.—FARABEU'S SUB-ASTRAGALOID AMPUTATION OF THE FOOT. The shaded portions of the foot are those removed. The deeply shaded bones, on the other hand, are those left behind. The thick continuous line is the incision on the side looked at, the interrupted one that on the opposite side.

unimpaired. This has the great advantage that the natural ankle-joint movement can be communicated to the artificial foot. The best method is perhaps that recommended by Farabeuf, who makes a large internal plantar flap (see Figs. 89, 90).

The patient lies upon the back with the foot projecting well beyond the

end of the table. The skin is scrupulously purified, and the front part of the foot should be wrapped up in gauze soaking in a 1-2000 sublimate solution, so that the hands of the assistant holding it will not be infected and therefore cannot endanger the wound. This precaution should be adopted for all amputations about the foot.

The incision should commence about a finger's-breadth below the tip of the external malleolus. From that point it extends forwards parallel to the outer border of the foot as far as the level of the tubercle of the fifth metatarsal bone. It then sweeps across the dorsum of the foot

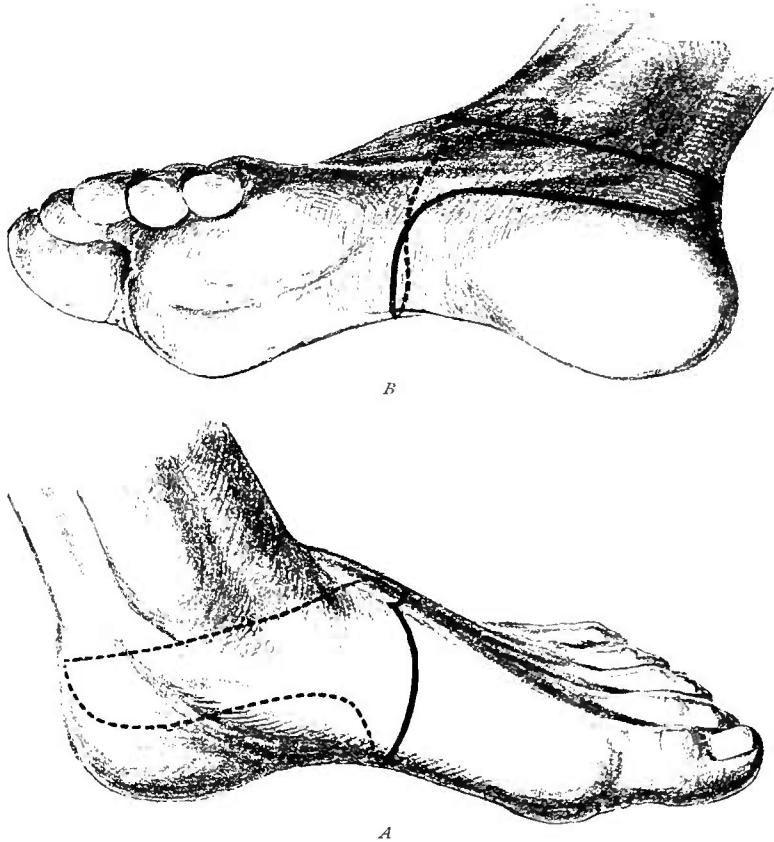

FIG. 90.—FARABEUF'S SUB-ASTRAGALOID AMPUTATION OF THE FOOT. Lines of incision seen in *A* from the inner, in *B* from the outer side of the foot. In each case the dotted line shows the line of incision on the opposite side of the foot to that from which the drawing is made.

with a slight convexity downwards just in front of the articulation between the scaphoid and the cuneiform bones, as far as the tendon of the extensor proprius hallucis. From this point the incision is continued downwards across the inner border of the foot to the centre of the sole, and during this part of its course it has a marked convexity forward which reaches as

far down as the central point of the inner border of the foot. From the centre of the sole the incision passes across to the outer border of the foot, sloping gradually back as it does so until it passes on to the outer surface just behind the tuberosity of the fifth metatarsal bone. It now follows the outer border of the foot until the outer tuberosity of the os calcis is reached, when it passes upwards over the back of the heel to join the first part of the incision which has been prolonged horizontally backwards from the malleolus to the insertion of the tendo Achillis. While the last part of the incision is being made the foot must be elevated and flexed.

This incision is carried right down to the bone and the flap thus formed is dissected up, while the leg is rotated inwards and the foot held at right angles to it with its outer surface uppermost. As the flap is raised, the articulations between the os calcis and the astragalus on the one hand, and the astragalus and the scaphoid on the other are exposed. If the dorsal part of the flap be dissected well back and held out of the way, the joint between the astragalus and scaphoid can easily be opened, and then, by depressing and pulling the point of the foot inwards the knife can be passed between the astragalus and the os calcis and the strong interosseous ligament divided. The insertion of the tendo Achillis is now divided and the soft structures carefully detached from the rest of the os calcis, in doing which great care must be taken to keep the edge of the knife close to the bone for fear of injuring the flap. The anterior and posterior tibial nerves should be pulled out and cut off as high up as possible.

When the edges of the flap are brought together, the line of union is on the anterior and outer aspect of the stump and the patient walks on the thick skin normally forming part of the sole. It is well to insert a drainage tube at the posterior angle of the wound; this may be left in for three or four days.

It will generally be found that in about three or four weeks the stump is firm enough to allow the patient to bear weight upon it. In the interval, the ankle joint should be exercised passively, so as to keep up movement and prevent adhesions.

**Syme's amputation.**—This is one of the most useful amputations about the foot and is applicable to a large number of cases. It may be employed for gangrene which is limited to the toes, so long as the tibial arteries are unobstructed; it is useful for many cases of tumour of the foot, and for tuberculous disease and severe crushes of the tarsus. It has also been employed for tuberculous disease of the ankle joint itself, but it is very difficult to remove the disease thoroughly without running the risk of damaging the vitality of the flap, and it cannot therefore be recommended for these cases; we should much prefer to cut a lateral flap in preference to the heel one described by Syme. In all the other cases, however, Syme's amputation provides an excellent stump

capable of bearing the entire weight and very easily fitted with an artificial limb.

The operation is performed as follows. The preliminary measures for disinfection, etc. recommended on p. 272, are attended to, and a tourniquet is applied around the lower third of the thigh. The patient lies upon his back with the foot projecting well over the end of the table and held by an assistant strictly at right angles. The surgeon then marks out the base of his flap by placing the thumb over the tip of the external malleolus and the forefinger at a corresponding point upon the inner side

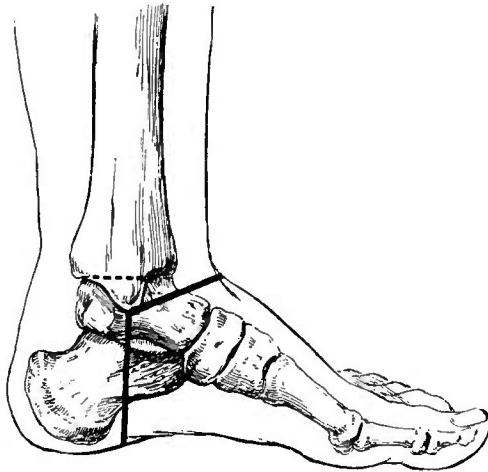

FIG. 91.—SYME'S AMPUTATION. The thick lines denote the skin incisions which pass direct from one side to a corresponding point on the other. The dotted line is the level of the bone section when the joint is healthy; should there be disease of it, the section will be entirely above the articular cartilage.

of the foot; that is to say, about half an inch below and a little behind the tip of the internal malleolus. These two points are then connected by an incision carried vertically downwards across the sole which goes right down to the bone. It is important that this incision should run vertically downwards and transversely across the sole from one point to the other (see Fig. 91). Should it be made to slope at all forwards into the sole,



FIG. 92.—SYME'S "FOOT-KNIFE."

great difficulty will be experienced during the later stages of the operation in dissecting back the flap. On the other hand should it be made to slope backwards towards the point of the heel, the flap will probably be insufficient to cover the ends of the bones. This incision should be made by a stout knife often termed a "Syme's" or a "foot" knife (see Fig. 92), and when it has been carried down to the bone, the two

original points are connected by an incision carried directly across the front of the ankle from one point to the other by the shortest route, so that there is no dorsal flap.

The next step is to dissect up the heel flap from the os calcis. The assistant should raise the limb until it is on a convenient level for the surgeon, and should point the toes so as to relax the structures over the heel while the flap is being raised. This is done by pressing back the edge of the flap with the thumb of the left hand whilst everything is dissected up down to the periosteum. As the flap is raised, the thumb pulls it back and prevents it from being damaged by the knife, the edge of which should be kept strictly in contact with the bone. The greatest difficulty is met with as the prominence of the heel is reached; at this point special care must be taken not to nick the posterior tibial artery on the inner side of the flap, as such an accident would dangerously imperil the nutrition of the flap. As soon as the prominence of the heel has been passed, the difficulty of the operation is over. The assistant then puts the tendo Achillis on the stretch and the surgeon divides this structure and continues to peel up the flap gradually from the posterior surface of the ankle joint.

When the heel flap has been raised to the level of the ankle joint the surgeon takes charge of the foot himself, bends the toes forcibly downwards and proceeds to disarticulate from the front. This is done by deepening the original incision across the front of the instep, dividing the tendons and opening the joint. The lateral ligaments are next divided and finally the posterior ligament; the posterior tibial artery must be guarded from damage during the manipulations on the inner side.

After the foot has been removed, the soft parts are cleared from the lower end of the bones as far up as the level of the articular surface; in doing this, great care must be taken not to damage the posterior tibial artery and also not to buttonhole the posterior flap, as is sometimes done by careless operators who double it up against the skin of the leg and forget that it is so doubled. While the leg is held horizontal the saw is applied at right angles to its long axis just above the articular surface of the tibia. It is not necessary to remove the whole of the articular cartilage unless it be diseased; all that is requisite is to saw off the malleoli.

The vessels requiring ligature are the anterior tibial in the centre of the dorsal flap, the posterior tibial, or more probably its internal and external plantar branches towards the inner edge of the heel flap, and one or two small vessels on the outer side. A small counter opening is made in the centre of the heel flap behind for the insertion of a fine drainage tube; this is very necessary, as otherwise the flap is certain to fill with blood, and healing may be considerably interfered with. The wound is next stitched up, and in doing this it is well to employ several stout interrupted fixation stitches inserted at some little distance from the cut edges so as to prevent any chance of the heavy heel flap falling backwards and becoming

detached; the union is completed by an ordinary continuous suture. The usual antiseptic dressings are then applied, the limb is placed upon a posterior straight splint with a special pad behind the heel flap so as to support it and press it forwards. When the case is aseptic the drainage tube may be removed in three or four days.

*After-treatment.*—In this amputation the treatment does not by any means cease when the wound has healed, because owing to the weight of the flap there is a considerable tendency for it to drag backwards and to bring the scar over the front of the lower end of the bones; this would lead to a tender scar interfering greatly with walking. The stump must therefore be carefully bandaged as already described (see p. 240) so as to pull forward and fix the heel flap; it is well after healing is complete to impregnate the bandage thus applied with starch so that it shall not slip, and to carry it well up the leg so as to enclose the stump in a stiff unyielding case. The patient can usually begin to bear weight upon the stump in from six to eight weeks; before that time he can get about wearing a peg-leg.

*Pirogoff's amputation.*—Syme's amputation has been modified by Pirogoff, who saws obliquely through the os calcis; the posterior portion of the bone and the skin over it are left behind. The operation is however unsuitable for any but a few rare cases. It is very troublesome to perform, and, as a matter of fact, the results it yields are not materially better than those obtained from Syme's amputation, whilst instrument makers rather object to it on account of the greater difficulty experienced in fitting the artificial foot. We shall therefore not describe the operation.

**Amputation through the ankle by an internal flap.**—In some cases—particularly of tuberculous disease of the ankle joint—Syme's amputation may with advantage be abandoned in favour of a somewhat similar one in which the posterior is replaced by an internal flap. On the whole, this operation is inferior to Syme's, because the skin in this situation is not so fitted for bearing pressure as is that over the back of the heel; nevertheless it gives a very good result, as the skin after a time becomes thickened and capable of bearing pressure. The incision commences at the tip of the external malleolus and runs across the front of the ankle with a slight downward curve until it reaches the astragalo-scaploid joint; from this point it passes straight on to about the centre of the sole, whence it turns backwards, passing over the centre of the heel to the level of the upper surface of the os calcis; it is then carried round the outer side of the ankle to join the commencement of the incision beneath the external malleolus (see Fig. 93). This large internal flap is raised carefully from the bone with which the edge of the knife is kept in contact throughout. The raising of the flap has to be effected with the greatest circumspection, as its nutrition is essentially derived from the posterior tibial artery, and therefore any injury to that vessel higher up than the point of section in the incision will materially damage it. When the ankle joint has been exposed, the foot is disarticulated and the lower ends of the tibia and fibula

are cleared and the malleoli sawn off just as in Syme's amputation. The cicatrix lies along the outer side of the stump, and the patient walks upon skin that is partly derived from the sole and partly from the inner side of the foot. In cases of tuberculous disease of the ankle this operation has the great advantage that the synovial membrane is much more easily removed along with the foot, and there is therefore not the same risk of recurrence in the stump.

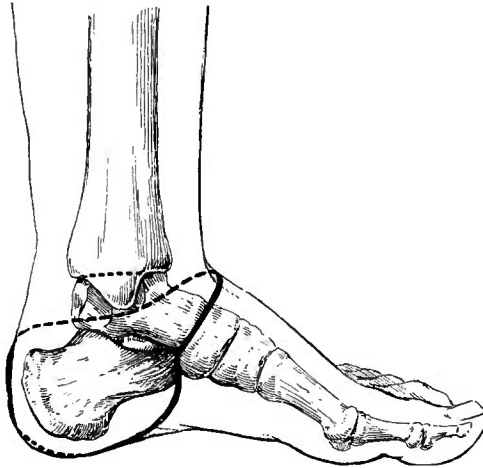


FIG. 93.—AMPUTATION AT THE ANKLE JOINT BY AN INTERNAL FLAP. The thick continuous line shows the incision upon the inner aspect of the foot, that on the outer being denoted by the thick dotted line. The thin dotted line on the bone shows the level of the bone section if the cartilage be healthy; otherwise it is well above this level.

#### AMPUTATIONS THROUGH THE LEG.

The general rule that the greatest possible amount of bone should be left in the stump, applies to amputations through the leg as to amputations elsewhere. Formerly the custom was to divide the bone at what was termed the "seat of election," namely, about a hand's-breadth below the tubercle of the tibia. The reason for this was that pressure was borne upon the bent knee which was received into what was termed a bucket stump, and the bones of the leg were therefore intentionally cut short so that there should be no undue projection behind. Of late years, however, the fitting of artificial limbs has been much improved and the natural movements of the knee joint are utilised; hence the longer the limb the better is the leverage that the patient can bring to bear upon the artificial limb.

**Lister's amputation.**—The best amputation through the lower third of the leg is that described by Lord Lister in Holmes' *System of Surgery*, Vol. III., p. 717 (see Fig. 94). His description is as follows:

"The diameter of the limb having been ascertained by spanning it, a straight longitudinal incision of that length is made at the inner side of the leg, and on the outer aspect another similar incision directly over the fibula



and extending about an inch higher up. The lower ends of these incisions are connected by cutting across the front of the limb in a direction transverse in the main, but rounded off where it joins the lateral lines. The knife is next carried round the back of the limb to the bone, from the upper end of the internal incision to a point exactly opposite on the outer side, which will be about an inch below the upper end of the outer incision; the instrument being carried in a line slightly convex downwards so as to form a very short posterior flap. The anterior flap is then raised in the manner above mentioned (by peeling up the tissues with the thumb) including everything in front of the bones and interosseous membrane; after which the tibia and fibula are cleared as high as the level of the upper end of the outer incision, the finger-tip being still used in detaching the parts anterior to the interosseous membrane. In order to avoid splintering the fibula, it is best to saw both bones at the same time, and to finish the fibula before the tibia. The sharp angle of the spine of the tibia being apt to cause ulceration of the skin over it, should be removed; and the most convenient way of doing this is to commence with sawing obliquely for a short distance from a point about half an inch above the place where the bones are to be divided transversely (see Fig. 73, *B*).

“Supposing effectual antiseptic treatment employed, the cutaneous margins of the flaps may be stitched very closely, except at the upper end of the outer incision, which is left open for the drain, and serves admirably for the purpose, as it leads directly from the cut surfaces of the bones and is dependent in position, from the circumstance that the limb reposes on its outer side. Accurate stitching is desirable elsewhere in consequence of the disproportion of the sizes of the two flaps, which, however, is diminished by making a short posterior flap as advised.”

In raising the anterior flap, special care must be taken to avoid damage to the anterior interosseous artery which lies immediately upon the front of the interosseous membrane. Therefore, in this situation the knife must not be used more than is absolutely necessary, and the tissues should be peeled off the membrane by means of the fingers or the handle of the knife. Before sawing the bones the interosseous membrane is divided with the knife. If the end of the tibia be rounded off, as is directed above, the stump very soon becomes able to bear considerable pressure, as the skin over the ends of the bones becomes thickened and closely resembles that upon

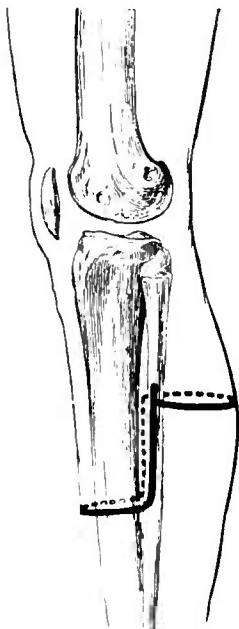


FIG. 94. — LISTER'S AMPUTATION THROUGH THE LEG. The vertical incision over the fibula extends about an inch higher up the limb than the corresponding one on the inner side. The amputation is shown unduly high up the limb.

the sole of the foot. The cicatrix is pulled well up out of the way behind by the contraction of the posterior muscles.

**Amputation at the "seat of election."**—Here the bones are usually divided about a hand's-breadth below the tubercle of the tibia. Various operations have been described, the one that we prefer being by means of a "hooded flap" fashioned somewhat after the manner of Stephen Smith's flaps for amputation at the knee joint (see p. 284). The operation is performed

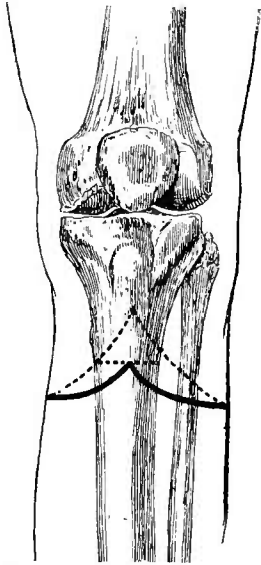


FIG. 95.—AMPUTATION OF THE LEG AT THE "SEAT OF ELECTION" BY THE "HOODED FLAP." The dotted line across the tibia shows the level at which the bones are divided. It will be seen that the incision shown above is notched in front, and does not run transversely across the limb as described in the text. The notching facilitates the raising of the flaps, and may be used when a bucket stump is to be worn.

as follows: The surgeon, standing upon the patient's right side, places the thumb of his left hand upon the crest of the tibia at the spot at which he desires to divide the bones, whilst the forefinger is placed in the centre of the calf about three inches higher up. Bending over the limb, he introduces the knife in the middle line of the calf just below the spot marked by his forefinger, and carries an incision almost vertically downwards, or with a very slight divergence to the side of the limb opposite to that on which he stands, to about two inches below the spot at which the bone is to be divided. The incision is then carried almost transversely across the front of the limb to a corresponding spot on the other side, whence it ultimately passes upwards to join the vertical incision in the calf (see Fig. 95); to enable the surgeon to mark out the last part of the incision the limb must be raised almost to the vertical. It is well, as a practical point, to have the flap somewhat longer on the inner side of the limb than on the outer. In this way a somewhat racket-shaped or oblique flap is fashioned, the lower end of which is about

two inches below the point of bone section. This flap is then raised, the muscle being taken up with it, and also, should it be healthy, the periosteum, and the bones are sawn at the point previously determined, and the crest of the tibia bevelled off. The result is that a hood of skin and muscle is formed which falls over the end of the bone, whilst the cicatrix lies vertically just behind the bone; as the contraction incidental to healing takes place, the scar becomes pulled up well behind the bone and out of harm's way.

Amputation at this situation may also be done by means of *lateral flaps*; but these are not to be recommended, because the cicatrix falls over the ends of the bones. This method should only be employed when amputation is performed high up and when the old bucket stump is to

be used. Under these circumstances there will be no pressure upon the ends of the bones, and the position of the cicatrix therefore is unobjectionable. In fashioning the lateral flaps it must be remembered that the one on the inner side must always be longer than the outer to allow for the greater width of the tibia. In other cases the operation may have to be performed by means of a *long anterior and short posterior flap*, but when the surgeon has the choice we greatly prefer the hooded flap above described.

**Other methods.**—It used to be the fashion to amputate the leg by a transfixion operation and to provide a long posterior and a short anterior flap, the former being the length of the diameter of the limb where the bones were divided, while the anterior flap was about one-third as long. The great objection to this plan is that the weight of the posterior flap drags upon the line of suture, and the union either gives way or the scar is pulled down till it comes to lie over the ends of the bones. The latter objection was no great disadvantage when amputation was performed at the “seat of election,” because no pressure was borne upon the end of the stump; but at the present time it is quite unsuitable, and should not be performed except where, owing to destruction of the skin on the front of the limb, it is necessary to make a long posterior flap in order to save the movements of the knee joint. Even when performed under these circumstances, it is better to cut the posterior flap from without inwards rather than by transfixion, and to take up only a comparatively small amount of muscle in it.

Another form of amputation was at one time a good deal employed and is always mentioned in detail in the text-books. This is the one introduced by Mr. Teale of Leeds, consisting of a long anterior rectangular flap and a similar short posterior one; the anterior flap corresponds in length to half the circumference of the limb at the spot where the bone is to be divided, and contains all the soft parts down to the bone; the posterior flap is about one-third the length of the anterior. This operation does not present any advantage nowadays over those already mentioned, and it can only be performed where there is an abundance of soft parts available, as otherwise it necessitates an unduly high section of the bone. We shall therefore not describe it.

#### AMPUTATION ABOUT THE KNEE-JOINT.

This form of amputation is most frequently required for malignant disease of the tibia, for injuries in which the condition of the parts does not allow of an amputation through the leg, and for gangrene of the foot when the tibial arteries are blocked. Whenever it is possible to obtain sufficient soft parts to cover in the condyles of the femur, disarticulation is always preferable to amputation through the lower end of the bone, because the broad smooth condylar surfaces are most admirably adapted for bearing pressure. Instrument makers rather object to amputa-

tions through the joint because it brings the new knee-joint in the artificial limb to a somewhat lower level than on the opposite side, but as a compensation for this we have a stump upon which the full weight of the patient can be borne without any trouble.

**Stephen Smith's amputation.**—In our opinion the best amputation at the knee-joint, whenever it can be performed, is that introduced by Stephen Smith, and often called the method by "hooded flaps." It is performed as follows: The patient lies upon his back with the sound leg flexed at the knee, and tied to the leg of the table so as to be out of the way of the surgeon, and with the limb on the affected side projecting well beyond the edge. The leg is fully extended and is held horizontal by an assistant, whilst the surgeon standing on the patient's right, first defines with the thumb and forefinger of his left hand the tubercle of the tibia in front, and a spot upon the middle of the popliteal space behind which corresponds to the posterior surface of the knee-joint. The assistant then rotates the limb somewhat towards the surgeon, who bends over and enters the knife behind at the spot fixed in the popliteal space, and carries an incision obliquely downwards for about a couple of inches, and then gradually sweeps round the side of the limb furthest away from him, cutting a rounded flap with its convexity downwards and crossing the middle line at a spot from one to two inches below the tubercle of the tibia. The knife is then made to start from the same point in the popliteal space as before, and is carried vertically downwards and across the opposite side of the limb until it joins the first incision over the crest of the tibia (see Fig. 96, *A*). The whole incision may, if preferred, be made in one sweep by raising the limb to the vertical position after the crest of the tibia has been passed and cutting upwards to the starting-point in the centre of the calf; this is on the whole perhaps the simpler method. It is well, instead of bringing the incision across the limb absolutely transversely, to make it run somewhat obliquely, so that the flap on the inner side is rather longer than that upon the outer; this is advisable on account of the larger size of the internal condyle of the femur. It is also well in most cases to notch the flap in front by carrying the incision almost up to the tubercle of the tibia and down again to its original level on the opposite side (see Fig. 96, *A*). This is not essential, but it gives a neater stump, which is also easier to suture afterwards.

The assistant now flexes the knee whilst the surgeon proceeds to raise the flap, which for the first inch should consist only of skin and subcutaneous tissues. After this, all the tissues down to the bone should be taken up. When the ligamentum patellæ is exposed, it should be divided immediately above the tubercle of the tibia and the dissection is then carried upwards all around the bone until the upper margin of the tibia is reached. The knife is now introduced between this bone and the semilunar cartilages so as to leave the latter in contact with the condyles of the femur. At the same time the tendons and ligaments

about the front and lateral aspects of the joint are divided, when by increasing the flexion of the limb the surgeon is able to complete the separation of the semilunar cartilages from the head of the tibia, and to divide the posterior ligament of the knee-joint. The division of the hamstring tendons and the vessels and nerves in the popliteal space completes the disarticulation. The arteries requiring ligation will of course be the popliteal, which with its vein will be found in the middle line behind the femur, and the anastomotica magna on the inner side of the flap: a few other ligatures will be required for articular and muscular arteries. The patella is left undisturbed in the flap.

A drainage tube should be inserted at the upper angle of the wound and may be removed in two or three days. The usual antiseptic dressings are applied, the limb placed in a short trough of Gooch's splinting, elevated and secured to an inclined plane or firm pillow.

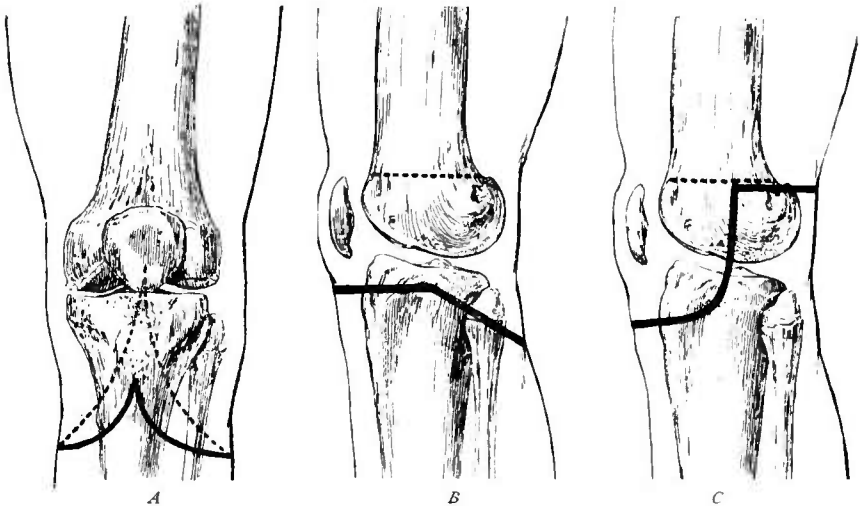


FIG. 96.—AMPUTATIONS ABOUT THE KNEE.

A. Stephen Smith's "hooded flap" method of disarticulation at the joint. In the original operation the incision ran transversely across the front of the limb, and was not notched as depicted above.

B. Lister's modification of Carden's amputation.

C. Carden's amputation through the femoral condyles.

In the two last operations the dotted line indicates the level at which the bone is divided.

This operation gives a large hooded flap which falls over the end of the femur, and the skin of this flap is dense and able to bear considerable pressure. The cicatrix is vertical, and lies partly behind the femur and partly in the hollow between the condyles. As healing goes on, it gets more and more drawn up upon the posterior aspect and out of the way of all pressure. The object of leaving the semilunar cartilages behind is to form a sort of natural pad which will furnish the rounded condyles with a more or less square surface and prevent injurious pressure upon

the flap. It is found in practice that the result is much more satisfactory when the cartilages are left behind than when they are taken away.

Various other amputations are performed in this situation in which the amputation goes through the condyles of the femur. This may be necessary, for example, when malignant disease of the tibia extends so high up that it is impossible to get sufficient covering after disarticulation, or when there is disease of the knee-joint itself; it may also be called for in severe injuries or septic troubles, such as extensive necrosis of the leg.

**Lister's amputation.**—Carden's amputation is most generally performed at the present day, but in our opinion it is advisable to adopt the modification suggested by Lord Lister in the *System of Surgery*, Vol. III., p. 718. The disadvantage of Carden's original operation is that sloughing may occur in a portion of the long anterior flap, and it is evident that this risk will be diminished if the flaps be made shorter by not carrying the horns of the incision so high up the limb on each side. Lister's amputation is performed as follows:

“The surgeon first cuts transversely across the front of the limb from side to side at the level of the anterior tuberosity of the tibia, and joins the horns of this incision posteriorly by carrying the knife at an angle of 45° to the axis of the leg through the skin and fat (see Fig 96, *B*). The limb being elevated, he dissects up the posterior skin flap, and then proceeds to raise the ring of integument as in a circular operation, taking due care to avoid scoring the subcutaneous tissue; and, dividing the hamstrings as soon as they are exposed, and bending the knee, he finds no difficulty in exposing the upper border of the patella. He then sinks his knife through the insertion of the quadriceps extensor, and having cleared the bone immediately above the articular cartilage, and holding the limb horizontal, he applies the saw vertically and at the same time transversely to the axis of the limb (not of the bone), so as to insure a horizontal surface for the patient to rest on. The popliteal artery and vein are then secured, and any articular or other small branches that may require it.

When the soft parts are thickened and condensed by inflammation, the integument cannot well be reflected above the patella with such incisions of the skin. But the difficulty may be got over by cutting into the joint as soon as the ligamentum patellæ is exposed, and at once removing the leg by dividing the ligaments and hamstrings; after which the soft parts can be retracted from the femur sufficiently to permit the application of the saw. The arteries having then been secured, the patella is dissected out at leisure.”

As thus performed, the amputation takes a little more time and trouble than when the large anterior flap is formed; but any extra trouble is amply repaid by the good covering to the bone, the small external wound, and the perfect security against sloughing.

*Carden's amputation.*—In Carden's original amputation a long anterior flap is formed by cutting downwards from the point at which the condyles

of the femur are to be divided on the one side of the joint, carrying the incision with its convexity downwards to a point well below the patella, bringing it across the front of the limb and up to a corresponding point upon the opposite side (see Fig. 96, *C*); this flap when raised should contain the patella. After it has been reflected to the point of section of the condyles, a transfixion knife is passed through behind, close to the bone at that spot, and by a steady sweeping cut the soft parts and skin are divided at right angles to the long axis of the bone, so that no posterior flap is made. The bone is then cleared at the proposed point of division, and the condyles removed by the saw applied at right angles to the long axis of the limb.

*The Stokes-Gritti amputation.*—The object of sawing the femur through the condyles is to furnish the patient with a broad flat surface upon which pressure may be borne. For the better accomplishment of this object it has been proposed to saw off the cartilaginous surface of the patella and to apply the cut surface thus formed directly to the cut surfaces of the femoral condyles. This procedure is known by the name of the Stokes-Gritti operation, but it does not present any advantages which counterbalance the increased time and patience required for its proper performance. It is a matter of considerable difficulty to cut off the cartilaginous surface of the patella completely and to apply it accurately to the sawn surface of the femur, and it is often very difficult, after this has been done satisfactorily, to secure it accurately in position, and to prevent it being tilted away from the bone by the pull of the quadriceps extensor muscle. For these reasons we cannot recommend the operation and shall therefore not describe it. Its results are in no way better than those of the amputations already described.

#### AMPUTATIONS THROUGH THE SHAFT OF THE FEMUR.

Amputation may be practised anywhere through the shaft of the femur; the usual situation is either at or below the middle of the bone, amputation in the lower third being especially suitable for tuberculous disease of the knee-joint.

In this situation the best operation is by means of antero-posterior flaps, but lateral flaps may be employed when the circumstances of the case are such that there is not sufficient sound skin available for an anterior one. A very good result may also be obtained by antero-external and postero-internal flaps. It should be remembered in amputating through the femur that it is not necessary to sacrifice bone in order to insure the cicatrix being out of the way of its divided end, because very little weight, if any, is borne upon the end of the stump when an artificial limb is fitted, as this takes its support mainly from the pelvis. The length of the femur left is of the greatest importance; the function of the stump is not to carry weight but merely to form a lever to work the artificial limb, and there-

fore the longer the lever the more satisfactory is the result. At the same time, when it is feasible, the scar should be made to lie out of the way of the end of the bone; should this not be possible it is of course necessary to pull out the nerves and cut them short so that their ends cannot become involved in the cicatrix. For some time the operation was done by transfixion, and some surgeons still prefer to cut the anterior flap from without inwards and the posterior one by transfixion. There is no great objection to this, but the flaps in all cases are more accurately fashioned if they are cut from without inwards.

*Means of controlling the circulation.*—In amputating through the lower or middle thirds of the thigh the circulation can be readily enough

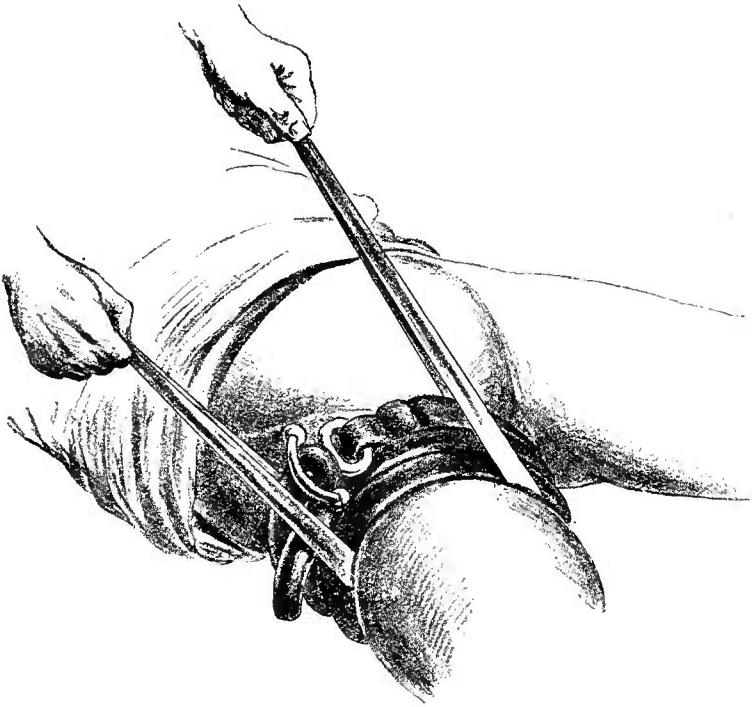


FIG. 97.—HOW TO PREVENT ESMARCH'S TUBING FROM SLIPPING DURING AN AMPUTATION THROUGH THE THIGH. Both the Esmarch's tubing and the strips of bandage with which they are pulled upwards should be carefully disinfected before use.

controlled by means of a stout indiarubber cord—which should be previously sterilised by boiling—passed around the limb at its upper limit. To prevent this from slipping off over the flaps after the femur has been divided, the best plan is to take two strips of sterilised bandage of sufficient length and lay them vertically over the limb, one on either side, and then to apply the elastic tube over these. When the tubing is in position, the pieces of bandage are converted into loops by seizing the two ends,



and these are pulled upon throughout the operation by an assistant, and thus the tubing is prevented from slipping (see Fig. 97). The assistant to whom this duty is entrusted may subsequently, when the tourniquet is removed, compress the femoral artery at the groin whilst the various bleeding vessels are being picked up in the flaps.

When amputation is called for still higher up in the limb the circulation may be satisfactorily controlled by means of similar elastic tubing applied as a spica around the groin, the two ends crossing over the great trochanter and being then passed around the pelvis and fastened on the opposite side (see Fig. 98). In this case also it is well to

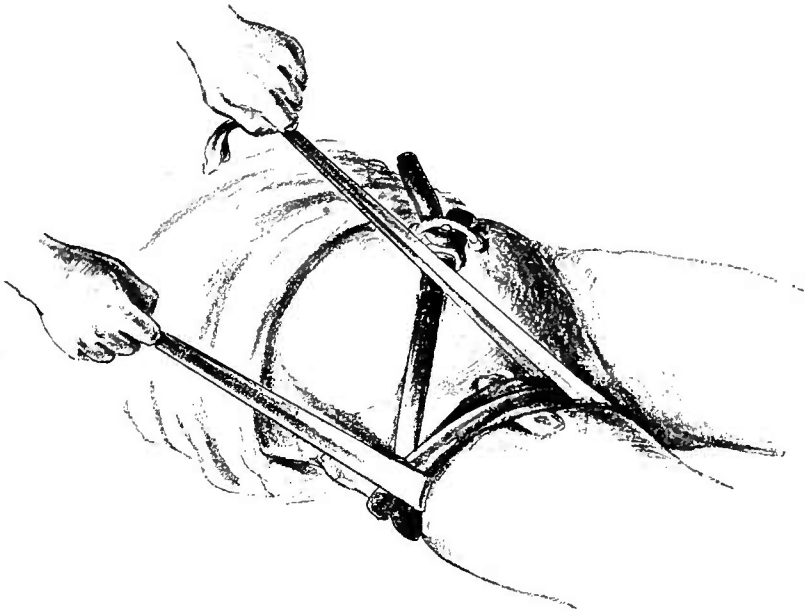


FIG. 98.—TOURNIQUET FOR USE IN AMPUTATIONS HIGH UP THE THIGH. There is a sterilised pad over the line of the femoral which is compressed against the pelvic brim.

pass strips of bandage beneath the tubing, one near the inner fold of the groin and another over the trochanter, and to give them to an assistant, who pulls upon them and prevents the possibility of the tubing slipping.

*Prevention of shock.*—In all these cases the surgeon must of course take every possible precaution to prevent shock (see Part I., p. 139), not the least valuable of which is rapidity of operation. The patient should be kept warm, the body being warmly clad and covered up. He should lie on a hot water-table and an enema of brandy and beef-tea should be administered half an hour before the operation, whilst the sixtieth of a grain of strychnine should be injected whilst he is being placed under the anæsthetic, and repeated if necessary during the operation. As soon

as the operation is over, the patient should be wrapped in warm blankets and put to bed surrounded by carefully covered hot-bottles. If these precautions be taken it is remarkable how slight the shock often is.

**By antero-external and postero-internal flaps.**—The operation which we prefer in all cases where choice is possible consists in making a flap on the anterior surface of the limb which shall be slightly antero-external rather than directly anterior; this flap should be about seven-eighths of the diameter of the limb at the point where the bone is to be divided. The object of having the flap somewhat external is to prevent the angle of union of the flaps lying over the femur, which is very liable to be the case when the flaps are anterior and posterior. The posterior flap should be about a third as long as the anterior one and both should consist merely of skin, subcutaneous tissue and deep fascia for the first two or three inches; then a gradually increasing thickness of muscular tissue should be taken up as they are raised, as has already been described for the flap method (see p. 228).

While sawing the femur, great care must be taken to keep the limb horizontal and perfectly steady, and the bone should be divided at right angles to its long axis. Special care must be taken when finishing the division of the *linea aspera*, for, if the assistant does not keep the limb steady, the saw is very apt to become locked, or else the bone may be fractured before it is completely sawn through. Should the latter event happen, the sharp edge of the *linea aspera* must be snipped off with bone forceps or rounded off with a saw (see Fig. 73, *B*).

A good sized drainage tube should be inserted at the outer angle of the wound, whilst the usual cyanide dressings are applied and the limb laid in a trough of Gooch's splinting supported upon an inclined plane; both the dressings and the splint should be fastened round the pelvis by a spica bandage. It is very essential to elevate the limb in order to relax the quadriceps extensor muscle, which would otherwise pull injuriously upon the anterior flap.

This method of amputation by means of long anterior and short posterior flaps, or by antero-external and postero-internal ones, is applicable to almost any part of the thigh, and the exact position and length of the flaps can be varied according to the circumstances of the case. But irregular operations should always be performed in preference to removing an unnecessary amount of bone. Almost the only amputation which is unsuited for the thigh is that by means of a long posterior flap.

#### AMPUTATIONS THROUGH THE HIP JOINT.

Amputation in this situation was formerly one of the most fatal and unsatisfactory operations which the surgeon was called upon to perform. The danger was due partly to the loss of blood at the time, partly to the profound shock occasioned by the division of large and important nerve

trunks, and also in a large degree to the septic infection of the wound which so frequently occurred afterwards. At the present time these dangers have much decreased, owing partly to improvements in the methods of operation and partly to the profound alteration in the treatment of wounds; the result is that in cases of amputation at the hip, except when done as a primary amputation for injury, the mortality is extremely slight if the patient be in good health when the operation is performed. The bleeding can be controlled quite satisfactorily, and the loss of blood rendered extremely slight. Further, when there is plenty of room, the soft structures may first be divided comparatively low down in the thigh and the head of the bone subsequently dissected out. In this way the large nerve trunks are divided at a much lower level than formerly, and the shock is thereby much diminished. Besides this, the flaps can be so planned that the line of incision is at a considerable distance from all sources of sepsis, which, combined with the improved antiseptic arrangements now in vogue, renders the avoidance of septic infection fairly certain.

Amputation at the hip joint has to be performed under two different sets of conditions. In the one case the nature of the disease permits of the formation of long flaps and of a preliminary division of the bone below the trochanters, whilst in the other the flaps have to be short, and disarticulation at the hip joint must be carried out at once without any preliminary division of the shaft of the bone. We shall describe operations suitable for each of these two main indications. The operation is generally required for tumours of the femur, but it may also be necessary in some cases of bad crushes of the limb, especially when the thigh is torn off; it may be called for in some rare cases of bone disease, such as widespread necrosis or extensive tuberculous disease of the femur, while some surgeons perform it for bad hip-joint disease where the trouble has extended on to the ilium or where there is lardaceous disease—in some instances with considerable benefit.

(a) **Cases in which the nature and situation of the disease do not call for disarticulation in the early stages of the operation.**—Here the control of hæmorrhage, the diminution of shock, and the arrangements for avoiding sepsis are much more satisfactory, and the mortality is comparative slight.

**Furneaux Jordan's amputation.**—The most suitable operation in these circumstances is that devised by Furneaux Jordan or some modification of his operation. It consists essentially of a more or less circular amputation of the limb well below the trochanters, and subsequent enucleation of the upper end of the bone. The nerves are divided low down and the angle of the wound is at a considerable distance from any possible source of contamination.

*Control of the circulation.*—In this operation the bleeding can be controlled without any difficulty by a band applied as a spica around the hip joint (see Fig. 98). The vertical strips of bandage along the inner and outer sides should be employed as shown there, and it is well

also to add an additional one behind, and to carry the tubing twice round the thigh and pelvis. Various other methods of preventing the hæmorrhage are employed, the next most satisfactory to the one described being the application of Esmarch's tubing around the abdomen so as to compress the abdominal aorta; but the objection to this plan is that it rather increases the shock owing to the pressure upon the nerves of the abdomen.

Should it be decided to employ this method, it is best done by taking a piece of wood about three inches wide, and about four inches longer than the transverse diameter of the trunk opposite the umbilicus, and placing it, padded with a thick folded towel, transversely beneath the patient opposite the last lumbar vertebra. A large pad of boracic lint or a

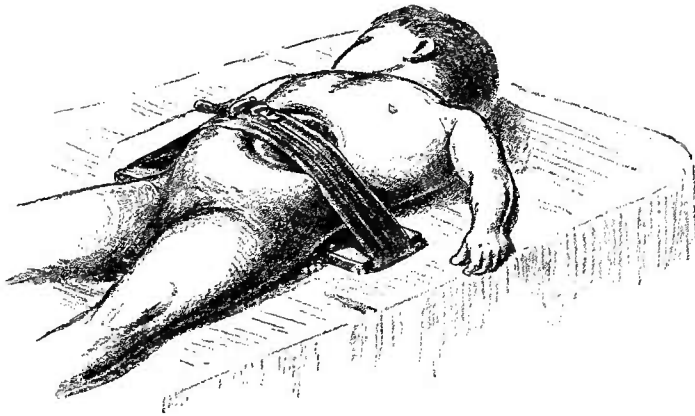


FIG. 99.—ABDOMINAL TOURNIQUET FOR USE IN AMPUTATIONS AT THE HIP JOINT. A thick folded towel should be interposed between the spine and the transverse board.

small folded towel, is then placed over the abdominal aorta, and, the patient being raised, the elastic tubing is passed transversely around the body across the front of the abdomen over the pad and around the ends of the wooden bar (see Fig. 99). The object of this is to compress the vessels satisfactorily whilst at the same time avoiding undue lateral compression of the abdominal walls.

Among other contrivances we may mention Lister's tourniquet, which was one of the first employed for arresting hæmorrhage in amputation at the hip joint. Another instrument was introduced by Mr. Davy and is known as "Davy's lever." This consists of a rod which is passed up the rectum and compresses the common iliac artery through the rectal wall against the sacro-iliac synchondrosis. Neither of these plans however is to be recommended. Lister's tourniquet, by its firm unyielding compression, is apt to do considerable damage to the contents of the abdomen, whilst with Davy's lever it has happened more than once that the point has been pushed through the wall of the rectum and the patient

has died of septic peritonitis; short of this, considerable rectal ulceration may be caused by it. Still another plan, namely, the introduction of a skewer behind the femoral vessels and the application of an elastic band in a figure-of-eight over it has been employed; this, however, apart from the uncertainty attaching to the passage of the skewer, is open to the great objection that it can only control the femoral artery itself, and therefore does not command the entire blood supply of the limb. The choice really lies between the spica around the groin or the Esmarch's tubing passed around the abdomen; in most cases the former is quite satisfactory.

*The operation.*—After the circulation has been controlled, towels are arranged so as to cover the whole of the lower part of the abdomen, the buttocks, and the perineum, and the most scrupulous care is taken to purify the limb, especially about the folds of the perineum. The point at which the bone is to be divided is determined upon, and a circular incision, somewhat notched at the inner side, is made around the thigh about an inch below this point (see Fig. 100, *A*). This notch on the inner side is made to enable the flaps to be raised with greater ease and to be more satisfactorily sutured afterwards. The incision goes through the skin, fat, and fascia, which are now dissected up for about two inches. The muscles are next divided circularly down to the bone, retracted carefully and the bone is sawn.

The next step in the operation is to secure the principal vessels, and then a vertical incision is carried up over the outer side of the femur to about two inches above the top of the great trochanter and deepened down to the bone from which the soft parts are readily dissected off. It is quite safe to remove the tourniquet at the end of the circular amputation after the principal vessels have been found and clamped. There is little fear of bleeding in the later stages of the operation, any large vessels divided being clamped at once. It is usual, when the circumstances of the case allow it, to carry the incision right down through the periosteum, which is stripped off from the bone along with the soft parts. The sides of the vertical incision are then held well apart and the head of the bone is seized in lion forceps, rapidly dissected out, disarticulated, and removed. Some surgeons do not saw the bone after the muscles have been divided in the circular amputation, but make use of the intact femur to aid the manipulations necessary for disarticulation. It is immaterial which method is employed.

When all bleeding has been arrested, a large drainage tube leading down to the acetabulum is inserted at the upper and outer part of the wound and the rest of the incision is sewn up. The usual antiseptic dressings are applied, and, in order to prevent them slipping, it is well to fasten the inner side to the perineum by means of a layer of dry gauze and collodion, and it is also very important to cover the inner aspect of the dressing with mackintosh in order to prevent it from being soiled. The best way

to do this is to take a piece of mackintosh sufficiently long to extend from the middle line of the thigh in front to well beyond the middle line behind and broad enough to reach from the perineum down to the end of the stump. A broad piece of adhesive plaster of the same length as the piece of mackintosh is then taken and the edge of the mackintosh is fixed by means of it to the skin of the perineum. The same thing is done outside the dressings above and behind, and thus the mackintosh is firmly fixed and prevents their being soiled. A trough of Gooch's splint should be applied and it and the bandages fastened on by a spica; the lower end of the splint is raised and secured to a firm pillow.

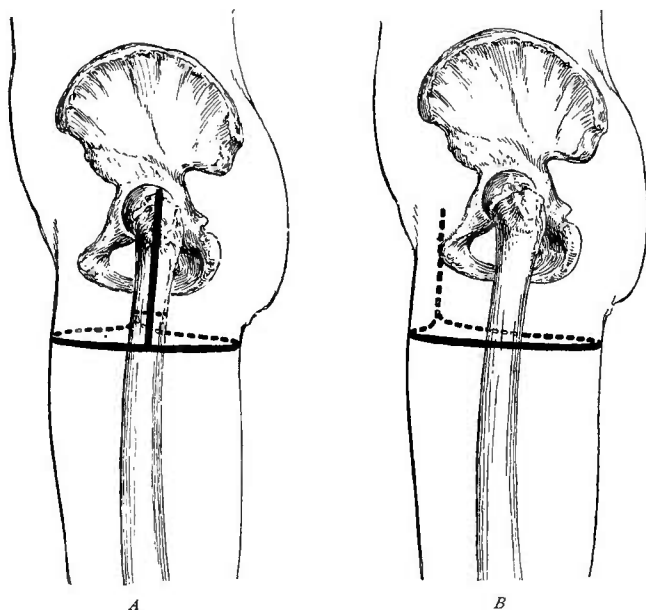


FIG. 100.—AMPUTATIONS THROUGH THE HIP JOINT.

*A. Furneaux Jordan's Amputation.* The circular amputation is done first, and the bone sawn along the dotted line. The vertical incision is then added, and the upper end of the bone enucleated.

*B. Amputation by oval flaps (internal racket).* The vertical incision is made first and lies over the femoral vessels.

The dressing must be changed on the following day on account of the free oozing that will occur. Subsequent changes of dressings will be called for according to the amount of discharge; it is better to err on the side of changing the dressings too frequently than to do it too seldom; as a rule it will be found necessary to dress the stump every day for the first three or four days. The drainage tube may usually be left out in about a week.

(b) **Cases where it is impracticable to perform a Furneaux Jordan operation.**—These are usually cases of malignant tumour in the upper third of the thigh. Under these circumstances the operation

must be performed directly through the hip joint itself, and this is best done by means of an oval flap.

A vertical incision is first made from the centre of Poupart's ligament downwards along the course of the femoral vessels, which are exposed, tied, and divided between two ligatures. The incision is then carried rapidly around the thigh in an oval form, and in this way becomes a more or less racket-shaped incision, the handle of it along the thigh being carried as low as possible under the circumstances of the case (see Fig. 100, *B*). The skin and fascia alone are first divided and dissected up for about two inches. The muscles are then cut across, care of course being taken to divide them as close to the pelvis as possible when the tumour is high up. The head of the bone is then rapidly disarticulated and pulled forcibly forward, when the muscles in the buttock are divided by a few strokes of the knife. The only vessels requiring ligature will be those in the buttock, and will consist essentially of the gluteal and sciatic vessels and their branches; they can be readily clamped without any material loss of blood.

The results of this operation are very satisfactory. Comparatively short flaps can be made which meet very nicely over the wound. The drainage tube should be placed in the lower and posterior angle of the wound and the dressing should be fixed on and the mackintosh applied as above described. The amount of blood lost is quite small, and the after-treatment is practically the same as that just described.

The old method of performing amputation at the hip joint by means of antero-posterior flaps cut by transfixion has nothing whatever to recommend it. Unless the bleeding be accurately controlled, a considerable amount of blood is lost, and the incision runs in such a direction that it is almost impossible to keep the wound aseptic. Hence we have not thought it necessary to describe the operation.

# INDEX.

## PART III.

- ABSCCESS, chronic of bone, 182  
    drainage of, 184  
    in tuberculous disease of bone, excision of, 200
- Acetabulum, fractures of, 105
- Acromegaly, 218
- Acromial end of clavicle, fracture of, 56  
    treatment, 61
- Acromion process of scapula, fracture of, 63
- Actinomycosis, causes and treatment, 219
- Acute epiphysitis, 172  
    treatment, 179  
    inflammation of bone, 170  
    necrosis, 172  
    non-suppurative osteitis, 171  
    suppurative osteitis, 171  
        of flat bones, treatment, 181  
        with joint suppuration, treatment, 180  
    suppurative osteo-myelitis, 171  
        treatment, 175  
        in flat bones, 181  
        with periostitis after an open wound, 181  
    suppurative periostitis, treatment, 174  
        with osteo-myelitis after an open wound, 181  
        tuberculosis of bone, 196  
    "Albuminous periostitis," 171
- Aluminium plates for fixing fractures, 53
- Alcohol in delirium tremens, 46
- Alcoholism as cause of non-union of fractures, 49
- Amputating knife, 235
- Amputation in acute epiphysitis, 180  
    in acute necrosis, 181  
    in acute osteo-myelitis, 177  
        with periostitis after an open wound, 181  
    in acute suppurative osteitis, 180  
    in chronic inflammation of bone, 185  
    in compound fracture, 34-36  
    general considerations with regard to, 222-243  
    essentials of a good, 223
- Amputation  
    methods of, 224  
        circular, 224  
        "flap," 228  
        modified circular, 226  
        irregular, 232  
        racket, 231  
            "hooded flap," 232  
            "racket incision," 231  
    present position of in surgery, 222  
    typical amputation, method of performing a, 232  
        after-treatment, 239  
        amputating knife, 235  
        drainage in, 238  
        dressings in, 238  
        flaps, cutting of, 235  
        stitching of, 237  
        preliminary steps, 232  
            arrest of hæmorrhage, 233  
            disinfection, 232  
        prevention of shock, 234  
        sawing bone, 236  
        securing vessels in, 237  
        septic cases, 242  
        splints in, 238  
    in necrosis of bone,  
    in sarcoma of bone, 220, 221  
    in tuberculosis of bone, 202
- Amputations, 222  
    in lower extremity, 271  
        femur, through shaft of, 287  
            control of circulation in, 288  
            prevention of shock in, 289  
    foot, of the, 272  
        Chopart's amputation, 273  
        Farabeuf's sub-astragaloid, 274  
        Pirogoff's, 279  
        Lisfranc's, 273  
        Syme's, 276  
            after-treatment, 279  
            through ankle by internal flap, 279  
    hip joint, through the, 290  
        Furneaux Jordan's, 291



- Amputations**  
 in lower extremity  
 hip joint, through the  
 Furneaux Jordan's  
 control of circulation, 291  
 where Furneaux Jordan's operation is impracticable, 295  
 knee joint, about the, 283  
 Carden's, 286  
 Lister's, 286  
 Stephen Smith's, 284  
 Stokes-Gritti, 287  
 leg, through the, 280  
 Lister's, 280  
 at "seat of election," 282  
 by hooded flaps, 282  
 by lateral flaps, 282  
 by long anterior and short posterior flaps, 283  
 Teale's method, 283  
 transfixion operation, 283  
 toes, of the, 271  
 in upper extremity, 244  
 arm, through the, 259  
 circulation, control of, 259  
 elbow joint, through the, 257  
 entire removal of upper extremity, 264  
 fingers, of the, 244  
 through first phalanx, 247  
 general considerations, 244  
 index and little fingers, 249  
 of a metacarpal bone, 250  
 at metacarpo-phalangeal joint, 247  
 after-treatment, 249  
 removal of head, 249  
 through second phalanx, 246  
 fixation of tendons in, 247  
 of terminal phalanx, 244  
 after-treatment, 246  
 of septic cases, 246  
 thumb, of the, 252  
 at metacarpo-phalangeal joint, 253  
 of first metacarpal bone, 253  
 of terminal phalanx, 253  
 fore-arm, through the, 256  
 modified circular method, 256  
 hand, partial of, 252  
 humerus, through the, 259  
 scapula, removal of, 267  
 shoulder joint, at, 260  
 operation by deltoid flap, 262  
 control of hæmorrhage, 262  
 removal of entire joint, 263  
 Furneaux Jordan's, 264  
 lateral flaps, by, 263  
 Spence's, 260  
 wrist joint, at the, 254  
 after-treatment, 256
- Anæsthetics** in reduction of simple fracture, 5  
**Anatomical neck** of humerus, fracture of, 67  
 treatment, 72  
**Aneurism**, false in fracture, 37  
**Angular displacement** in fractures, 9  
**Apparatus retentive** for simple fractures, 9
- Arm**, amputations through the, 259  
**Artery**, injury to, in fractures, 36  
 subclavian, wound of, in fractured clavicle, 57  
**Arthrotomy** in acute osteitis with joint supuration, 181  
**Astragalus**, fracture of, 167  
**Axillary incision** in removal of scapula, 268
- BANDAGE** retractors in amputation, 227  
**Bandages** for simple fracture, 9  
 gauze and collodion, 239  
 silicate, 22  
 stump, application of, 240  
**Barker's operation** for fractured patella, 141  
**Bavarian splint**, 21  
**Bedsore**s in fractures, 46  
 prevention of in treatment of fracture of the femur, 110  
**Berger's method** of removing upper extremity, 264  
**Bladder**, injury to in fracture of pelvis, 103  
**Blisters** in chronic inflammation of bones, 183  
**Block-tin splints** for fractures, 11  
**Blood-clot**, obliteration of cavity by after-sequestrotomy, 189  
**Bone abscess**, in tuberculous disease, 200, 201  
 chronic, 182  
**Bone-grafting** in acute osteo-myelitis, 178  
 in non-union of fractures, 54  
**Bone marrow**, in osteitis deformans, 218  
 in osteomalacia, 217  
**Bones**, acute inflammation of, 170  
 acute non-suppurative osteitis, 171  
 suppurative osteitis, 171  
 treatment of various conditions, 174  
 acute epiphysitis, 179  
 combined with acute arthritis, 181  
 acute suppurative osteitis of flat bones, 181  
 osteo-myelitis, 175  
 periostitis, 174  
 periostitis and osteo-myelitis following injury, 181  
 caseating deposits in, treatment, 199  
 chronic inflammation of, 182  
 symptoms of, 183  
 treatment of, 183  
 operative, 183  
 abscess, drainage of, 184  
 after-treatment, 184  
 amputation in, 185  
 gouging of bone in, 183  
 in old subjects, 185  
 periosteum, removal of, 183  
 palliative, 183  
 diseases of, 171  
 acromegaly, 218  
 actinomycosis, 219  
 acute and chronic inflammations, 170  
 leontiasis ossium, 218  
 necrosis, 186  
 osteitis deformans, 217  
 osteomalacia, 217  
 rickets, 207  
 syphilitic and rheumatic, 203

- Bones  
 diseases of  
   tuberculous, 196  
   tumours, 219  
 gummata of, 204  
 hereditary syphilitic affections of, 205  
 methods of fixing after fracture, 51, 52  
 necrosis of, 186  
 rheumatic affections of, 205  
 surgical diseases of, 171  
   injuries of, 1  
   syphilis of, 203  
   syphilitic caries of, 204  
   tuberculous disease of, 196 (*see* Tuberculous)  
   tumours of, 219  
 "Box splint" for simple fracture of tibia, 151  
 Brachial plexus, pressure on in fracture of clavicle, 57  
 Brachialis anticus, ossification of, 91  
 Bryant's double splint, 125  
   vertical extension for fractured femur, 26, 124  
 Butcher's osteoclast, 47
- CALLUS as cause of non-union of fractures, 48  
 formation of in simple fractures, 4  
 inclusion of nerves in, 55  
   treatment of in fracture of the humerus, 76  
 removal of in fractures of fore-arm, 96  
 Carbolic acid, undiluted, in compound fractures, 32  
 Carden's amputation, 286  
 Caries, tuberculous, 197  
   syphilitic, 204  
 Carpal bones, fractures of, 101  
 Carr's splint for Colles' fracture, 99  
 Cartilage articular of femur, detachment of, 133  
   epiphyseal, destruction of, 179  
 Caseating deposits in bones, treatment of, 199  
 Catgut for obliterating cavity after sequestrotomy, 189  
 Chloral in delirium tremens, 45  
 Chopart's amputation, 273  
 Chondroma of bone, treatment of, 220  
 Chronic abscess of bone, 182  
   inflammation of bone, 182  
 Cicatrix, adherent as cause of faulty stump, 242  
   position of in amputation, 223  
 Circular method of amputation, 224  
 Clavicle, fractures of the, 56  
   acromial end, 56  
   treatment, 61  
   complications of, 57  
   compound, 62  
   greenstick, 62  
   ordinary form, treatment of, 57  
   handkerchief method, 57, 58  
   recumbency in, 57  
   Sayre's method, 59  
   sternal end, treatment of, 56  
 "Cloacæ," 186  
 Clothing for ricketty children, 210  
 Coccydynia, 107  
 Coccyx, fracture of, causes and treatment, 107
- Cod-liver oil in rickets, 210  
 in tuberculous disease of hones, 198  
 Colles' fracture, causes, 97  
   displacement, 97  
   treatment, 98  
   after-treatment, 99  
   of mal-union, 99  
 Complicated fracture, definition of, 3  
   treatment of, 36  
 Complications during progress of fracture, 41  
   immediate in fractures, 36  
 Compound fracture, definition of, 2  
   treatment of, 31  
   of clavicle, 62  
   fibula, 160  
   os calcis, 168  
   shaft of tibia, 153  
   tibia and fibula, 165  
 Condyles of femur, fracture of, 131  
   of humerus, fractures of, 78  
   treatment of, 80  
 Condy's fluid in phosphorus necrosis, 194  
 Conical stump, causes and treatment, 243  
 Coracoid process of scapula, fracture of, 63  
   wiring of, 65  
 Coronoid process, fracture of, causes, 90  
   ossification of brachialis anticus in, 91  
   removal of spur-like process of, 91  
 Corrigan's cauterly in chronic osteitis, 183  
   in rheumatic osteitis, 205  
 Counter-extension in simple fracture, 5, 6  
 Counter-irritation in rheumatic periostitis and osteitis, 205
- Croft's splints, 14  
   advantages of, 18  
   antero-posterior, 19  
   lateral, 14, 15  
   methods of strengthening, 20  
   precautions in applying, 18  
   shaping pattern for, 14
- DACTYLITIS strumous, treatment, 201  
 Davy's lever, 292  
 Deal splints for simple fractures, 10  
 Decalcified bone-grafting after sequestrotomy, 189, 190  
 Delirium tremens in fracture, treatment of, 45  
 Deltoid flap amputation through the shoulder, 262  
 Diet in treatment of rickets, 208, 209  
 Dislocation complicating fracture, 39  
 Drainage of stump after amputation, 238  
 Dupuytren's fracture, causes and treatment of, 162  
   splint in Dupuytren's fracture, 163  
   in Pott's fracture, 157, 160
- ELBOW, flexion of in fractures of humerus, 78  
 Elbow joint, amputation through the, 257  
 Emboli fatty, in after fracture, 41  
 Embolism in acute suppurative osteitis, 173  
   fatty complicating fracture, 40  
 Endocarditis, ulcerative, in acute suppurative osteitis, 173  
 Epiphyseal cartilage, destruction of, 179  
   enlargements in rickets, 208

- Epiphysis, separation of, 3  
 of femur, lower, 132  
 humerus, lower, 77  
   upper, 67  
 tibia, upper, 150  
 radius, lower, 100  
   upper, 91
- Epiphysitis, acute, 172  
 treatment, 179  
 amputation in, 180  
 of arrest of growth after, 179  
 destruction of healthy epiphyseal  
 cartilage, 179  
 resection of portions of unaffected  
 bone, 180
- Esmarch's bandage in sequestrotomy, 187  
 in amputations, 233  
 tubing in amputation through hip,  
 291
- Exostoses, treatment, 219
- Extension in simple fracture, 23  
 arrangement of bed in, 26  
 and counter-extension, 5, 6  
 splint, 26  
 vertical, 26  
 weight, 23  
 in fracture of surgical neck of humerus,  
 70  
 in unimpacted extra-capsular fracture of  
 femur, 116  
 in ununited fracture, 50
- Extra-capsular fracture of femur, 115
- FARABEUF'S sub-astragaloid amputation, 274
- Femoral artery, rupture of in supra-condyloid  
 fracture of femur, 129
- Femur, articular cartilage, detachment of, 158  
 amputation through shaft of, 287  
 control of circulation in, 288  
 prevention of shock in, 289  
 extra-capsular fracture of, 115  
 fractures of, 109  
 of lower end of, 129  
 of condyles, 131  
 separation of epiphysis, 132  
 supra-condyloid, 129  
 T-shaped, 131  
 of shaft of, 119  
 treatment of, 120  
 compound fracture, 129  
 fracture just below trochanters,  
 120  
 fracture near centre of shaft,  
 122  
   in adults, 122  
   children, 124  
   mal-union, 126  
   non-union, 127  
 of upper end, 109  
 extra-capsular, 115  
 treatment of, 116  
   impacted form, 118  
   unimpacted form, 116  
     after-treatment, 118  
 intra-capsular, 109  
 treatment of, 110  
   in young adults, 110  
   impacted form, 113
- Femur  
 fractures of  
   intra-capsular  
     treatment of  
       in young adults  
         unimpacted form, 110  
         after-treatment, 112  
       in elderly subjects, 113  
         palliative, 113  
         operative, 115  
     of great trochanter of, 119  
   intracapsular fracture of, 109  
   supra-condyloid fracture of, 129  
   tuberculous disease of, excision of abscess  
     in, 201
- Fibula, fractures of, 155  
 compound, 160  
 of lower end, 155  
   Dupuytren's, 162  
   Pott's, 155  
     without dislocation, 162  
 mal-union, operation for, 161  
 of shaft, treatment of, 155
- Fibula and tibia, fractures of both, 163
- Finger, index, amputation of, 249  
 little, amputation of, 249
- Fingers, amputations of (*see* Amputa-  
 tions), 244
- Flap method of amputation, 228
- Flaps in amputation, cutting of, 235  
 raising of, 235  
 stitching of, 237
- "Foetal rickets," 207
- Fore-arm, amputations through the (*see*  
 Amputations), 256  
 fractures of the, 82  
   in lower third, 97  
   both bones, 100  
   in middle, 92  
     both bones, 94  
   of olecranon, 82  
   radius alone, 93  
   ulna alone, 92
- Foreign bodies as cause of non-union of  
 fractures, 49
- Foot, amputations of (*see* Amputations), 272  
 fractures of bones of, 167  
   astragalus, 167  
   metatarsal bones, 169  
   os calcis, 168  
   tarsal bones, 168
- Foot and leg, fractures of, 149
- "Foot knife," 277
- "Fracture boards," 26
- "Fracture box," 151
- Fracture "setting" of a, 5
- Fractures, causes of and definition of, 1  
 classification of, 2  
 comminuted, 3  
 compound, definition of, 2  
   aseptic, repair in, 4  
   delay of union in, 36  
   treatment of, 31  
     after treatment in aseptic, 33  
     amputation in, 34  
     disinfection of limb in, 32  
     septic cases, 34  
     repair in, 4

## Fractures

- compound
  - treatment of
    - splints in, 33
    - when damage is extreme, 35
    - when there is necrosis, 35
    - when wound is considerable, 32
    - when wound is very small, 33
- complicated, definition of, 3
- treatment of, 36
- complications, during progress of case, 41
  - adhesion of muscles and tendons to fractured ends, 55
  - bed-sores, 46
  - delirium tremens, 45
  - gangrene, 43
  - hypostatic pneumonia, 43
  - inclusion of nerve in callus, 55
  - mal-union, 46
  - necrosis, 46
  - non-union, 48
  - oedema, 41
    - of lungs, 43
  - pruritis, 41
  - sepsis, 43
  - thrombosis, 42
  - vesication, 41
- complications, immediate, 36
  - dislocation, 39
  - false aneurism, 37
  - fatty embolism, 40
  - injury to main artery, 36
    - to main nerve, 38
    - to main vein, 38
    - to viscera, 38
  - wounds of joints, 39
    - of skin, 36
- delay in union of, 48
- displacements in, 3
- formation of false joint in ununited, 48
- general considerations, 1
- greenstick, 3
- impacted, 3
- of the individual bones, 56
  - acetabulum, 105
  - carpal bones, 101
  - clavicle, 56
  - coccyx, 107
  - Colles's, 97
  - coronoid process, 90
  - femur, 109
    - great trochanter, 119
    - lower end, 129
    - shaft, 119
    - upper end, 109
  - fibula, 155
    - Dupuytren's fracture, 162
    - Pott's fracture, 155
  - foot, bones of the, 167
  - fore-arm, bones of the, 82
    - both bones at middle, 94
    - at lower third, 97
    - at middle, 92
    - olecranon, 82
    - radius alone, 93
    - ulna alone, 92

## Fractures

- of the individual bones
  - hand, bones of the, 101
    - carpal bones, 101
    - metacarpal bones, 101
    - phalanges, 102
  - humerus, 66
    - lower end, 77
    - shaft, 74
    - upper end, 66
  - ilium, 104
  - ischium, 105
  - leg, bones of the, 149
    - both bones, 163
    - fibula alone, 155
    - tibia alone, 149
  - metacarpal bones, 101
  - olecranon, 82
  - patella, 134
  - pelvis, 103
    - as a whole, 103
    - of individual bones, 104
  - phalanges, 102
  - radius, 93
  - sacrum, 106
  - scapula, 63
  - tibia, 149
  - ulna alone, 92
- mal-union, causes and treatment of, 46
  - multiple, 3
  - non-union of, 48
  - oblique, 3
  - pathological changes in, 4
  - repair, process of, 4
  - separation of epiphysis, 33
  - simple, 2
    - treatment of, 5
      - after-treatment, 28
        - where massage is relied on, 29
        - where splints are employed, 28
- bandages in, 9
  - silicate, 22
- combination of splints with massage, 30
- extension and counter-extension in, 5, 6, 23
- fixation of fragments in, 26, 27
- operative interference in, 27
- passive movements in, 30, 31
- plaster casing for, 22
- reduction and coaptation of, 5
  - advantages of early, 7
  - division of tendons after, 9
  - maintenance of, 9
  - obstacles to, 6
  - position after, 8
  - time for effecting, 7
- retentive apparatus for, 9
- splints for, 9-21
  - Bavarian, 21
  - block-tin, 11
  - Croft's, 16
  - general rules for, 9, 10
  - Gooch's, 11
  - wire-netting, 11
- strapping in, 9

- Fractures**  
 simple  
   wiring in, 28  
   spiral, 3  
   transverse, 3  
**Fragilitas ossium** as cause of fracture, 2  
**Furieux** Jordan's amputation through hip joint, 291  
   through shoulder joint, 264
- GANGRENE**, treatment of in fracture, 43  
**Gooch's splinting**, 11  
**Greenstick fracture**, 3  
   of clavicle, treatment of, 62  
   of ulna and radius, treatment of, 95  
**Growing pains**, 170  
**Gummatous disease of bones**, treatment of, 204  
**Guttapercha** for splints, 12
- HÆMORRHAGE**, arrest of in amputations, 233  
   Esmarch's method, 233  
   Lister's method, 233  
     material for and seat of tourniquet, 234  
**Hand**, amputation of the, 254  
   partial, 252  
**Hand**, fractures of the bones of the, 82, 101  
   of carpal bones, 101  
   metacarpal bones, 101  
   phalanges, 102  
**Handkerchief method** for fractured clavicle, 57, 58  
**Hereditary syphilis** of bone, 205  
**Hip joint**, amputations through (*see* Amputations), 290  
**Hodgen's splint**, in fractures of shaft of femur, 121, 123  
   in supra-condyloid fracture of femur, 130  
**"Hooded flap,"** 232  
**Humerus**, amputations through the, 259  
   anatomical neck, fracture of, 67  
   condyles, fracture of, 78  
   fractures of, 66  
     of lower end varieties, 77  
       treatment, 78-81  
     condyles, 78  
     either condyle alone, 80  
     internal epi-condyle, 78  
       treatment, 81  
     separation of epiphysis, 77  
     supra-condyloid, 77  
       treatment of, 78  
   T-shaped, 77  
     operation for, 79  
   of shaft, causes and displacements in, 74  
     complications, 74  
     treatment of, 74  
       of injury to musculo-spiral nerve, 76  
   of upper end, 66  
     of anatomical neck, 67  
       treatment of, 72  
     combined with dislocation, 73, 74  
     epiphysis, separation of, 67  
       treatment, 73  
     great tuberosity, separation of, 67  
       treatment, 7
- Humerus**, fractures of  
   upper end  
     of surgical neck displacements, 66  
       complicated with dislocation, 67  
       treatment of, 67  
       after-treatment, 70  
     separation of lower epiphysis of, 77  
       of upper epiphysis of, 67  
     supra-condyloid fracture of, 77  
     surgical neck, fracture of, 66  
     T-shaped fracture of, 77
- ICEBAG** in treatment of fractures, 42, 88  
**Ilium**, fracture of the, 104  
**Impacted fracture**, 3  
**Index finger**, amputation of, 249  
**Inflammation of bones**, acute (*see* Bones), 170  
   chronic, 182  
**Injections** in ununited fractures, 50  
**Insanity** as cause of fracture, 2  
**Intra-capsular fracture** of femur, 109  
**Iodide of iron**, in bone tuberculosis, 198  
   of potassium in chronic osteitis, 183  
   in gummatous disease of bone, 204  
   in rheumatic periostitis and osteitis, 205  
**Ischium**, fracture of, 105  
**Ivory exostoses**, treatment of, 220  
   pegs for fixing bones after fracture, 52
- JOINTS**, wounds of complicating fractures, 39
- KNEE JOINT**, amputations about the (*see* Amputations), 283
- LEATHER splints**, 12  
**Leg**, amputation through the (*see* Amputations), 280  
   fractures of, 149  
     both bones, 163  
     fibula alone, 155  
     tibia alone, 149  
**Leontiasis ossium**, 218  
**Lisfranc's operation**, 273  
**Lister's amputation** at knee, 286  
   through the leg, 280  
**Lister's method** of arresting hæmorrhage in amputations, 233  
   tourniquet in amputations through hip joint, 292  
**Liston's splint** in simple fracture, 26  
   in fractures of femur, 111  
     impacted extra-capsular, 118  
     of shaft, 127
- Locomotor ataxia** as cause of fracture, 2  
**Lower extremity**, amputation in the (*see* Amputations), 271  
**Lung**, wound of in fracture of clavicle, 57
- MACINTYRE'S splint** in fracture of femur, 120, 130, 131  
   in fracture of tibia, compound, 151, 153  
**Malgaigne's hooks**, 141  
**Mal-union** after fracture, 46  
   after Colles' fracture, 99  
     fracture of femur, 126  
     fracture of fore-arm, 96  
     Pott's fracture, 161  
**Manipulations** in treatment of fractures, 5

- Massage after union of fractures, 48  
   in treatment of simple fracture, 29  
 Mercury in gummatous disease of bone, 204  
 Metacarpal bone, amputation of, 250  
   importance of retaining head of, 247  
   removal of head of, 249  
 Metacarpal bones, fractures of, 101  
 Metacarpo-phalangeal joint, amputation at, 247  
 Metatarsal bones, fractures of, 169  
   removal of, 271  
 Mollities ossium as cause of fracture, 2  
 Multiple fractures, 3  
 Muscles, adhesion of in fracture, 55  
   condition of in fracture, 4  
 Musculo-spiral nerve, injury to in fracture of humerus, 74  
   treatment of, 76  
 Myeloid sarcomata of bone, treatment of, 221
- NECROSIS** of bone, 172, 186  
   acute, 172  
     amputation in, 181  
     after acute suppurative osteitis, 172  
     after fracture, treatment of, 35, 46  
     phosphorus necrosis, 194  
     sequestrum, characters of, 186  
     separation of, 186  
   treatment of, 187  
     amputation, 193  
     sequestrotomy, 187  
       circulation, control of, 187  
       incision in, 187  
       obliteration of cavity, 188  
       in an aseptic wound, 189  
         after-treatment, 191  
       in a septic wound, 191  
         after-treatment, 192  
 Nerve, injury to, complicating fracture, 38  
   "Neuralgic osteitis," treatment of, 206  
 Non-union of fractures, 48  
   of bones of fore-arm, 96  
     leg, 166  
     femur, treatment of, 127  
     olecranon, 88  
     patella, 144  
     tibia alone, 154
- CEDEMA**, complicating fracture, 41  
   of lungs, treatment of, 43, 44  
 Olecranon, fractures of the, 82  
   treatment, 83  
   of old cases, 88  
     after-treatment, 90  
     triceps, lengthening of, 88  
   operative, 83  
     after-treatment, 87  
     choice of cases, 87  
   palliative, 87  
     after-treatment, 88  
   recent cases, 83  
   where suppuration has occurred, 90
- OÖPHORECTOMY** in osteo-malacia, 217  
 Opium in delirium tremens, 45  
 Os calcis, fracture of, 168  
 Ossification of brachialis anticus in fracture of coronoid process, 91
- Ossification of brachialis anticus in repair of fractures, 4  
 Osteitis, acute non-suppurative, treatment of, 171  
   acute suppurative, causes, 171  
   causes of death in, 173  
   necrosis after, 172  
   pathological changes in, 172  
   results of, 173  
   seat of inflammation in, 171  
   separation of sequestrum in, 172  
   symptoms of, 173  
   treatment of, 174  
     of flat bones, 181  
     with joint suppuration, 180  
   deformans, symptoms and treatment of, 218  
   neuralgic, treatment of, 206  
   rarefying, 182  
     in tertiary syphilis of bone, 204  
   "Osteochondritis," 205  
 Osteo-malacia, 217  
 Osteo-myelitis, acute suppurative, 171  
   treatment of, 175  
     amputation in, 177  
     bone-grafting in, 178  
       complications, 176  
     diaphysis, resection of, 177  
     osteotomy in, 175  
       after-treatment, 176  
   as cause of necrosis, 186  
   chronic, pathological changes in, 182  
   of flat bones, treatment of, 181  
   tuberculous, 197  
   with periostitis after an open wound, 181  
 Osteo-sarcomata, treatment of, 220  
 Osteotomy for acute osteo-myelitis, 175, 181  
 Oxygen, in fatty embolism, 41
- PADDINGTON GREEN** Children's Hospital  
   dietary for infants, 214  
   rickets, 209  
 Passive movements in simple fracture, 30, 31  
   "Pasteurisation" of milk, 212  
 Patella, fractures of, causes, 134  
   varieties of, 134  
     comminuted, 147  
     compound, 148  
     longitudinal, 134  
     starred or comminuted, 147  
     transverse, 134  
       treatment of long-standing cases, 144  
       after-treatment, 147  
       secondary suture of, 145  
       treatment of recent cases, 135  
       operative, 135  
       after-treatment, 140  
       palliative, 142  
       after-treatment, 144  
       vertical, 148  
   Patella, secondary suture of, 145  
 Pegging in unimpacted extra-capsular fracture of femur, 118  
 Pelvic girdle, fracture of, 103  
 Pelvis, fractures of, 103  
   as a whole, 103

- Pelvis. fractures of  
of individual bones, 104  
acetabulum, 105  
ilium, 104  
ischium, 105
- Periosteal sarcomata, treatment of, 220
- Periosteum, removal of in chronic osteitis, 183
- Periostitis as cause of necrosis, 186  
acute suppurative, 174  
albuminous, 171  
chronic, 182  
rheumatic with osteitis, 205  
tuberculous, 197  
with acute traumatic osteo-myelitis, 181
- Phalanges, fractures of in hand, 102
- Phalanx, amputation through first, 247  
through second, 246  
of terminal, 244
- Phosphates, syrup of, in rickets, 210.
- Phosphorus in osteo-malacia, 217  
in rickets, 210
- Phosphorus necrosis, 194  
" Pigeon breast," 208
- Pirogoff's amputation, 279
- Plaster casing, 22
- Plaster of Paris, method of mixing, 16  
method of obliterating cavity after seques-  
troctomy, 190  
spica, 114  
splints, 14  
Bavarian, 21  
Croft's, 14  
permanent casing, 22
- Pleura, wound of, in fracture of clavicle, 57
- Pneumonia, hypostatic in fracture, 43
- Poroplastic material for splints, 12
- Potassium, iodide of, in chronic osteitis, 183  
in gummatous disease of bone, 204  
in rheumatic periostitis and osteitis, 205
- Pott's fracture, 155  
complications of, 155  
treatment of, 156  
compound, 160  
of mal-union, 161  
simple, 156  
after-treatment, 157
- Pruritis complicating fracture, 41
- Pyæmia in acute osteo-myelitis, 176  
after acute suppurative osteitis, 173
- " QUIET necrosis," treatment of, 193
- " RACIITIS adolescentium," 207
- " Racket incisions," 231
- " Racket " method of amputation, 231
- Radius, dislocation of complicating fracture  
of ulna, 92  
fracture of, alone, 91, 93, 94, 97, 100.  
of head and neck, 91  
separation of upper epiphysis, 92  
of lower third, 97  
Colles' fracture, 97  
treatment of, 98  
after-treatment, 99  
of mal-union, 99  
separation of lower epiphysis, 100
- Radius  
fracture of  
of middle of, 93  
treatment of, 94  
when fracture is above in-  
sertion of pronator, 94  
when below insertion of  
pronator teres, 94
- Radius and ulna, fracture at lower third, 100  
fracture at middle, 94  
causes of, and displacement in, 94  
treatment in, 94  
callus, removal of, 96  
greenstick fractures, 95  
mal-union, 96  
non-union, avoidance of, 94  
of ununited fracture, 96
- " Rarefying osteitis," 182, 204
- Recumbency in fracture of clavicle, 57
- Re-fracture in mal-union of fracture, 47
- Retractors for circular amputations, 226, 228
- Rheumatic periostitis and osteitis, 205
- Rib, tuberculous, excision of abscess in, 200
- Rickets, as a cause of fracture, 2  
as cause of non-union of fractures, 49  
deformities in, 208  
pathological changes in, 208  
treatment of, 208  
clothing, 210  
diet at different ages, 208, 209  
hygiene, 209  
drugs, 210  
sea-water baths, 211  
surgical, 211
- " fatal," 207
- scurvy-rickets, etiology, 212  
pathological changes and symptoms,  
213  
treatment, 213  
curative, 215  
prophylactic, 213
- " Ricketty rosary," 208
- Riding and overlapping in fractures, 3
- Röntgen rays in fractures, 28
- Rotation of fragments in fractures, 3
- Round-celled sarcoma of bone, 221
- Rugines, 226
- SACRUM, fracture of, 106
- Salicin in chronic osteitis, 183
- Salicylate of soda in chronic osteitis, 183  
in rheumatic periostitis and osteitis, 205
- Sanitas in phosphorus necrosis, 194
- Sarcoma of bone, treatment of, 220  
myeloid, treatment of, 221
- Sayre's method for fracture of clavicle, 59
- Scapula, acute osteo-myelitis of, treatment  
of, 182  
fractures of, symptoms, 63  
treatment, 64  
wiring coracoid process to, 65  
varieties of, 63  
of acromion process, 63  
treatment, 64  
of coracoid process, 63  
treatment, 65  
of body, 63  
treatment, 64

- Scapula  
fractures of  
varieties of  
of neck, anatomical, 63  
surgical, 63  
removal of, 267
- Scurvy-rickets, etiology, 212  
pathological changes and symptoms, 213  
treatment, 213  
curative, 215  
prophylactic, 213
- "Seat of election," amputation of leg at, 282
- Sea-water baths for rickets, 211
- Secondary syphilis of bones, 203
- Separation of epiphysis, 3
- Sepsis complicating fracture, 43
- Septic compound fractures, repair in, 4
- Septicæmia, acute following osteitis, 173  
complicating acute osteo-myelitis, 177
- Sequestrotomy for necrosis, 187
- Sequestrum, characters of a, 186  
separation of in acute osteitis, 172  
phosphorus, 194  
syphilitic, characters, 204  
tuberculous, 197  
removal of, 199
- Shock, prevention of in amputations, 234
- Shoulder-cap, in fractures of humerus, shaft, 75  
surgical neck, 68
- Shoulder joint, amputation at (*see* Amputations), 260
- Silicate bandage for fractures, 22
- Simple fracture (*see* Fractures, simple), 2
- Sinuses, excision of in tuberculous bones, 201
- Skiagraphy for fractures, 28
- Skin, wound of complicating fracture, 36
- Skull, acute osteo-myelitis of, 181
- Soda, salicylate of in rheumatic osteitis, 205
- Spence's amputation at shoulder joint, 260
- Spica, elastic in hip amputations, 289  
plaster of Paris, 114
- Spindle-celled sarcoma of bone, 221
- Splint extension in simple fracture, 26
- Splints, Bavarian, 21  
for compound fractures, 33  
septic cases, 34
- Croft's, 14  
advantages of, 18  
precautions in applying, 18
- guttapercha, 12  
leather, 12  
for mal-union, 46  
for non-union, 54  
Liston's, 26  
plaster of Paris, 13  
poroplastic, 12  
for rickets, employment of, 211  
for simple fracture, 9  
general rules for, 9, 10  
fastening, method of, 13  
materials for, 10  
padding of, 12
- Sponge-grafting after sequestrotomy, 189
- Spongy exostoses, treatment of, 220
- Stephen Smith's amputation at the knee, 284
- Sterilised milks in rickets, 212
- Sternal end of clavicle, fracture of, 56  
treatment, 61
- Stokes-Gritti amputation at the knee, 287
- Strapping in treatment of simple fracture, 9
- Strumous dactylitis, excision of bone abscess in, 201
- Stump bandage, 239
- Stump, conical, 243  
support to after amputations, 239
- Stumps, faulty, cause of, 242  
adherent cicatrix, 242  
conical stump, 243
- Styloid process of ulna, fracture of, 100
- Sub-astragaloid amputation of foot, 274
- Surgical neck of humerus, fractures of, 66
- Supra-condyloid fracture, of femur, 129  
of humerus, 77
- Syme's amputation, 276  
horse-hoe splint, 159
- "Syme's knife," 277
- Syphilis, as cause of necrosis, 186  
of bone, 203  
hereditary, 205  
secondary, 203  
tertiary, 204
- Syphilitic caries, 204
- TARSAL bones, fractures of, 168
- Teale's amputation, 283
- Tendons, adhesion of in fractures, 55  
division of after reduction of simple fracture, 9  
fixation of in finger amputations, 247  
flexor, retention of in partial amputations of hand, 252
- Tertiary syphilis of bones, 204
- Thomas's hip splint, in fractures of femur, in old subjects, 114  
in unimpacted extra-capsular fracture, 118  
in ununited fracture of shaft, 128  
in young adults, 113
- Thomas's knee splint in ununited fracture of femur, 128
- Thrombosis complicating fracture, 42
- Thumb, amputations of the, 252
- Thyroid extract in osteitis deformans, 218
- Tibia, fractures of, 149  
of lower end, 154  
of shaft, 150  
comminuted, 152  
compound, treatment of, 153  
after-treatment, 154  
simple, 150  
treatment of, 151  
ununited, 154  
of upper end, treatment of, 149  
compression fracture, 149  
transverse fracture, 150  
separation of epiphysis, 150  
when spine is broken off, 150  
separation of epiphysis of, 150
- Tibia and fibula, fractures of both, 163  
causes of and displacement in, 163  
treatment, 163  
various forms, 163  
compound, treatment of, 165  
simple, treatment of, 163  
oblique fractures, 164  
ununited, 166



- Toes, amputations of, 271  
 removal of metatarsal bones, 271
- Tourniquet, Lister's in hip amputations, 292  
 material for in amputations, 234
- Transfixion, advantages of flap amputation  
 over, 229
- Triceps, lengthening of, 88
- Trochanter, fracture of great, 119
- T-shaped fracture, of femur, 131  
 of humerus, 77
- Tuberculous disease of bones, 196  
 clinical stages, 197  
 treatment, 198  
 cases unaccompanied by chronic  
 abscess, 198  
 cases with an unopened abscess,  
 200  
 cases where there are septic sinuses,  
 201  
 varieties of, 196  
 osteo-myelitis, 197  
 periostitis, 197  
 sequestra in bone, 197
- Tuberosity of humerus, separation of, 67  
 treatment of, 73
- Tumours of bones, 219  
 primary, treatment of, 219  
 chondroma, 220  
 exostosis, 219  
 sarcoma, 220  
 secondary, treatment of, 221
- ULNA, fracture of, complicated by dislocation  
 of radius, 92  
 fracture of, in lower third, 97  
 at middle of fore-arm, 92  
 of styloid process, 100
- Ulna and radius, fracture of both in lower  
 third, 100  
 fracture at middle of, 94  
 causes of, 94  
 treatment of, 94  
 greenstick fractures, 95  
 mal-union, 96  
 non-union, avoidance of, 94  
 ununited fracture, 96
- Ununited fracture of both bones of leg, 166  
 of shaft of tibia, 154  
 of ulna and radius, 96
- Urethra, laceration of, in fractures of pelvis,  
 103
- VEIN, injury to, in fracture, 38
- Vertical extension in fracture, 26
- Vesication complicating fracture, 41
- Viscera, injury to, in fracture, 38
- WEIGHT extension in simple fracture, 3
- Wire-netting splint for fractures, 11
- Wiring simple fractures, 28, 52
- Wrist joint, amputation at the, 254
- ZINC, phosphate of, in osteo-malacia, 217







A LIST OF WORKS ON  
MEDICINE, SURGERY,  
AND  
GENERAL SCIENCE,  
PUBLISHED BY  
**LONGMANS, GREEN & CO.**  
39 PATERNOSTER ROW LONDON, E.C.  
91 AND 93 FIFTH AVENUE, NEW YORK, AND 32 HORNBY ROAD, BOMBA'

*Medical and Surgical Works.*

—

**ASHBY.**—*WORKS* by **HENRY ASHBY, M.D. Lond., F.R.C.P.,**  
*Physician to the General Hospital for Sick Children, Manchester; formerly Demonstrator of Physiology, Liverpool School of Medicine.*

**NOTES ON PHYSIOLOGY FOR THE USE OF STUDENTS PREPARING FOR EXAMINATION.** Sixth Edition, thoroughly revised. With 141 Illustrations. 18mo, price 5s.

**HEALTH IN THE NURSERY** With 25 Illustrations. Crown 8vo. 3s. 6d.

—

**ASHBY AND WRIGHT. THE DISEASES OF CHILDREN, MEDICAL AND SURGICAL.** By **HENRY ASHBY, M.D. Lond., F.R.C.P.,** Physician to the General Hospital for Sick Children, Manchester; Lecturer and Examiner in Diseases of Children in the Victoria University; and **G. A. WRIGHT, B.A., M.B. Oxon., F.R.C.S. Eng.,** Assistant Surgeon to the Manchester Royal Infirmary and Surgeon to the Children's Hospital; formerly Examiner in Surgery in the University of Oxford. Enlarged and Improved Edition. With 192 Illustrations. 8vo, price 25s.

—

**BENNETT.**—*WORKS* by **WILLIAM H. BENNETT, F.R.C.S.,**  
*Surgeon to St. George's Hospital; Member of the Board of Examiners, Royal College of Surgeons of England.*

**CLINICAL LECTURES ON VARICOSE VEINS OF THE LOWER EXTREMITIES.** With 3 Plates. 8vo. 6s.

**ON VARICOCELE: A PRACTICAL TREATISE.** With 4 Tables and a Diagram. 8vo. 5s.

**CLINICAL LECTURES ON ABDOMINAL HERNIA:** chiefly in relation to Treatment, including the Radical Cure. With 12 Diagrams in the Text. 8vo. 8s. 6d.

**ON VARIX, ITS CAUSES AND TREATMENT, WITH ESPECIAL REFERENCE TO THROMBOSIS:** an Address delivered at the Inaugural Meeting of the Nottingham Medico-Chirurgical Society, Session 1898—9. 8vo. 3s. 6d.

**BENTLEY.** A TEXT-BOOK OF ORGANIC MATERIA MEDICA. Comprising a Description of the Vegetable and Animal Drugs of the British Pharmacopœia, with some others in common use. Arranged Systematically, and Especially Designed for Students. By ROBERT BENTLEY, M.R.C.S. Eng., F.L.S. With 62 Illustrations on Wood. Crown 8vo, price 7s. 6d.

**BRODIE.** THE ESSENTIALS OF EXPERIMENTAL PHYSIOLOGY. For the Use of Students. By T. G. BRODIE, M.D., Lecturer on Physiology, St. Thomas's Hospital Medical School. With 2 Plates and 177 Illustrations. 8vo. 6s. 6d.

**CABOT.** *WORKS* by RICHARD C. CABOT, M.D., Physician to Out-Patients, Massachusetts General Hospital.

A GUIDE TO THE CLINICAL EXAMINATION OF THE BLOOD FOR DIAGNOSTIC PURPOSES. With 3 Coloured Plates and 28 Illustrations in the Text. 8vo, 16s.

THE SERUM DIAGNOSIS OF DISEASE. With 31 Temperature Charts and 9 Illustrations. Royal 8vo, 7s. 6d.

**CELLI.** MALARIA ACCORDING TO THE NEW RESEARCHES. By Professor ANGELO CELLI, Director of the Institute of Hygiene, University of Rome. Translated by JOHN JOSEPH EYRE, M.R.C.P., L.R.C.S. Ire., D.P.H. Cambridge. With Corrections and Additions made for this Translation by the Author.

**CHEYNE AND BURGHARD.** A MANUAL OF SURGICAL TREATMENT. By W. WATSON CHEYNE, M.B., F.R.C.S., F.R.S., Professor of Surgery in King's College, London; Surgeon to King's College Hospital, and the Children's Hospital, Paddington Green, &c.; and F. F. BURGHARD, M.D. and M.S. (Lond.), F.R.C.S., Teacher of Practical Surgery in King's College, London; Surgeon to King's College Hospital, and the Children's Hospital, Paddington Green, &c.

#### PROPOSED DIVISION OF WORK.

- |   |   |
|---|---|
| <p><b>PART I.</b> The Treatment of General Surgical Diseases, including inflammation, suppuration, ulceration, gangrene, wounds and their complications, infective diseases and tumours; the administration of anæsthetics. With 66 Illustrations. Royal 8vo, 10s. 6d. [Ready.]</p> <p><b>PART II.</b> The treatment of the Surgical Affections of the tissues, including the skin and subcutaneous tissues, the nails, the lymphatic vessels and glands, the fasciæ, bursæ, muscles, tendons, and tendon-sheaths, nerves, arteries, and veins. Deformities. With 141 Illustrations. Royal 8vo. 14s. [Ready.]</p> | <p><b>PART III.</b> The treatment of the Surgical Affections of bones and joints, including fractures and dislocations, excisions and amputations. [In the Press.]</p> <p><b>PART IV.</b> The treatment of the Surgical Affections of the head, face, and neck; throat, nose, and ear. [In preparation.]</p> <p><b>PART V.</b> The treatment of the Surgical Affections of the thorax, breast, spine, and generative organs. [In preparation.]</p> <p><b>PART VI.</b> The treatment of the Surgical Affections of the alimentary and urinary systems. [In preparation.]</p> |
|---|---|

**CLARKE.**—*WORKS* by **J. JACKSON CLARKE, M.B. (Lond.),**  
*F.R.C.S., Assistant-Surgeon to the North-West London Hospital, Pathologist and Curator  
of the Museum at St. Mary's Hospital.*

**POST-MORTEM EXAMINATIONS IN MEDICO-LEGAL  
AND ORDINARY CASES.** With Special Chapters on the Legal  
Aspects of Post-Mortems, and on Certificates of Death. Fcp. 8vo, 2s. 6d.

**SURGICAL PATHOLOGY AND PRINCIPLES.** With 194  
Illustrations. Crown 8vo. 10s. 6d.

**COATS. A MANUAL OF PATHOLOGY.** By **JOSEPH COATS,**  
M.D., late Professor of Pathology in the University of Glasgow. Fourth  
Edition. Revised throughout and Edited by **LEWIS R. SUTHERLAND,**  
M.D., Professor of Pathology, University of St. Andrews. With 490 Illus-  
trations. 8vo, 31s. 6d.

\* \* \* A considerable portion of the work of revision necessary in the prepara-  
tion of a Fourth Edition of the above text-book had been already accomplished  
by the Author, Professor Joseph Coats, in the four months immediately pre-  
ceding his death. It is in response to his expressed wish that the editorial  
duties have been assumed by Dr. Lewis R. Sutherland.

**COOKE.**—*WORKS* by **THOMAS COOKE, F.R.C.S. Eng., B.A., B.Sc.,**  
*M.D. Paris, Senior Assistant Surgeon to the Westminster Hospital.*

**TABLETS OF ANATOMY.** Being a Synopsis of Demonstrations given  
in the Westminster Hospital Medical School. Eleventh Edition in Three  
Parts, thoroughly brought up to date, and with over 700 Illustrations from all  
the best sources, British and Foreign. Post 4to. Part I. The Bones, 7s. 6d.  
net; Part II. Limbs, Abdomen, Pelvis, 10s. 6d. net; Part III. Head and  
Neck, Thorax, Brain, 10s. 6d. net.

**APHORISMS IN APPLIED ANATOMY AND OPERATIVE  
SURGERY.** Including 100 Typical *viva voce* Questions on Surface  
Marking, &c. Crown 8vo, 3s. 6d.

**DISSECTION GUIDES.** Aiming at Extending and Facilitating such  
Practical Work in Anatomy as will be specially useful in connection with an  
ordinary Hospital Curriculum. 8vo, 10s. 6d.

**DAKIN. A MANUAL OF MIDWIFERY.** By **WILLIAM RAD-  
FORD DAKIN, M.D., F.R.C.P.,** Obstetrical Physician and Lecturer on  
Midwifery at St. George's Hospital, Examiner in Midwifery and Diseases of  
Women on the Conjoint Board of the Royal College of Physicians and  
Surgeons in England, &c. With 393 Illustrations. 8vo, 18s.

**DICKINSON.**—*WORKS* by **W. HOWSHIP DICKINSON, M.D.**  
*Cantab., F.R.C.P., Physician to, and Lecturer on Medicine at, St. George's Hospital;  
Consulting Physician to the Hospital for Sick Children.*

**ON RENAL AND URINARY AFFECTIONS.** Complete in Three  
Parts, 8vo, with 12 Plates and 122 Woodcuts. Price £3 4s. 6d.

**THE TONGUE AS AN INDICATION OF DISEASE;** being the  
Lumleian Lectures delivered at the Royal College of Physicians in March, 1888.  
8vo, price 7s. 6d.

**OCCASIONAL PAPERS ON MEDICAL SUBJECTS, 1855-1896.**  
8vo, 12s.

**THE HARVEIAN ORATION ON HARVEY IN ANCIENT  
AND MODERN MEDICINE.** Crown 8vo, 2s. 6d.

**MEDICINE, OLD AND NEW:** an Introductory Address delivered on  
the occasion of the Opening of the Winter Session, 1899-1900, at St. George's  
Hospital Medical School, on October 2, 1899. Crown 8vo, 2s. 6d.

**DUCKWORTH.**—*WORKS* by Sir **DYCE DUCKWORTH, M.D.**  
*LL.D., Fellow and Treasurer of the Royal College of Physicians, &c.*

**THE SEQUELS OF DISEASE:** being the Lumleian Lectures delivered in the Royal College of Physicians, 1896. Together with Observations on Prognosis in Disease. 8vo, 10s. 6d.

**THE INFLUENCE OF CHARACTER AND RIGHT JUDGMENT IN MEDICINE:** the Harveian Oration, delivered before the Royal College of Physicians, October 11, 1898. Post 4to, 2s. 6d.

**ERICHSEN.** **THE SCIENCE AND ART OF SURGERY: A TREATISE ON SURGICAL INJURIES, DISEASES, AND OPERATIONS.** By Sir **JOHN ERIC ERICHSEN, Bart., F.R.S., LL.D.** (Edin.), Hon. M. Ch. and F.R.C.S. (Ireland), late Surgeon Extraordinary to H.M. the Queen. Tenth Edition. Revised by the late **MARCUS BECK, M.S. & M.B. (Lond.), F.R.C.S.,** Surgeon to University College Hospital, and Professor of Surgery in University College, London; and by **RAYMOND JOHNSON, M.B. & B.S. (Lond.), F.R.C.S.,** Assistant Surgeon to University College Hospital, &c. Illustrated by nearly 1,000 Engravings on Wood. 2 Vols. royal 8vo, 48s.

**FOWLER AND GODLEE.** **THE DISEASES OF THE LUNGS.** By **JAMES KINGSTON FOWLER, M.A., M.D., F.R.C.P.,** Physician to the Middlesex Hospital, and to the Hospital for Consumption and Diseases of the Chest, Brompton; late Examiner in Medicine at the University of Cambridge, and on the Conjoint Examining Board in England; and **RICKMAN JOHN GODLEE, M.S., F.R.C.S.,** Fellow and Professor of Clinical Surgery, University College, London; Surgeon to University College Hospital and to the Hospital for Consumption and Diseases of the Chest, Brompton; Surgeon in Ordinary to Her Majesty's Household. With 160 Illustrations. 8vo, 25s.

**FRANKLAND.** **MICRO-ORGANISMS IN WATER, THEIR SIGNIFICANCE, IDENTIFICATION, AND REMOVAL.** Together with an Account of the Bacteriological Methods Involved in their Investigation. Specially Designed for the Use of those connected with the Sanitary Aspects of Water Supply. By Professor **PERCY FRANKLAND, Ph.D., B.Sc. (Lond.), F.R.S.,** Fellow of the Chemical Society; and Mrs. **PERCY FRANKLAND,** Joint Author of "Studies on Some New Micro-Organisms Obtained from Air." With 2 Plates and numerous Diagrams. 8vo. 16s. net.

**GARROD.**—*WORKS* by Sir **ALFRED BARING GARROD, M.D., F.R.S., &c.;** *Physician Extraordinary to H.M. the Queen; Consulting Physician to King's College Hospital; late Vice-President of the Royal College of Physicians.*

**A TREATISE ON GOUT AND RHEUMATIC GOUT (RHEUMATOID ARTHRITIS).** Third Edition, thoroughly revised and enlarged; with 6 Plates, comprising 21 Figures (14 Coloured), and 27 Illustrations engraved on Wood. 8vo, price 21s.

**THE ESSENTIALS OF MATERIA MEDICA AND THERAPEUTICS.** The Fourteenth Edition, revised and edited, under the supervision of the Author, by **NESTOR TIRARD, M.D. Lond., F.R.C.P.,** Professor of Materia Medica and Therapeutics in King's College, London, &c. Crown 8vo, price 12s. 6d.



**GRAY.** ANATOMY, DESCRIPTIVE AND SURGICAL. By HENRY GRAY, F.R.S., late Lecturer on Anatomy at St. George's Hospital. The Fourteenth Edition, re-edited by T. PICKERING PICK, Surgeon to St. George's Hospital; Inspector of Anatomy in England and Wales; late Member of the Court of Examiners, Royal College of Surgeons of England. With 705 large Woodcut Illustrations, a large proportion of which are Coloured, the Arteries being coloured red, the Veins blue, and the Nerves yellow. The attachments of the muscles to the bones, in the section on Osteology, are also shown in coloured outline. Royal 8vo, price 36s.

**HALLIBURTON.**—*WORKS* by W. D. HALLIBURTON, M.D., F.R.S., F.R.C.P., Professor of Physiology in King's College, London.

A TEXT-BOOK OF CHEMICAL PHYSIOLOGY AND PATHOLOGY. With 104 Illustrations. 8vo, 28s.

THE ESSENTIALS OF CHEMICAL PHYSIOLOGY. For the Use of Students. Third Edition. With 77 Illustrations. 8vo, 5s.

\* \* This book treats of the subject in the same way as Prof. SCHÄFER's "Essentials" treats of Histology. It contains a number of elementary and advanced practical lessons, followed in each case by a brief descriptive account of the facts related to the exercises which are intended to be performed by each member of the class.

**LANG.** THE METHODICAL EXAMINATION OF THE EYE. Being Part I. of a Guide to the Practice of Ophthalmology for Students and Practitioners. By WILLIAM LANG, F.R.C.S. Eng., Surgeon to the Royal London Ophthalmic Hospital, Moorfields, &c. With 15 Illustrations. Crown 8vo, 3s. 6d.

**LEUMANN.** NOTES ON MICRO ORGANISMS PATHOGENIC TO MAN. By SURGEON-CAPTAIN B. H. S. LEUMANN, M.B., Indian Medical Service. 8vo, 3s.

**LIVEING.** HANDBOOK ON DISEASES OF THE SKIN. With especial reference to Diagnosis and Treatment. By ROBERT LIVEING, M.A. & M.D. Cantab., F.R.C.P. Lond., &c., Physician to the Department for Diseases of the Skin at the Middlesex Hospital, &c. Fifth Edition, revised and enlarged. Fcap. 8vo, price 5s.

**LUFF.** TEXT BOOK OF FORENSIC MEDICINE AND TOXICOLOGY. By ARTHUR P. LUFF, M.D., B.Sc. (Lond.), Physician in Charge of Out-Patients and Lecturer on Medical Jurisprudence and Toxicology in St. Mary's Hospital; Examiner in Forensic Medicine in the University of London; External Examiner in Forensic Medicine in the Victoria University; Official Analyst to the Home Office. With numerous Illustrations. 2 vols., crown 8vo, 24s.

**MOORE.** ELEMENTARY PHYSIOLOGY By BENJAMIN MOORE, M.A. late Sharpey Research Scholar, and Assistant Professor of Physiology at University College, London. With 125 Illustrations. Crown 8vo, 3s. 6d.

**NEWMAN.** ON THE DISEASES OF THE KIDNEY AMENABLE TO SURGICAL TREATMENT. Lectures to Practitioners. By DAVID NEWMAN, M.D., Surgeon to the Western Infirmary Out-Door Department; Pathologist and Lecturer on Pathology at the Glasgow Royal Infirmary; Examiner in Pathology in the University of Glasgow; Vice-President Glasgow Pathological and Clinical Society. 8vo, price 8s.

**NOTTER AND FIRTH. HYGIENE.** By J. L. NOTTER, M.A., M.D., Fellow and Member of Council of the Sanitary Institute of Great Britain, Examiner in Hygiene, Science and Art Department, etc.; and R. H. FIRTH, F.R.C.S., Assistant Examiner in Hygiene, Science and Art Department. With 93 Illustrations. Crown 8vo, 3s. 6d.

**OWEN. A MANUAL OF ANATOMY FOR SENIOR STUDENTS.** By EDMUND OWEN, M.B., F.R.S.C., Senior Surgeon to the Hospital for Sick Children, Great Ormond Street, Surgeon to St. Mary's Hospital, London, and co-Lecturer on Surgery, late Lecturer on Anatomy in its Medical School. With 210 Illustrations. Crown 8vo, price 12s. 6d.

**PICK. SURGERY: A TREATISE FOR STUDENTS AND PRACTITIONERS.** By T. PICKERING PICK, Consulting Surgeon to St. George's Hospital; Senior Surgeon to the Victoria Hospital for Children; H.M. Inspector of Anatomy in England and Wales. With 441 Illustrations. Medium 8vo, 25s.

**POOLE. COOKERY FOR THE DIABETIC.** By W. H. and Mrs. POOLE. With Preface by Dr. PAVY. Fcap. 8vo, 2s. 6d.

**POORE.—WORKS by GEORGE VIVIAN POORE, M.D., F.R.C.P.**  
**ESSAYS ON RURAL HYGIENE.** Crown 8vo, 6s. 6d.  
**THE DWELLING HOUSE.** With 36 Illustrations. Crown 8vo, 3s. 6d.

**QUAIN. A DICTIONARY OF MEDICINE;** Including General Pathology, General Therapeutics, Hygiene, and the Diseases of Women and Children. By Various Writers. Edited by RICHARD QUAIN, Bart., M.D.Lond., LL.D.Edin. (Hon.), F.R.S., Physician Extraordinary to H.M. the Queen, President of the General Medical Council, Member of the Senate of the University of London, &c. Assisted by FREDERICK THOMAS ROBERTS, M.D.Lond., B.Sc., Fellow of the Royal College of Physicians, Fellow of University College, Professor of Materia Medica and Therapeutics, University College, &c.; and J. MITCHELL BRUCE, M.A.Abdn., M.D.Lond., Fellow of the Royal College of Physicians of London, Physician and Lecturer on the Principles and Practice of Medicine, Charing Cross Hospital, &c. New Edition, Revised throughout and Enlarged. In 2 Vols. medium 8vo, cloth, red edges, price 40s. *net*.

**QUAIN. QUAIN'S (JONES) ELEMENTS OF ANATOMY.** New Edition. Edited by EDWARD ALBERT SCHÄFER, F.R.S., Professor of Physiology in the University of Edinburgh; and GEORGE DANCER THANE, Professor of Anatomy in University College, London. In 3 Vols.

\*.\* The several parts of this work form COMPLETE TEXT-BOOKS OF THEIR RESPECTIVE SUBJECTS. They can be obtained separately as follows:—

**VOL. I., PART I. EMBRYOLOGY.** By E. A. SCHÄFER, F.R.S. With 200 Illustrations. Royal 8vo, 9s.

**VOL. I., PART II. GENERAL ANATOMY OR HISTOLOGY.** By E. A. SCHÄFER, F.R.S. With 291 Illustrations. Royal 8vo, 12s. 6d.

**QUAIN (ANATOMY)**—*continued.*

- VOL. II., PART I. OSTEOLOGY — ARTHROLOGY** By G. D. THANE. With 224 Illustrations. Royal 8vo, 11s.
- VOL. II., PART II. MYOLOGY — ANGIOLOGY.** By G. D. THANE. With 199 Illustrations. Royal 8vo, 16s.
- VOL. III., PART I. THE SPINAL CORD AND BRAIN.** By E. A. SCHÄFER, F.R.S. With 139 Illustrations. Royal 8vo, 12s. 6d.
- VOL. III., PART II. THE NERVES.** By G. D. THANE. With 102 Illustrations. Royal 8vo, 9s.
- VOL. III., PART III. THE ORGANS OF THE SENSES.** By E. A. SCHÄFER, F.R.S. With 178 Illustrations. Royal 8vo, 9s.
- VOL. III., PART IV. SPLANCHNOLOGY.** By E. A. SCHÄFER, F.R.S., and JOHNSON SYMINGTON, M.D. With 337 Illustrations. Royal 8vo, 16s.
- APPENDIX. SUPERFICIAL AND SURGICAL ANATOMY.** By Professor G. D. THANE and Professor R. J. GODLEE, M.S. With 29 Illustrations. Royal 8vo, 6s. 6d.

**SCHÄFER. THE ESSENTIALS OF HISTOLOGY:** Descriptive and Practical. For the Use of Students. By E. A. SCHÄFER, LL.D., F.R.S., Professor of Physiology in the University of Edinburgh; Editor of the Histological Portion of Quain's "Anatomy." Illustrated by nearly 400 Figures. Fifth Edition, Revised and Enlarged. 8vo, 8s.; Interleaved, 10s. 6d.

**SCHENK. MANUAL OF BACTERIOLOGY.** For Practitioners and Students. With especial reference to Practical Methods. By Dr. S. L. SCHENK, Professor (Extraordinary) in the University of Vienna. Translated from the German, with an Appendix, by W. R. DAWSON, B.A., M.D., Univ. Dub.; late University Travelling Prizeman in Medicine. With 100 Illustrations, some of which are coloured. 8vo, 10s. net.

**SCHREINER. THE ANGORA GOAT** published under the auspices of the South African Angora Goat Breeders' Association); and A PAPER ON THE OSTRICH (reprinted from the *Zoologist* for March, 1897). By S. C. CRONWRIGHT SCHREINER. With 26 Illustrations from Photographs. 8vo, 10s. 6d.

**SMALE AND COLYER. DISEASES AND INJURIES OF THE TEETH,** including Pathology and Treatment: a Manual of Practical Dentistry for Students and Practitioners. By MORTON SMALE, M.R.C.S., L.S.A., L.D.S., Dental Surgeon to St. Mary's Hospital, Dean of the School, Dental Hospital of London, &c.; and J. F. COLYER, L.R.C.P., M.R.C.S., L.D.S., Assistant Dental Surgeon to Charing Cross Hospital, and Assistant Dental Surgeon to the Dental Hospital of London. With 334 Illustrations. Large Crown 8vo, 15s.

WORKS ON MEDICINE, SURGERY &c.

---

**SMITH (H. F.).** THE HANDBOOK FOR MIDWIVES. By HENRY FLY SMITH, B.A., M.B. Oxon., M.R.C.S. Second Edition. With 41 Woodcuts. Crown 8vo, price 5s.

---

**STEEL.**—WORKS by JOHN HENRY STEEL, F.R.C.V.S., F.Z.S. A.V.D., late Professor of Veterinary Science and Principal of Bombay Veterinary College.

A TREATISE ON THE DISEASES OF THE DOG; being a Manual of Canine Pathology. Especially adapted for the use of Veterinary Practitioners and Students. 88 Illustrations. 8vo, 10s. 6d.

A TREATISE ON THE DISEASES OF THE OX; being a Manual of Bovine Pathology. Especially adapted for the use of Veterinary Practitioners and Students. 2 Plates and 117 Woodcuts. 8vo, 15s.

A TREATISE ON THE DISEASES OF THE SHEEP; being a Manual of Ovine Pathology for the use of Veterinary Practitioners and Students. With Coloured Plate, and 99 Woodcuts. 8vo, 12s.

OUTLINES OF EQUINE ANATOMY; a Manual for the use of Veterinary Students in the Dissecting Room. Crown 8vo, 7s. 6d.

---

**STEVENSON.** WOUNDS IN WAR: the Mechanism of their Production and their Treatment. By Surgeon-Colonel W. F. STEVENSON (Army Medical Staff), A.B., M.B., M.Ch. Dublin University; Professor of Military Surgery, Army Medical School, Netley. With 86 Illustrations. 8vo, price 18s.

---

**“STONEHENGE.”** THE DOG IN HEALTH AND DISEASE. By “STONEHENGE.” With 84 Wood Engravings. Square crown 8vo, 7s. 6d.

---

**TAPPEINER.** INTRODUCTION TO CHEMICAL METHODS OF CLINICAL DIAGNOSIS. By Dr. H. TAPPEINER, Professor of Pharmacology and Principal of the Pharmacological Institute of the University of Munich. Translated from the Sixth German Edition, with an Appendix on Micro-Biological Methods of Diagnosis, by EDMOND J. McWEENEY, M.A., M.D. (Royal Univ. of Ireland), L.R.C.P.I. &c. With 22 Illustrations. Crown 8vo. 3s. 6d.

---

**THORNTON.** HUMAN PHYSIOLOGY. By JOHN THORNTON, M.A., Author of “Elementary Physiography,” “Advanced Physiography,” &c. With 267 Illustrations, some of which are Coloured. Crown 8vo, 6s.

---

**TIRARD.** DIPHTHERIA AND ANTITOXIN. By NESTOR TIRARD, M.D. Lond., Fellow of the Royal College of Physicians; Fellow of King's College, London; Professor of Materia Medica and Therapeutics at King's College; Physician to King's College Hospital; and Senior Physician to the Evelina Hospital for Sick Children. 8vo, 7s. 6d.

**WAKLEY.** THE LIFE AND TIMES OF THOMAS WAKLEY,  
 Founder and First Editor of the *Lancet*, Member of Parliament for Finsbury,  
 and Coroner for West Middlesex. By S. SQUIRE SPRIGGE, M.B.  
 Cantab. With 2 Portraits. 8vo, 6s.

**WALLER.**—*WORKS* by AUGUSTUS D. WALLER, M.D., Lecturer  
 on Physiology at St. Mary's Hospital Medical School, London; late External Examiner  
 at the Victorian University.

AN INTRODUCTION TO HUMAN PHYSIOLOGY. Third  
 Edition, Revised. With 314 Illustrations. 8vo, 18s.

EXERCISES IN PRACTICAL PHYSIOLOGY.

PART I.—*Elementary Physiological Chemistry.* By AUGUSTUS D.  
 WALLER and W. LEGGE SYMES. 8vo, sewed, 1s. net.

PART II.—*In the Press.*

PART III.—*Physiology of the Nervous System; Electro-Physiology.*  
 8vo, 2s. 6d. net.

LECTURES ON PHYSIOLOGY.

FIRST SERIES.—*On Animal Electricity.* 8vo, 5s. net.

**WEICHSELBAUM.** THE ELEMENTS OF PATHOLOGICAL  
 HISTOLOGY, with Special Reference to Practical Methods.  
 By Dr. ANTON WEICHSELBAUM, Professor of Pathology in the  
 University of Vienna. Translated by W. R. DAWSON, M.D. (Dub.),  
 Demonstrator of Pathology in the Royal College of Surgeons, Ireland, late  
 Medical Travelling Prizeman of Dublin University, &c. With 221 Figures,  
 partly in Colours, a Chromo-lithographic Plate, and 7 Photographic Plates.  
 Royal 8vo, 21s. net.

**WILKS AND MOXON.** LECTURES ON PATHOLOGICAL  
 ANATOMY. By Sir SAMUEL WILKS, Bart., M.D., F.R.S., President  
 of the Royal College of Physicians, and Physician Extraordinary to H. M. the  
 Queen, and the late WALTER MOXON, M.D., F.R.C.P., Physician to,  
 and some time Lecturer on Pathology at, Guy's Hospital. Third Edition,  
 thoroughly Revised. By Sir SAMUEL WILKS, Bart., M.D., LL.D.,  
 F.R.S. 8vo, 18s.

**YOUATT.**—*WORKS* by WILLIAM YOUATT

THE HORSE. Revised and Enlarged by W. WATSON, M.R.C.V.S.  
 With 52 Woodcuts. 8vo, 7s. 6d.

THE DOG. Revised and Enlarged. With 33 Woodcuts. 8vo, 6s.

## General Scientific Works.

**BEDDARD.** THE STRUCTURE AND CLASSIFICATION OF BIRDS. By FRANK E. BEDDARD, M.A., F.R.S., Prosector and Vice-Secretary of the Zoological Society of London. With 252 Illustrations. 8vo, 21s. net.

**BENNETT AND MURRAY** A HANDBOOK OF CRYPTOGAMIC BOTANY. By A. W. BENNETT, M.A., B.Sc., F.L.S., and GEORGE R. MILNE MURRAY, F.L.S. With 378 Illustrations. 8vo, 16s.

**CLERKE.** THE SYSTEM OF THE STARS. By AGNES M. CLERKE, Author of "A History of Astronomy during the Nineteenth Century." With 6 Plates and Numerous Illustrations. 8vo, 21s.

**CLODD.**—*WORKS* by EDWARD CLODD, Author of "*The Childhood of the World,*" &c.

THE STORY OF CREATION. A Plain Account of Evolution. With 77 Illustrations. Crown 8vo, 3s. 6d.

A PRIMER OF EVOLUTION: being a Popular Abridged Edition of "The Story of Creation." With Illustrations. Fcp. 8vo, 1s. 6d.

**CROOKES.** SELECT METHODS IN CHEMICAL ANALYSIS (chiefly Inorganic). By Sir W. CROOKES, F.R.S., V.P.C.S., Editor of "The Chemical News." Third Edition, re-written and enlarged. Illustrated with 67 Woodcuts. 8vo, 21s. net.

**CURTIS.** A TEXT-BOOK OF GENERAL BOTANY By CARLTON C. CURTIS, A.M. Ph.D. Tutor in Botany in Columbia University. With 87 Illustrations. Royal 8vo, 12s. net.

**DU BOIS.** THE MAGNETIC CIRCUIT IN THEORY AND PRACTICE. By Dr. H. DU BOIS, Privat-docent in the University of Berlin. Translated from the German by Dr. E. ATKINSON. With 94 Illustrations. 8vo, 12s. net.

**EBERT** MAGNETIC FIELDS OF FORCE: An Exposition of the Phenomena of Magnetism, Electromagnetism, and Induction, based on the Conception of Lines of Force. By H. EBERT, Professor of Physics in the University of Kiel. Translated by C. V. BURTON, D.Sc. Part I. With 93 Illustrations. 8vo, 10s. 6d. net.

**GANOT** ELEMENTARY TREATISE ON PHYSICS ;

Experimental and Applied, for the use of Colleges and Schools. Translated and edited from GANOT'S *Éléments de Physique* (with the Author's sanction) by E. ATKINSON, Ph.D., F.C.S., formerly Professor of Experimental Science, Staff College, Sandhurst. Fifteenth Edition, revised and enlarged, with 9 Coloured Plates and 1,057 Woodcuts. Large crown 8vo, 15s.

## NATURAL PHILOSOPHY FOR GENERAL READERS AND YOUNG PERSONS ;

Translated and Edited from GANOT'S *Cours Élémentaire de Physique* (with the Author's sanction) by E. ATKINSON, Ph.D., F.C.S. Eighth Edition, carefully revised ; with 7 Plates, 624 Woodcuts, and an Appendix of Questions. Crown 8vo, 7s. 6d.

**GOODEVE.**—*WORKS* by T. M. GOODEVE, M.A., *Barrister-at-Law* ; formerly Professor of Mechanics at the Normal School of Science and the Royal School of Mines.

**PRINCIPLES OF MECHANICS.** New Edition, re-written and enlarged. With 253 Woodcuts and numerous Examples. Crown 8vo, 6s.

**THE ELEMENTS OF MECHANISM.** New Edition, re-written and enlarged. With 357 Woodcuts. Crown 8vo, 6s.

**A MANUAL OF MECHANICS :** an Elementary Text-Book for Students of Applied Mechanics. With 138 Illustrations and Diagrams, and 141 Examples taken from the Science Department Examination Papers, with Answers. Fcp. 8vo, 2s. 6d.

**HELMHOLTZ.**—*WORKS* by HERMANN L. F. HELMHOLTZ, M.D., late Professor of Physics in the University of Berlin.

**ON THE SENSATIONS OF TONE AS A PHYSIOLOGICAL BASIS FOR THE THEORY OF MUSIC.** Second English Edition ; with numerous additional Notes, and a new Additional Appendix, bringing down information to 1885, and specially adapted to the use of Musical Students. By ALEXANDER J. ELLIS, B.A., F.R.S., F.S.A., &c., formerly Scholar of Trinity College, Cambridge. With 68 Figures engraved on Wood, and 42 Passages in Musical Notes. Royal 8vo, 28s.

**POPULAR LECTURES ON SCIENTIFIC SUBJECTS.** With 68 Woodcuts. 2 Vols. crown 8vo, 3s. 6d. each.

**HERSCHEL.** OUTLINES OF ASTRONOMY. By Sir JOHN F. W. HERSCHEL, Bart., K.H., &c., Member of the Institute of France. Twelfth Edition, with 9 Plates, and numerous Diagrams. 8vo, 12s.

**HOFF.** THE ARRANGEMENT OF ATOMS IN SPACE. By J. H. VAN 'T HOFF. Second, Revised, and Enlarged Edition. With a Preface by JOHANNES WISLICENUS, Professor of Chemistry at the University of Leipzig ; and an Appendix, "Stereochemistry among Inorganic Substances," by ALFRED WERNER, Professor of Chemistry at the University of Zürich. Translated and Edited by ARNOLD EILOART. Crown 8vo, 6s. 6d.

**HUDSON AND GOSSE.** THE ROTIFERA OR 'WHEEL ANIMALCULES.' By C. T. HUDSON, LL.D., and P. H. GOSSE, F.R.S. With 30 Coloured and 4 Uncoloured Plates. In 6 Parts. 4to, price 10s. 6d. each; Supplement, 12s. 6d. Complete in Two Volumes, with Supplement, 4to, £4 4s.

\* \* The Plates in the Supplement contain figures of almost all the Foreign Species, as well as of the British Species, that have been discovered since the original publication of Vols. I. and II.

**JOUBERT.** ELEMENTARY TREATISE ON ELECTRICITY AND MAGNETISM. Founded on JOUBERT'S "*Traité Élémentaire d'Électricité.*" By G. C. FOSTER, F.R.S., Quain Professor of Physics in University College, London; and E. ATKINSON, Ph.D., formerly Professor of Experimental Science in the Staff College. With 381 Illustrations. Crown 8vo, 7s. 6d.

**KOLBE.** A SHORT TEXT-BOOK OF INORGANIC CHEMISTRY. By Dr. HERMANN KOLBE, late Professor of Chemistry in the University of Leipzig. Translated and Edited by T. S. HUMPIDGE, Ph.D., B.Sc. (Lond.), late Professor of Chemistry and Physics in the University College of Wales, Aberystwyth. New Edition. Revised by H. LLOYD-SNAPE, Ph.D., D.Sc. (Lond.), Professor of Chemistry in the University College of Wales, Aberystwyth. With a Coloured Table of Spectra and 66 Woodcuts. Crown 8vo, 8s. 6d.

**LARDEN.** ELECTRICITY FOR PUBLIC SCHOOLS AND COLLEGES. With numerous Questions and Examples with Answers, and 214 Illustrations and Diagrams. By W. LARDEN, M.A. Crown 8vo, 6s.

**LEWIS.** PAPERS AND NOTES ON THE GENESIS AND MATRIX OF THE DIAMOND. By the late HENRY CARVILL LEWIS, M.A., F.G.S., Professor of Mineralogy in the Academy of Natural Sciences, Philadelphia, Professor of Geology in Haverford College, U.S.A. Edited from his unpublished MSS. by Professor T. G. BONNEY, D.Sc., LL.D., F.R.S., &c. With 2 Plates and 35 Illustrations in the Text. 8vo, 7s. 6d.

**LINDLEY AND MOORE.** THE TREASURY OF BOTANY, OR POPULAR DICTIONARY OF THE VEGETABLE KINGDOM: with which is incorporated a Glossary of Botanical Terms. Edited by J. LINDLEY, M.D., F.R.S., and T. MOORE, F.L.S. With 20 Steel Plates, and numerous Woodcuts. 2 Parts, fcp. 8vo, price 12s.

**LOWELL.** MARS. By PERCIVAL LOWELL, Fellow American Academy, Member Royal Asiatic Society, Great Britain and Ireland, &c. With 24 Plates. 8vo, 12s. 6d.

\* \* The book is written in a style suitable for the general reader, and the most recent speculations as to the planet being inhabited, the possible canals, oases, &c., are discussed.



**MARTIN. NAVIGATION AND NAUTICAL ASTRONOMY.**

Compiled by Staff-Commander W. R. MARTIN, R.N., Instructor in Surveying, Navigation, and Compass Adjustment; Lecturer on Meteorology at the Royal Naval College, Greenwich. Sanctioned for use in the Royal Navy by the Lords Commissioners of the Admiralty. Royal 8vo, 18s.

**MENDELÉEFF. THE PRINCIPLES OF CHEMISTRY.** By

D. MENDELÉEFF. Translated from the Russian (Sixth Edition) by GEORGE KANENSKY, A.R.S.M. of the Imperial Mint, St. Petersburg, and Edited by T. A. LAWSON, B.Sc., Ph.D., Fellow of the Institute of Chemistry. With 96 Diagrams and Illustrations. 2 Vols. 8vo, 36s.

**MEYER. OUTLINES OF THEORETICAL CHEMISTRY**

By LOTHAR MEYER, Professor of Chemistry in the University of Tübingen. Translated by Professors P. PHILLIPS BEDSON, D.Sc., and W. CARLETON WILLIAMS, B.Sc. 8vo, 9s.

**MEYER. THE KINETIC THEORY OF GASES.** Elementary

Treatise, with Mathematical Appendices. By Dr. OSKAR EMIL MEYER, Professor of Physics at the University of Breslau. Second Revised Edition. Translated by ROBERT E. BAYNES, M.A., Student of Christ Church, Oxford, and Dr. Lee's Reader in Physics. 8vo, 15s. net.

**MORGAN. ANIMAL BIOLOGY** An Elementary Text-Book. By

C. LLOYD MORGAN, Principal of University College, Bristol. With numerous Illustrations. Crown 8vo, 8s. 6d.

**OSTWALD. SOLUTIONS.** By W. OSTWALD, Professor of Chemistry

in the University of Leipzig. Being the Fourth Book, with some additions, of the Second Edition of Ostwald's "Lehrbuch der Allgemeinen Chemie." Translated by M. M. PATTISON MUIR, Professor of Gonville and Caius College, Cambridge. 8vo, 10s. 6d.

**PROCTOR.—WORKS by RICHARD A. PROCTOR.**

LIGHT SCIENCE FOR  
LEISURE HOURS; Familiar  
Essays on Scientific Subjects,  
Natural Phenomena, &c. 3 Vols.  
Crown 8vo, 5s. each. Vol. I.,  
Cheap Edition. Crown, 3s. 6d.

Planets, Meteors, and Comets.  
With Chart and Diagrams. Crown  
8vo, 3s. 6d.

OTHER WORLDS THAN  
OURS; The Plurality of Worlds  
Studied under the Light of Recent  
Scientific Researches. With 14  
Illustrations. Crown 8vo, 3s. 6d.

THE ORBS AROUND US; a  
Series of Essays on the Moon and

[Continued.]

**PROCTOR.**—*WORKS* by *RICHARD A. PROCTOR*—*continued.*

- THE MOON**; her Motions, Aspects, Scenery, and Physical Condition. With Plates, Charts, Woodcuts, and Lunar Photographs. Crown 8vo, 3s. 6d.
- LARGER STAR ATLAS** for the Library, in 12 Circular Maps, with Introduction and 2 Index Pages. Folio, 15s., or Maps only, 12s. 6d.
- NEW STAR ATLAS** for the Library, the School, and the Observatory, in 12 Circular Maps (with 2 Index Plates). Crown 8vo, 5s.
- OTHER SUNS THAN OURS**: a Series of Essays on Suns—Old, Young, and Dead. With other Science Gleanings, Two Essays on Whist, and Correspondence with Sir John Herschel. With 9 Star-Maps and Diagrams. Crown 8vo, 3s. 6d.
- HALF-HOURS WITH THE TELESCOPE**: a Popular Guide to the Use of the Telescope as a Means of Amusement and Instruction. With 7 Plates. Fcap. 8vo, 2s. 6d.
- THE SOUTHERN SKIES**: a Plain and Easy Guide to the Constellations of the Southern Hemisphere. Showing in 12 Maps the position of the principal Star-Groups night after night throughout the year. With an Introduction and a separate Explanation of each Map. True for every Year. 4to, 5s.
- MYTHS AND MARVELS OF ASTRONOMY**. Crown 8vo, 3s. 6d.
- HALF-HOURS WITH THE STARS**: a Plain and Easy Guide to the Knowledge of the Constellations. Showing in 12 Maps the position of the principal Star-Groups night after night throughout the Year. With Introduction and a separate Explanation of each Map. True for every Year. 4to, 3s. 6d.
- THE STARS IN THEIR SEASONS**. An Easy Guide to a Knowledge of the Star Groups, in 12 Large Maps. Imperial 8vo, 5s.
- OUR PLACE AMONG INFINITIES**: a Series of Essays contrasting our Little Abode in Space and Time with the Infinities around Us. Crown 8vo, 3s. 6d.
- ROUGH WAYS MADE SMOOTH**. Familiar Essays on Scientific Subjects. Crown 8vo, 3s. 6d.
- THE EXPANSE OF HEAVEN**. Essays on the Wonders of the Firmament. Crown 8vo, 3s. 6d.
- PLEASANT WAYS IN SCIENCE**. Crown 8vo, 3s. 6d.
- NATURE STUDIES**. By GRANT ALLEN, A. WILSON, T. FOSTER, E. CLODD, and R. A. PROCTOR. Crown 8vo, 3s. 6d.
- LEISURE READINGS**. By E. CLODD, A. WILSON, T. FOSTER, A. C. RUNYARD, and R. A. PROCTOR. Crown 8vo, 3s. 6d.
- STRENGTH**: How to get Strong and keep Strong, with Chapters on Rowing and Swimming, Fat, Age, and the Waist. With 9 Illustrations. Crown 8vo, 2s.

**REYNOLDS. EXPERIMENTAL CHEMISTRY** for Junior Students.

By J. EMERSON REYNOLDS, M.D., F.R.S., Professor of Chemistry, Univ. of Dublin. Fcp. 8vo, with numerous Woodcuts.

PART I.—*Introductory*, 1s. 6d. PART III.—*Metals and Allied Bodies*, 3s. 6d.  
PART II.—*Non-Metals*, 2s. 6d. PART IV.—*Chemistry of Carbon Compounds*, 4s.

**ROMANES.—WORKS** by *GEORGE JOHN ROMANES, M.A., LL.D., F.R.S.*

**DARWIN, AND AFTER DARWIN:** an Exposition on the Darwinian Theory, and a Discussion on Post-Darwinian Questions. Part I. **THE DARWINIAN THEORY.** With Portrait of Darwin and 125 Illustrations. Crown 8vo, 10s. 6d. Part II. **POST-DARWINIAN QUESTIONS: Heredity and Utility.** With Portrait of the Author and 5 Illustrations. Crown 8vo, 10s. 6d. Part III. **POST-DARWINIAN QUESTIONS: ISOLATION AND PHYSIOLOGICAL SELECTION.** Crown 8vo, 5s.

**AN EXAMINATION OF WEISMANNISM.** Cr. 8vo, 6s.

**ESSAYS.** Edited by C. LLOYD MORGAN, Principal of University College, Bristol. Crown 8vo, 6s.

CONTENTS: Primitive Natural History—The Darwinian Theory of Instinct—Man and Brute—Mind in Men and Animals—Origin of Human Faculty—Mental Differences between Men and Women—What is the Object of Life?—Recreation—Hypnotism—Hydrophobia and the Muzzling Order.

**SLINGO AND BROOKER. ELECTRICAL ENGINEERING FOR ELECTRIC-LIGHT ARTISANS AND STUDENTS.**

(Embracing those branches prescribed in the Syllabus issued by the City and Guilds Technical Institute.) By W. SLINGO and A. BROOKER. With 346 Illustrations. Crown 8vo, 12s.

**SORAUER. A POPULAR TREATISE ON THE PHYSIOLOGY OF PLANTS.**

For the Use of Gardeners, or for Students of Horticulture and of Agriculture. By Dr. PAUL SORAUER, Director of the Experimental Station at the Royal Pomological Institute in Proskau (Silesia). Translated by F. E. WEISS, B.Sc., F.L.S., Professor of Botany at the Owens College, Manchester. With 33 Illustrations. 8vo, 9s. net.

**THORPE. A DICTIONARY OF APPLIED CHEMISTRY**

By T. E. THORPE, B.Sc. (Vict.), Ph.D., F.R.S., Treas. C.S., Professor of Chemistry in the Royal College of Science, London. Assisted by Eminent Contributors. To be published in 3 vols. 8vo. Vols. I. and II. £2 2s. each, Vol. III. £3 3s.

**TILDEN. A SHORT HISTORY OF THE PROGRESS OF SCIENTIFIC CHEMISTRY IN OUR OWN TIMES.**

By WILLIAM A. TILDEN, D.Sc.Lond., D.Sc.Dub., F.R.S., Fellow of the University of London, Professor of Chemistry in the Royal College of Science, London. Crown 8vo, 5s. net.

**TUBEUF.** DISEASES OF PLANTS DUE TO CRYPTO-GAMIC PARASITES. Translated from the German of DR. CARL FREIHERR VON TUBEUF, of the University of Munich, by WILLIAM G. SMITH, B.Sc., Ph.D., Lecturer on Plant Physiology to the University of Edinburgh. With 330 Illustrations. Royal 8vo, 18s. net.

**TYNDALL.**—WORKS by JOHN TYNDALL, F.R.S., &c.

FRAGMENTS OF SCIENCE. 2 Vols. Crown 8vo, 16s.

NEW FRAGMENTS. Crown 8vo, 10s. 6d.

HEAT A MODE OF MOTION. Crown 8vo, 12s.

SOUND. With 204 Woodcuts. Crown 8vo, 10s. 6d.

RESEARCHES ON DIAMAGNETISM AND MAGNE-CRYSTALLIC ACTION, including the question of Diamagnetic Polarity. Crown 8vo, 12s.

ESSAYS ON THE FLOATING-MATTER OF THE AIR in relation to Putrefaction and Infection. With 24 Woodcuts. Crown 8vo, 7s. 6d.

LECTURES ON LIGHT, delivered in America in 1872 and 1873. With 57 Diagrams. Crown 8vo, 5s.

LESSONS IN ELECTRICITY AT THE ROYAL INSTITUTION, 1875-76. With 58 Woodcuts. Crown 8vo, 2s. 6d.

NOTES OF A COURSE OF SEVEN LECTURES ON ELECTRICAL PHENOMENA AND THEORIES, delivered at the Royal Institution. Crown 8vo, 1s. 6d.

NOTES OF A COURSE OF NINE LECTURES ON LIGHT, delivered at the Royal Institution. Crown 8vo, 1s. 6d.

FARADAY AS A DISCOVERER. Crown 8vo, 3s. 6d.

THE GLACIERS OF THE ALPS: being a Narrative of Excursions and Ascents. An Account of the Origin and Phenomena of Glaciers, and an Exposition of the Physical Principles to which they are related. With 61 Illustrations. Crown 8vo, 6s. 6d. net.

**WEBB.** CELESTIAL OBJECTS FOR COMMON TELESCOPES.

By the Rev. T. W. WEBB, M.A., F.R.A.S., Vicar of Hardwick, Herefordshire. Fifth Edition, Revised and greatly Enlarged by the Rev. T. E. ESPIN, M.A., F.R.A.S. (Two Volumes.)

VOL. I. With Portrait and a Reminiscence of the Author, 2 Plates, and numerous Illustrations. Crown 8vo, 6s.


VOL. II. With Illustrations and Map of Star Spectra. Crown 8vo, 6s. 6d.

**WRIGHT** OPTICAL PROJECTION: A Treatise on the Use of the Lantern in Exhibition and Scientific Demonstration. By LEWIS WRIGHT, Author of "Light: a Course of Experimental Optics." With 232 Illustrations. Crown 8vo, 6s.











## ORIENTAÇÕES PARA O USO

Esta é uma cópia digital de um documento (ou parte dele) que pertence a um dos acervos que fazem parte da Biblioteca Digital de Obras Raras e Especiais da USP. Trata-se de uma referência a um documento original. Neste sentido, procuramos manter a integridade e a autenticidade da fonte, não realizando alterações no ambiente digital – com exceção de ajustes de cor, contraste e definição.

**1. Você apenas deve utilizar esta obra para fins não comerciais.** Os livros, textos e imagens que publicamos na Biblioteca Digital de Obras Raras e Especiais da USP são de domínio público, no entanto, é proibido o uso comercial das nossas imagens.

**2. Atribuição.** Quando utilizar este documento em outro contexto, você deve dar crédito ao autor (ou autores), à Biblioteca Digital de Obras Raras e Especiais da USP e ao acervo original, da forma como aparece na ficha catalográfica (metadados) do repositório digital. Pedimos que você não republique este conteúdo na rede mundial de computadores (internet) sem a nossa expressa autorização.

**3. Direitos do autor.** No Brasil, os direitos do autor são regulados pela Lei n.º 9.610, de 19 de Fevereiro de 1998. Os direitos do autor estão também respaldados na Convenção de Berna, de 1971. Sabemos das dificuldades existentes para a verificação se uma obra realmente encontra-se em domínio público. Neste sentido, se você acreditar que algum documento publicado na Biblioteca Digital de Obras Raras e Especiais da USP esteja violando direitos autorais de tradução, versão, exibição, reprodução ou quaisquer outros, solicitamos que nos informe imediatamente ([dtsibi@usp.br](mailto:dtsibi@usp.br)).